

UNDER REPORTED VACUUM PHENOMENON: ACCUMULATING THE BURDEN OF DISEASE

Khalid Mahmood Khan, Nazila Bano Khalid, Saima Noor, Ahsan Ali, Zuhaib Zafar, Manzoor Mushtaq, Shabbir Naeem

Department of Radiology Sindh Institute of Urology & Transplantation, SIUT, Karachi, Pakistan.

PJR October - December 2018; 28(4): 267-271

ABSTRACT

BACKGROUND AND PURPOSE: In Low-middle income countries like Pakistan, musculoskeletal diseases and renal calculi are prevalent and impart tremendous socioeconomic burden on health care system but receives little attention both for prevention and treatment. Since Computed Tomography Kidney, Ureter & Bladder (CT KUB) are frequently performed for diagnosis and include sacroiliac joints in field of view. The vacuum phenomenon less found in literature is a common finding in sacroiliac joints reflects an indicator of bone degenerative diseases in CT KUB. We hypothesized the prevalence of vacuum phenomenon in spine and sacroiliac joints (SJVP) assuming that it more common and radiologists would not mention frequently on spine images performed for urogenital ailments. **METHODS AND MATERIALS:** A prospective exploratory study of four months (July to October 2017) sample of seven hundred and thirty referrals to radiology department for CT KUB scans. The age, sex and radiologists reports were reviewed from medical records. **RESULTS:** Along with Urogenital and renal calculi, CT KUB of almost two third patients 42.2% (n=49) revealed vacuum phenomena in spines of middle aged males and 31% (n=57) sacroiliac joints of adult females. Among 730 patients with vacuum phenomenon only 41% (n=300) were reported. **CONCLUSION:** The bone degenerative diseases are prevalent among adult males and females. But the phenomenon is underreported on CT images. The identification may channelize individuals to early diagnostic and cost effective therapeutic interventions to avert the health care cost and implement timely cost effective measures for bone degeneration in masses of low middle income countries.

Keywords: Vacuum phenomenon, Sacroiliac joint, CT Kidney Ureter & Bladder, bone degeneration

Introduction

Vacuum phenomenon (VP) is commonly found in sacroiliac joints in CT KUB performed for urogenital and renal calculi constituting 50-60% of Urologic workload.¹ It is a significant finding in patients with backache which is prevalent along with renal ailments in middle to old aged patients. We investigated the prevalence of spine and sacroiliac joint vacuum phenomenon (SJVP) and the rate at which it is reported in CT KUB scans by radiologists of a tertiary care hospital.

The vacuum phenomenon appears as a radiolucent

area visible in synovial joints, intervertebral disks and vertebrae.² The nitrogen produced by the surrounding tissues manifests as gas accumulation.² This gas accumulation exhibits diversely as in synovial joints appears as distraction of the articular surfaces,³ whereas in intervertebral disks, the vacuum phenomenon is, in most cases, related to degenerative processes and this phenomenon has also been reported in rare cases of tumors and infections too.^{4&5} Moreover, in the vertebrae, the phenomenon has been described in cases of collapse, usually resulting from osteone-

Correspondence : Dr. Khalid Mahmood Khan
Department of Radiology
Sindh Institute of Urology & Transplantation,
SIUT, Karachi, Pakistan.
Email: nazilakhalid@gmail.com

Submitted 16 June 2018, Accepted 28 July 2018

crisis.⁶ The vacuum phenomenon detected incidentally on CT was performed for diagnosis of renal tract calculi, their sequelae or other causes of obstruction. The literature has dearth of studies related to vacuum phenomenon and only few studies show the data related to incidence, significance and diagnostic identification as indicator of degenerative bone disorders. Owing to hot weather and poor drinking water in developing countries of East Asia like Pakistan; the prevalence of renal calculi is high and constitutes 50-60% of Urologic workload.¹ These patients may also have backache due to degenerative bone diseases which needs to be differentiated from renal disorders. Hence, the detection rate of renal calculi on CT KUB is 90-100%, thus considered a cost effective diagnostic measure.¹ As lumbosacral vertebrae and sacroiliac joints are included in the field of view but the common finding of gas in these areas is not mentioned in radiologist's reports.

The vacuum phenomenon was hypothesized to be more common and radiologists would not identify or mention more frequently on CT KUB performed as diagnostic and therapeutic measures for renal calculi or other urogenital ailments. The aim of this study was to describe the vacuum phenomenon in CT KUB scans as a CT sign of bone degenerative diseases and rate of reporting by radiologists which may not only improve the practice quality but also prove to be cost effective indicator of bone degenerative diseases in low middle countries.

Materials and Methods

Research design and sample:

The ethics review committee of the institute approved retrospective, exploratory study. The 730 patients referred by the Urologists from July to October 2017, underwent CT KUB scans with multiplanar reconstructions to evaluate the renal tract calculi or obstruction. The demographic data was retrieved from medical records. The CT images reported by the investigator and without vacuum phenomenon were excluded from the study.

Investigations:

The CT KUB images were obtained in 5.00 mm-thick axial slices. The images were reviewed at bone

window. The images were reconstructed on Vitrea software 1mm-interval, for coronal and sagittal images.

From July 2017 to October 2017, 730 patients underwent CT KUB. In patients 41% (n=300) a gas collection was seen in spines and sacroiliac joints which raised suspicion of degenerative diseases. The presence of a gas collection within the lumbar vertebrae and sacroiliac joints as well as within the surrounding soft tissues was coded.

At the study site the descriptive distribution of the study population with respect to the referral provided by the consultant and the selection and distribution of patients who underwent CT KUB is explained in (Tab. 1) as following:

	Reported (n=300)	Under reported (n=430)
Mean Age	45 Years	48 Years
Gender		
Male	152	269
Female	148	161
CT KUB reported by Radiologist	300	430

Table 1: The descriptive distribution of Computed Tomography Kidney Ureter and Bladder (CT KUB)

Results

Statistical analysis:

The clinicians referred 730 patients during the period of four months from July to October'2017. Out of these 730; 41% (n= 300) had vacuum phenomenon (VP) in either sacroiliac or spine region. The (Tab. 2) explains the descriptive analysis of study participants:

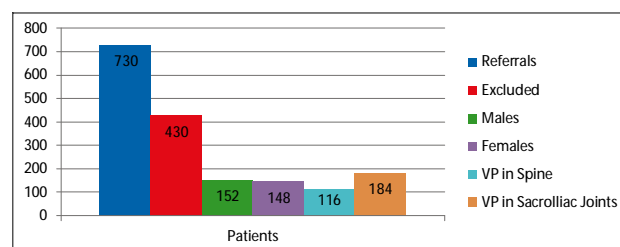


Table 2: Distribution of patients' Computed Tomography of Kidney Ureter & Bladder (CT KUB)

The study population consisted of 300 patients and gender distribution of study population was 50.6% (n=152) males and females 49.3% (n=148) with a mean age of 45 years (age range 31-60 years). The

significantly highest frequency for vacuum phenomena was in Sacroiliac joints 61.3% (n=184) whereas in spine was 38.6% (n=116). In terms of gender the occurrence of vacuum phenomenon was higher in sacroiliac joints of females 69.5% (n= 128) whereas vacuum phenomenon of spine was prominent in males 69.8% (n= 81).

The occurrence of vacuum phenomenon was much higher in sacroiliac joints of young females 31% (n=57) within the ages of 31 to 40 years followed by 21.9% (n = 39) among females of 41 to 50 years. The onset and occurrence of vacuum phenomenon with respect to age stratification for lumbar spine and sacroiliac joints is explained in (Tab. 3) as following:

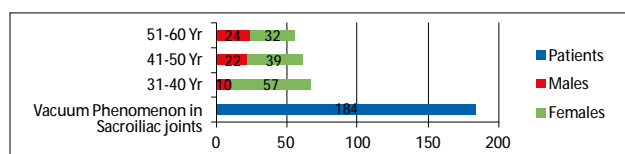


Table 3: Distribution of Vacuum phenomenon in Sacroiliac Joints

The (Tab. 4) describes occurrence of vacuum phenomenon in spine predominantly in middle aged adult men 42.2% (n= 49) with age range of 51 to 60 years. Whereas only 20% (n=23) spines of males of 41 to 50 years exhibited vacuum phenomenon.

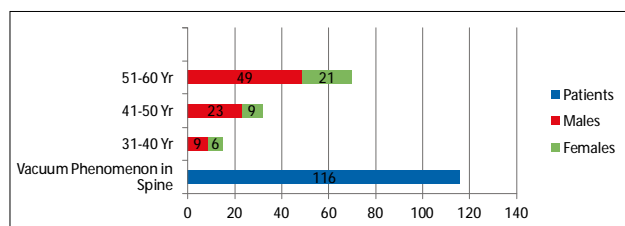


Table 4: Distribution of Vacuum phenomenon in Lumbar spine

Discussion

Our study findings in CT KUB of 300 patients revealed vacuum phenomenon as an indicating sign of degenerative bone diseases along with renal calculi or other obstructive ailments. These may co-occur or need to be differentiated. In developing countries the degenerative bone diseases manifests as low back ache and imposes tremendous burden on healthcare services and occupational health.⁷ The pronounced factor related to backache is mechanical musculoskeletal injuries of aging spine.^{8,9&10}

The negative pressure between the bone fragments persuaded the release of gas from the surrounding tissues.² The mostly observed gas collection pattern was in linear shape which is a proof of the vacuum phenomenon (Tab. 1). Whereas some of the patients had round gas bubble appearance between one and four which indicates an infection^{11&12} (Tab. 2). Nevertheless, the absence of this indicator does not manifest the healthy vertebrae. The (Fig. 1) shows the vacuum phenomenon linear pattern in sacroiliac joint of a 50 years old female patient.

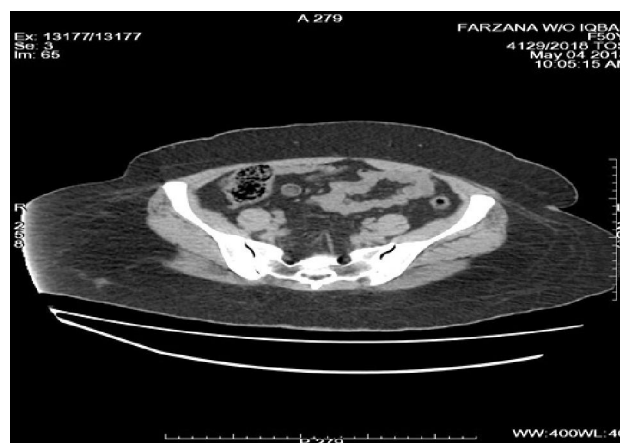

Figure 1: CT KUB Axial view at the level of SI Joint shows bilateral vacuum phenomenon in 50 years old female

The vacuum phenomenon may affect more than one intervertebral disc and causes disc degeneration leading to instability, functional incapacity and disability in the working years equally in both sexes. There is high prevalence of patients who remain asymptomatic despite degenerative changes. The imaging provides the platform for precise morphological information and therapeutic implications. The effects of sex and age groups showed that 69% females were prone to degenerative sacroiliac joints diseases whereas almost same numbers of males 69 % exhibited vacuum phenomenon in spine region. The middle aged males (> 51 years) were more likely to exhibit VP than younger males. While young adult females (>31 years) had degenerative bone diseases than middle aged adult females. These findings correlate with demographic and morphologic characteristics of both genders. The anatomical and morphological explanation for higher prevalence of SJVP in females is influence of estrogen and relaxin on pelvic ligaments resulting

in wider and mobile Sacroiliac joints. This phenomenon leads to higher prevalence of SJVP in multiparous females.^{2,13} And the common age of multiparous women in developing countries is between 26-30 years and comprises of 19.3 - 33.64% of obstetric case load.¹³ This coincides with study findings which exhibited vacuum phenomenon among 69.5 % (n=128) of females of adult age 31% (n=57). Moreover, in low middle income countries like Pakistan the Low back pain (LBP) is the single most common cause for disability in males aged 45 years or younger and imposes tremendous burden on socioeconomic conditions.¹⁴ It entails estimated gross economic loss of more than \$100 billion per year owing to reduced productivity.¹⁵

The process of degeneration is accelerated in males of productive age and the rate of biomedical changes in disc is pivotal in physical and functional impairment of the individuals.¹⁵ The environment or occupations like unskilled laborers demand frequent bending and twisting body movements and poses high risk of degenerative bone diseases (DDD) and manifests as vacuum phenomenon in males vertebrae.¹⁶ Moreover, smoking is another chemical factor leading to degenerative bone diseases and vacuum phenomenon in men.^{17&18}

The degenerative bone process is related to age but accelerates in patients of working age. Thus the DALY: Disability adjusted life year's measures the non-fatal loss of health but loss of productivity at younger ages. The 18% of the total burden of unintentional injury is related to East Asian working men aged 15-59 years.^{4&17} The study revealed that among 69.8% (n=81) males who had vacuum phenomenon as an indicator of bone degeneration sign, 42.2% (n=49) were adult males of working age group.

Furthermore, the occupational risks (ergonomic stressors) like physical exertion, lifting and carrying heavy loads, awkward postures and bending causes low back aches in 37% of males. This leads to absenteeism and poses economic losses.¹⁸

Hence, vacuum phenomenon (VP) is commonly found in sacroiliac joints in CT KUB performed for urogenital and renal calculi constituting 50-60% of Urologic workload.¹ It is a significant finding in patients with backache which is prevalent along with renal ailments in middle to old aged patients of both genders.

The findings emphasize that reporting of incidental finding of vacuum phenomenon will not only help in early diagnosis of degenerative bone diseases but shall prove cost effective in early therapeutic interventions in resource constrained developing countries.^{19,20}

Conclusion

The CT KUB scans provide valuable information about the prevalent spine and sacroiliac joints condition. Unfortunately, this phenomenon is under reported by radiologists. It calls upon the collaborative approach to improve patient care and clinical practices aimed to reduce the global burden of musculoskeletal diseases arising from disability and promote cost effective interventions to avert the societal cost of long-term care of bone degenerative disorders.

There are a few limitations in the study. Our study is cross-sectional and was conducted in a specific group of patients with urogenital ailments at a single center. We did not assess for backache in other population.

Acknowledgments: No funds were received in support of this work.

Conflict of interest: No benefits in any form have been or will be received from a commercial party related directly or indirectly to the subject of this manuscript

References

1. Naqvi S, Rizvi S, Sultan S, Zafar M, Ahmed B, Faiq S et al. Evaluation of children with urolithiasis. *Indian Journal of Urology*. 2007; **23(4)**: 420.
2. Lo S, Atceken Z, Carone M, Yousem D. Sacroiliac joint vacuum phenomenon - underreported finding. *Clinical Imaging*. 2011; **35(6)**: 465-9.
3. Boos N, Weissbach S, Rohrbach H, Weiler C, Spratt K, Nerlich A. Classification of Age-Related Changes in Lumbar Intervertebral Discs. *Spine*. 2002; **27(23)**: 2631-44.

4. Battié MC, Videman T. Lumbar Disc Degeneration. *The Journal of Bone and Joint Surgery-American Volume*. 2006; **88**: 3-9.
5. Ayberk G. Spinal gas accumulation causing lumbar discogenic disease: a case report. *Acta Orthopaedica Et Traumatologica Turcica*. 2015.
6. Lin T, Liao J, Tsai T, Lu M, Niu C, Chen W et al. The effects of anterior vacuum disc on surgical outcomes of degenerative versus spondylolytic spondylolisthesis: at a minimum two-year follow-up. *BMC Musculoskeletal Disorders*. 2014; **15(1)**:
7. Salomon J, Wang H, Freeman M, Vos T, Flaxman A, Lopez A et al. Healthy life expectancy for 187 countries, 1990 - 2010: a systematic analysis for the Global Burden Disease Study 2010. *The Lancet*. 2012; **380(9859)**: 2144-62.
8. North R, Shipley J, Wang H, Mekhail N. A Review of Economic Factors Related to the Delivery of Health Care for Chronic Low Back Pain. *Neuro-modulation: Technology at the Neural Interface*. 2014; **17**: 69-76.
9. Warnakulasuriya S, Peiris-John R, Coggon D, Ntani G, Sathiakumar N, Wickremasinghe A. Musculoskeletal pain in four occupational populations in Sri Lanka. *Occupational Medicine*. 2012; **62(4)**: 269-72.
10. Kuligowski T, Cieslik B, Nowicka Z. Functional outcomes in relation with the progression level in young degenerative disc disease patients. *Physiotherapy*. 2017; **24(2)**.
11. Gohil I, Vilensky J, Weber E. Vacuum phenomenon: Clinical relevance. *Clinical Anatomy*. 2013; **27(3)**: 455-62.
12. Feng S, Chang M, Wu H, Yu J, Wang S, Liu C. Are intravertebral vacuum phenomena benign lesions?. *European Spine Journal*. 2011; **20(8)**: 1341-8.
13. Njoku C, Abeshi S, Emechebe C. Grand Multiparity: Obstetric Outcome in Comparison with Multiparous Women in a Developing Country. *Open Journal of Obstetrics and Gynecology*. 2017; **7(7)**: 707-18.
14. Katz J. Lumbar Disc Disorders and Low-Back Pain: Socioeconomic Factors and Consequences. *The Journal of Bone and Joint Surgery (American)*. 2006; **88(2)**: 21.
15. Williams F, Sambrook P. Neck and back pain and intervertebral disc degeneration: Role of occupational factors. *Best Practice & Research Clinical Rheumatology*. 2011; **25(1)**: 69-79.
16. Lötters F, Burdorf A, Kuiper J, Miedema H. Model for the work-relatedness of low-back pain. *Scandinavian Journal of Work, Environment & Health*. 2003; **29(6)**: 431-40.
17. Oda H, Matsuzaki H, Tokuhashi Y, Wakabayashi K, Uematsu Y, Iwahashi M. Degeneration of intervertebral discs due to smoking: experimental assessment in a rat-smoking model. *Journal of Orthopaedic Science*. 2004; **9(2)**: 135-41.
18. Taher F, Essig D, Lebl DR, Hughes AP, Sama AA, Cammisa FP, et al. Lumbar Degenerative Disc Disease: Current and Future Concepts of Diagnosis and Management. *Advances in Orthopedics*. 2012; **2012**: 1-7
19. Yen C, Beckman J, Vivas A, Bach K, Uribe J. Effects of intradiscal vacuum phenomenon on surgical outcome of lateral interbody fusion for degenerative lumbar disease. *Journal of Neurosurgery: Spine*. 2017; **26(4)**: 419-25.
20. Schröder J, Marschalek N, Hufeland M, Perka C. The 'Hip Vacuum Sign' - a new radiographic phenomenon in femoro-acetabular impingement. *Journal of Hip Preservation Surgery*. 2016; hnw018