

# COMPARISON OF ELASTOGRAPHY AND SUPERB-MICROVASCULAR IMAGING (SMI) WITH GREY SCALE ULTRASOUND AND DOPPLER RESPECTIVELY IN BENIGN AND MALIGNANT BREAST LESIONS

Arifa Mobeen,<sup>1</sup> Syed Amir Gilani,<sup>1</sup> Rafia Shahzad,<sup>2</sup> Sajid Shaheen Malik,<sup>1</sup> Mehreen Fatima<sup>1</sup>

<sup>1</sup> University Institute of Radiological Sciences & Medical Imaging Technology, Faculty of Allied Health Sciences. The University of Lahore, Lahore, Pakistan.

<sup>2</sup> Department of Radiology, INMOL Hospital, Lahore, Pakistan.

PJR October - December 2018; 28(4): 294-299

## ABSTRACT

Ultrasound elastography (SW & Strain) is a medical imaging method that maps the elastic properties of soft tissues and provides additional characterization information for recognizing benign and malignant breast tumors over conventional sonography like clinical palpation examination but these mode shows color elasticity maps with quantitative values in real time. Doppler imaging can also help differentiate benign from malignant masses. SMI (superb microvascular imaging), new ultrasound technique for evaluating micro-vessels and is more sensitive in blood flow detection than conventional Doppler. **OBJECTIVE:** To compare elastography and superb-microvascular imaging (SMI) with grey scale ultrasound and Doppler respectively in benign and malignant breast lesions. **METHOD:** A comparative cross sectional study with convenient sampling technique was used. The study was conducted at Diagnostic Radiology Department of Institute of nuclear medicine and oncology Lahore (INMOL Hospital) from July 2016 to March 2017. A sample of 105 women with symptoms and screen detected breast masses prior to surgery, biopsy or fine-needle aspirations were selected. **RESULTS:** Comparison of ultrasound elastography, using elasticity score versus B-mode ultrasonography using breast imaging reporting and data system (BI-RADS). Tumors were considered malignant if they have elasticity score 3 or higher and elasticity values (>70 Kpa) along with the high vascularity detection on SMI. The sensitivity and specificity of BI-RADS with elastography was 98.07% and 85.71% respectively. **CONCLUSION:** Ultrasound elastography is a noninvasive and reliable method to distinguish low-risk lesions and decreasing pointless interventional diagnostic methods. If we combined B-mode ultrasound with strain, SWE and SMI on the lesions, the diagnostic performance would be improved.

**Key words:** Breast cancer, Elastography, strain elastography, shear wave elastography, superb-microvascular imaging (SMI), breast imaging reporting and data system (BI-RADS)

## Introduction

The main cause of cancer death in women worldwide is the breast cancer and it is most often diagnosed cancer throughout the world. It is accounted for 23% of all cancer cases globally.<sup>1</sup> As stated by WHO per year more than 1.2 billion people are diagnosed with breast cancer throughout the world.<sup>2</sup> Pakistan has the highest incidence of breast cancer in Asia. Com-

pared to neighboring countries like India and Iran it is 2.5 times higher accounting for 34.6% of the female cancer.<sup>3</sup> The chance of a women to develop breast cancer in her life is approximately 1 in 8 (12%).<sup>4</sup> At present, most commonly performed diagnostic tests to detect breast cancer are palpation, mammography and sonography. Palpation is easy to perform as

**Correspondence :** Dr. Arifa Mobeen  
University Institute of Radiological Sciences &  
Medical Imaging Technology, Faculty of Allied  
Health Sciences. The University of Lahore,  
Lahore, Pakistan  
Email: arifa.haider20@yahoo.com

Submitted 13 June 2018, Accepted 9 July 2018

compared to sonography and mammography but it has limited value due to low sensitivity and confined accuracy.<sup>5</sup> Clinicians cannot detect breast tumors in patients with dense breasts, in about 50% of cases. Mammography can diagnose breast cancer early by revealing ill-defined or speculated margins or some indirect sign, such as sand like and acupunctate like calcifications. However, when it is performed in dense or thick breast tissue, may often yield false-negative outcomes. Also, there are some limitations to mammography which has been reported by some researchers when trying to detect lobular cancer, intraductal cancer without characteristic microcalcifications, multifocal cancer, local invasive cancer, and recurrent cancer after hormone replacement therapy. Sonography is very suitable as screening tool as compared to other methods mentioned above because of the following advantages: non-invasive procedure, simple and real-time dynamic imaging.<sup>6</sup> It tends to be a better predictor of tumor size than mammography and may detect intraductal tumours extension.<sup>7</sup> There are characteristic malignant features on ultrasound: carcinomas are seen as ill-defined masses and are markedly hypoechoic compared with the surrounding fat. Carcinomas tend to be taller than they are wide (the anterior to posterior dimension is greater than the transverse diameter). The texture, size and margins of the tumors helps to decide whether cancer is present or not. On ultrasound normal nodes are well-defined oval hypoechoic masses with a central echogenic area representing the fatty hilum. In women with breast cancer it has been long recognized that, involvement of axillary lymph nodes are one of the most important prognostic factor.<sup>8</sup> Elastography is a medical imaging method that maps the elastic properties of soft tissue. Elasticity is defined as mechanical and biologic property; it measures stiffness of soft tissues which may be different in normal and diseased organs. Benign and malignant tumors of the breast can be differentiated using strain elastography which displays stiffness in color map. Strain elastography is a real time imaging technique that utilizes an external force to deform tissues to estimates tissue stiffness from the degree of deformation. Hence this technique is based on the fact harder tissues deform less than soft tissues under external force resulting in different strain values. Elastography has been utilized as a technique to differentiate benign

and malignant masses of breast.<sup>9</sup> A new type of elastography is shear wave elastography that shows color elasticity maps in real time in the form of quantitative values along with the propagation waves. To produce shear waves a high intensity pulse is transmitted, that extends laterally from the source. The propagation waves of SWE can be displayed. Cancerous tumors will often be harder than the surrounding tissue, and have more propagation speed (m/s) and more stiffness (Kpal).<sup>10</sup> Elasticity of tissue can be measured from the shear wave transmission speed by the Young Modulus formula. Elasticity can be calculated quantitatively; the resulting elasticity index is measured in Kpal or m/s and can be displayed in terms of mean, maximum or minimum elasticity. Strain elastography can assess the tissue elasticity by color map and fat-to-lesion ratio.<sup>11</sup> The innovative ultrasound technique called SMI, for superb microvascular imaging has proven superior to conventional color and power Doppler ultrasound imaging when it comes to evaluating tumor vascularity in breast cancer. Accurately assessing tumor vascularity can give clinicians key diagnostic and prognostic information. SMI uses multidimensional filter to cancel out clutter without losing depiction of blood flowing at extremely low velocity.<sup>12</sup> The BI-RADS is designed to standardize breast imaging - reporting and data system which has been widely adopted as risk assessment and quality assurance technique in mammography and ultrasound, the latest version classified lesion in to six categories. BI-RADS are designed to standardize breast imaging reporting and to reduce confusion in breast imaging interpretation. It also eases out come and quality evaluation.<sup>13</sup>

Therefore, the aim of the study was to appraise the performance and accuracy of shear wave elastography, strain elastography and SMI comparing with BI-RADS classification of greyscale images and Doppler to differentiate benign/malignant lesions.

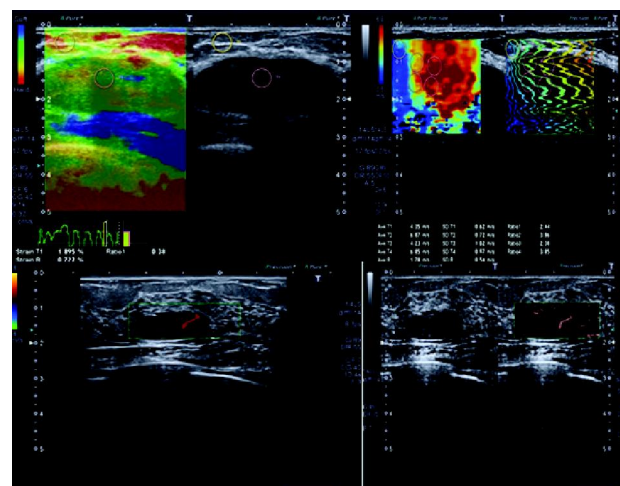
## Methods

A comparative cross sectional study with convenient sampling technique was used after approval from institute ethical review board. This study was conducted at Radiology Department Institute of nuclear medicine and oncology Lahore (INMOL Hospital)

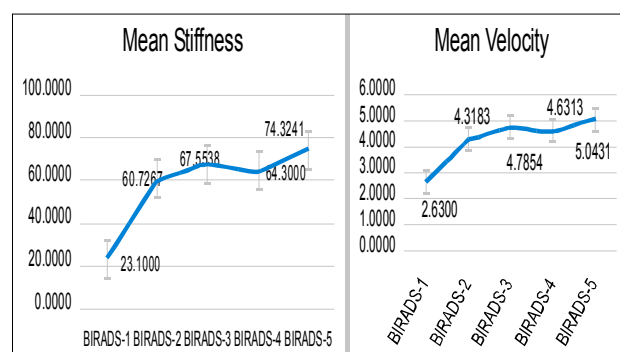
from July 2016 to March 2017. A sample of 105 women with symptoms and screen detected breast masses before surgery, biopsy or fine-needle aspirations were included after approval from ethical committees. Patients were scanned by an ultrasound scanner (Toshiba Aplio-500) with a 7 - 14 MHz high frequency linear probe with strain elastography, SWE and SMI software. The entire breast was examined, with particular attention paid to the region that contained the breast mass.

## Results

In this comparative cross-sectional study, samples of 105 patients with the mean age of  $35.53 \pm 13.46$  ranging from 14 to 70 years were included. All patients underwent sonography (B-mode) and sono-elastography including strain and shearwave elastography. According to the elasticity scores on strain elastography, breast lesions were classified into benign suspicious and malignant. Of all lesions, 37 (35%) were benign, 14 (13%) were suspicious and 54 (51%) malignant (Tab. 1 and Fig. 4). On strain elastography most malignant lesions showed high elasticity score (FLR >3) and benign lesions showed low elasticity scores (FLR < 2.2). On SWE most malignant lesions showed high elasticity values (>70 Kpa) and most benign lesions showed low elasticity values ( $\leq 60$  Kpa) (Fig. 1 and 2). The mean elasticity in Kpa and mean elasticity scores in m/s (velocity) on SW and strain elastography increases as BI-RADS scores increases (Fig. 3). The sensitivity and specificity of

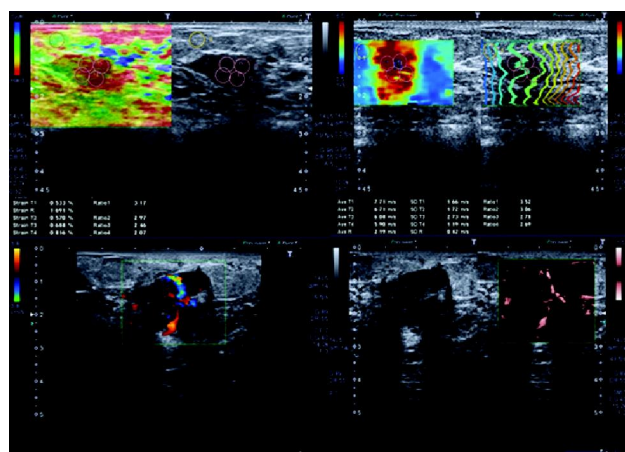


**Figure 2:** Benign breast lesion showing Lesion is soft (Green color) with FLR 0.38 along with same vascularity on SMI and conventional Doppler



**Figure 3:** Graphical presentation showing Mean stiffness (SW) in Kpa and mean velocity (strain elastography) in m/s according to the BI-RADS

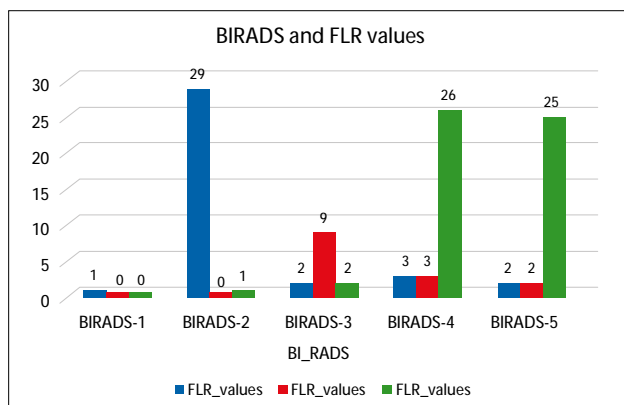
B-mode ultrasound alone were 68.4% and 78.5% respectively,<sup>25</sup> where as in this study the sensitivity and specificity of B-mode ultrasound with elastography were 98.07% and 85.71% respectively. By contrast, a statistically significant difference was noted. On color Doppler SMI is more sensitive than conventional Doppler in flow detection of breast lesions (Fig. 5).



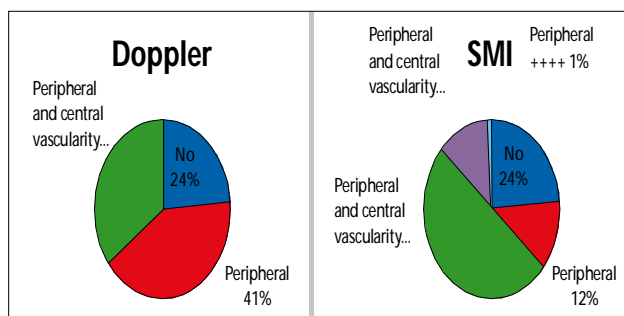
**Figure 1:** Malignant breast lesion showing Lesion is hard (Red color) with FLR 3.17 along with high vascularity on SMI than conventional Doppler

		Benign Lesion	Suspicious Lesion	Malignant	Total
BI-RADS	BIRADS-1	1	0	0	1
	BIRADS-2	29	0	1	30
	BIRADS-3	2	9	2	13
	BIRADS-4	3	3	26	32
	BIRADS-5	2	2	25	29
Total		37	14	54	105

**Table 1:** Breast lesions were classified into benign suspicious and malignant according to the FLR (strain elastography) and BI-RADS



**Figure 4:** Graphical presentation showing benign suspicious and malignant according to the FLR (strain elastography) and BI-RADS



**Figure 5:** Frequency distribution showing of conventional Doppler and SMI

## Discussion

Sono-elastography is a valuable tool acquire information about the hardness of a tumor. Like a clinical palpation examination, elastography utilizes the fat to lesion ratio (FLR) and shear waves (SW) propagating through the lesion to differentiate breast masses. The results of our study revealed significantly greater strain ratio of the malignant masses as compared to the benign masses, as 3 or above ratio for malignant masses, 2.4 to 2.9 as suspicious masses and below 2.4 as benign masses. According to the FLR on strain elastography, breast lesions were classified into benign suspicious and malignant masses and compared with BI-RADS categories. Previous studies showed that greyscale ultrasound and SWE are very sensitive for detection of malignancy and the strain index based on the FLR has diagnostic accuracy comparable with that of B-mode sonography for differentiation of benign and malignant breast lesions.<sup>15,16,17,18</sup> In this study, when

comparing B-mode ultrasound with elastography the sensitivity and specificity were 98.07 % and 85.71 % respectively. The sensitivity and specificity of B-mode ultrasound alone were 68.4% and 78.5% respectively.<sup>25</sup> As the previous studies conducted by Chang JM et.al, and Thomas A et.al, showed that corresponding to tumor grade, breast thickness and lesion histological profile specificity and sensitivity of strain and shear wave elastography were different, but can improve overall diagnostic performance, and calculation of SRs contributes to the standardization of sono elastography with high sensitivity allows significant differentiation of benign and malignant breast lesions.<sup>14,20</sup> Furthermore strain US imaging can help to effectively classify benign and malignant breast masses.<sup>19,22</sup> In addition in this study, the innovative ultrasound technique called SMI, for superb microvascular imaging, has proven superior to conventional color Doppler. Previous studies showed that in the differential diagnosis of avascular benign and malignant breast lesions SMI was valuable, particularly those in BI-RADS category 4/3.<sup>24</sup> Although biopsy remains the gold standard for diagnosis of suspicious breast lesion, a large proportion of biopsy specimens are benign.<sup>21</sup> Therefore, to minimize unnecessary interventional procedures, a reliable and noninvasive method would be very fruitful. Ultrasound elastography is a very uncomplicated and rapid method with superior sensitivity and specificity as compared to conventional sonography for detecting breast tumors. If we combine B-mode ultrasound with strain, SWE and SMI, the diagnostic values would be enhanced.

## Conclusion

Ultrasound elastography is a noninvasive and reliable method to distinguish low-risk lesions and decreasing pointless interventional diagnostic methods. It's an extremely simple and fast technique with better sensitivity and specificity over conventional sonography for identifying breast tumors. If we combined B-mode ultrasound with strain, SWE and do SMI on the lesions the diagnostic values would be boost.

**Conflict of Interest:** None



## References

1. Jemal A, Bray F, Centre M M, et al. Global Cancer statistics. *Ca Cancer J Clin.* 2015; **61**: 69-90.
2. Zahra f, Humayoun F, Yousaf T, Khan NA. Evaluation of risk factors for carcinoma breast in Pakistani women. *J Fatima Jinnah Med assoc.* 2014; **1**: 34-8.
3. Shaukat U, Ismail M, Mahmood N. Epidemiology, Major risk factor and genetic predisposition for breast cancer in the Pakistani population. *Asia pacific journal of cancer prevention.* 2016; **14**: 10-4.
4. American Cancer Society. Detailed Guide: Breast Cancer what are the key Statistics for Cancer? American Cancer Society Cancer Resource. <http://www.cancer.org/dcroot/home/index.asp>
5. Gong X, Wang Y, Xu P. Application of Real-time Ultrasound Elastography for Differential Diagnosis of Breast Tumors. *Journal of Ultrasound in Medicine.* 2013; **32(12)**: 2171-6.
6. Andreas Adam, Adrian k. Dixon, Jonathan H, Gillard and Cornela M. Grainger & Allison Radiology: A Textbook of Medical Imaging 6th edition. 2015; **978**: 4295-9.
7. Evans A J, Pinder S E, Snead D R J, et al. The detection of ductal carcinoma in situ at mammographic screening enables the diagnosis of Small, Grade 3 invasive tumours. *Br J Cancer* 2016; **75**: 542-4.
8. Demera A, Evans A J, Conford E J, et al. Diagnosis of axillary nodal metastases by ultrasound guided core biopsy in primary operable breast cancer. *Br J Cancer* 2016; **89**: 1310-3.
9. Jung HJ, Hahn SY, Choi HY, Park SH, Park HK. Breast Sonographic Elastography Using an Advanced Breast Tissue-Specific Imaging Preset. *Journal of Ultrasound in Medicine.* 2012; **31(2)**: 273-80.
10. Olgun DÇ, Korkmazer B, Kiliç F, Dikici AS, Velideoglu M, Aydogan F, Kantarci F, Yilmaz MH. Use of shear wave elastography to differentiate benign and malignant breast lesions. *Diagnostic and Interventional Radiology.* 2014 ; **20(3)**: 239.
11. Evans A, Whelehan P, Thomson K, Brauer K, Jordan L, Purdie C, McLean D, Baker L, Vinnicombe S, Thompson A. Differentiating benign from malignant solid breast masses: value of shear wave elastography according to lesion stiffness combined with greyscale ultrasound according to BI-RADS classification. *British journal of cancer.* 2012; **107(2)**: 224-9.
12. Ma Y, Li G, Li J, Ren WD. The diagnostic value of superb microvascular imaging (SMI) in detecting blood flow signals of breast lesions: a preliminary study comparing SMI to color Doppler flow imaging. *Medicine.* 2015; **94(36)**: 690-9.
13. American college of Radiology. Breast Imaging Reporting and Data System: Mammography. 4th edition. Reston, VA: American College of Radiology 2015.
14. Chang JM, Won JK, Lee KB, Park IA, Yi A, Moon WK. Comparison of shear-wave and strain ultrasound elastography in the differentiation of benign and malignant breast lesions. *American Journal of Roentgenology.* 2013; **201(2)**: W347-56.
15. Evans A, Whelehan P, Thomson K, Brauer K, Jordan L, Purdie C, McLean D, Baker L, Vinnicombe S, Thompson A. Differentiating benign from malignant solid breast masses: value of shear wave elastography according to lesion stiffness combined with greyscale ultrasound according to BI-RADS classification. *British journal of cancer.* 2012; **107(2)**: 224.
16. Cho N, Moon WK, Kim HY, Chang JM, Park SH, Lyou CY. Sonoelastographic strain index for differentiation of benign and malignant nonpalpable breast masses. *Journal of Ultrasound in Medicine.* 2010; **29(1)**: 1-7.



17. Gong X, Wang Y, Xu P. Application of Real-time Ultrasound Elastography for Differential Diagnosis of Breast Tumors. *Journal of Ultrasound in Medicine*. 2013; **32(12)**: 2171-6.
18. Olgun DÇ, Korkmazer B, Kiliç F, Dikici AS, Velidedeoglu M, Aydogan F, Kantarci F, Yilmaz MH. Use of shear wave elastography to differentiate benign and malignant breast lesions. *Diagnostic and Interventional Radiology*. 2014; **20(3)**: 239.
19. Burnside ES, Hall TJ, Sommer AM, Hesley GK, Sisney GA, Svensson WE, Fine JP, Jiang J, Hangiandreou NJ. Differentiating benign from malignant solid breast masses with US strain imaging. *Radiology*. 2007; **245(2)**: 401-10.
20. Thomas A, Degenhardt F, Farrokh A, Wojcinski S, Slowinski T, Fischer T. Significant differentiation of focal breast lesions: calculation of strain ratio in breast sonoelastography. *Academic radiology*. 2010; **17(5)**: 558-63.
21. Sadigh G, Carlos RC, Neal CH, Dwamena BA. Ultrasonographic differentiation of malignant from benign breast lesions: a meta-analytic comparison of elasticity and BIRADS scoring. *Breast cancer research and treatment*. 2012; **133(1)**: 23-35.
22. Itoh A, Ueno E, Tohno E, Kamma H, Takahashi H, Shiina T, Yamakawa M, Matsumura T. Breast disease: clinical application of US elastography for diagnosis. *Radiology*. 2006; **239(2)**: 341-50.
23. Zhan J, Diao XH, Jin JM, Chen L, Chen Y. Superb microvascular imaging - a new vascular detecting ultrasonographic technique for avascular breast masses: a preliminary study. *European journal of radiology*. 2016; **85(5)**: 915-21.
24. Ma Y, Li G, Li J, Ren WD. The diagnostic value of superb microvascular imaging (SMI) in detecting blood flow signals of breast lesions: a preliminary study comparing SMI to color Doppler flow imaging. *Medicine*. 2015; **94(36)**.
25. Bartolotta TV, Ienzi R, Cirino A, Genova C, Ienzi F, Pitarresi D, Safina E, Midiri M. Characterisation of indeterminate focal breast lesions on grey-scale ultrasound: role of ultrasound elastography. *La radiologia medica*. 2011; **116(7)**: 1027.