

# PRIMARY SYNOVIAL CHONDROMATOSIS OF ANKLE JOINT: A CASE REPORT

Ruchira Das,<sup>1</sup> Sudipta Saha,<sup>1</sup> Samiran Samanta,<sup>1</sup> Nilanjan Panda<sup>2</sup>

<sup>1</sup> Department of Radiodiagnosis, Institute of Post-Graduate Medical Education and Research and Seth Sukhlal Karnani Memorial (IPGME&R and SSKM) Hospital, Kolkata, West Bengal, India

<sup>2</sup> Department of Surgery, R. G. Kar Medical College & Hospital, Kolkata, India.

PJR October - December 2015; 25(4): 164-167

## ABSTRACT

Primary synovial osteochondromatosis is an uncommon usually benign disorder characterized by the presence of metaplastic cartilage nodules originating from the synovia, bursa and tendon sheaths. It presents unilaterally in large joints such as the knee but can occur in the shoulder and elbow. Involvement of ankle is rare. Although may be asymptomatic, common complains include pain, swelling and decreased range of motion. In the early stage, diagnosis can only be confirmed by MRI. When unmineralised synovium detaches and calcifies it is easily picked up by conventional radiography. Treatment is mainly surgical but depends on symptoms and stage of disease. Long term complications include malignant transformation and progressive secondary osteoarthritis. We report here a rare case of primary synovial carcinomatosis involving ankle joint. It is important to be aware of this condition to prevent incorrect diagnosis and unjustified surgery.

**Key words:** Synovial chondromatosis, Primary, Ankle, Loose bodies

## Introduction

Primary synovial osteochondromatosis is an uncommon generally benign disorder characterized by formation of cartilaginous bodies within the synovia of the different joints, tendon sheaths and bursae. Although often benign, malignant transformation can occur.<sup>1</sup> Aetiology is unknown, however, there are data suggesting neoplastic origin with chromosome-6 abnormalities.<sup>1</sup> It typically presents unilaterally in large joints such as the knee but can occur in the shoulder, elbow, hip, ankle and temporomandibular joints.<sup>2</sup> Symptoms include pain, swelling and decreased range of motion. Diagnosis is by radiographs and MRI. In the early stage of the disease, only active synovitis is present, and radiographs are negative. In the late stage loose bodies can be detected. We present here a case of primary synovial chondro-

matosis of the ankle joint, its radiographic and MRI features and a brief review.

## Case Presentation

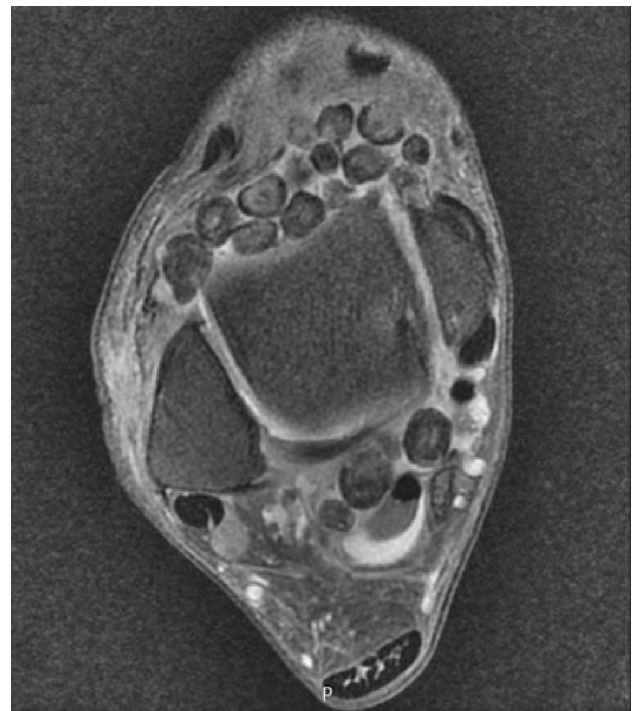A 31 year old male patient presented with pain and palpable mass on his right ankle which was first noticed two year ago. There was no history of trauma or any other inflammatory or infectious disease. On examination there was a swelling in the region of the glenohumeral joint but there was no tenderness of the palpable mass. There was a previous history of locking and swelling in both ankles. The locking was usually accompanied by decreased active dorsiflexion until the patient manually self-mobilized the ankle. No neurological deficits of his right upper arm were found. Radiograph of the right ankle joint was ordered. The radiographs illustrated several calcific loose

**Correspondence** : Dr. Ruchira Das  
Department of Radiology, (IPGME&R and SSKM) Hospital, Kolkata 700020, West Bengal, India.  
Mobile: +919433775216  
Email: dr.ruchiradas@gmail.com

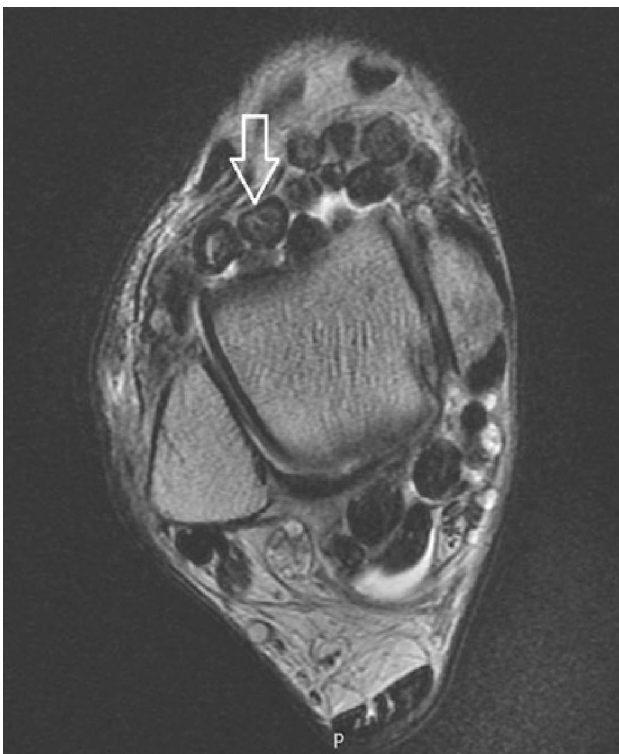
Submitted 19 June 2015, Accepted 7 July 2015

bodies projecting posterior to the tibio-talar joint with additional loose bodies anterior to the joint. The ankle mortise and subtalar joint spaces were well maintained. MRI was done which revealed multiple loose bodies, all of similar sizes. Target appearances of loose bodies were seen in some with a low intensity peripheral rim and a relatively hyperintense centre on both T1 and T2 weighted images (Fig. 1). Some loose bodies appeared homogeneously hypointense in T1 and T2. No loss of signal was noted in T2 FS sequence (Fig. 2). Loose bodies appeared more prominent in gradient echo images (Fig. 3). Synovial hypertrophy, seen as frond like hypointensities in T2 and T2 FS sequences were noted in the posterolateral aspect of the joint cavity (Fig. 4). A diagnosis of primary synovial chondromatosis was made.

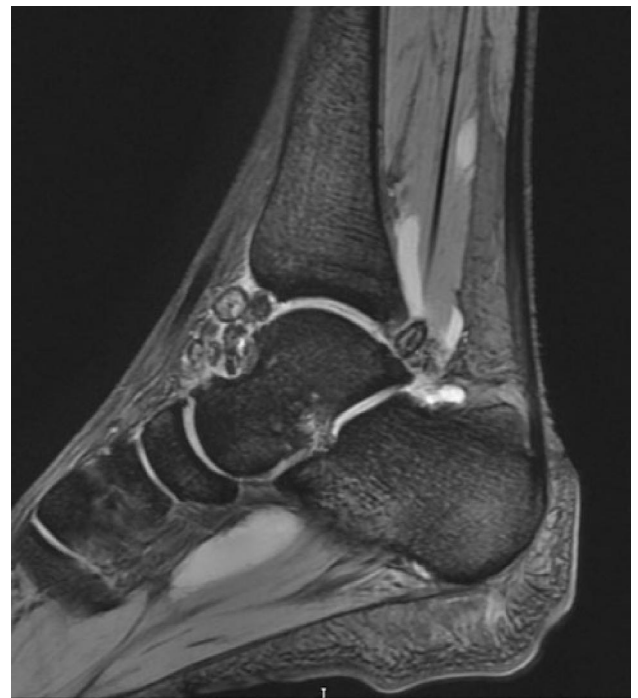Orthopaedic consult suggested surgery; however the patient choose to defer the surgery temporarily. He was started on conservative therapy for pain and asked to return on follow up.



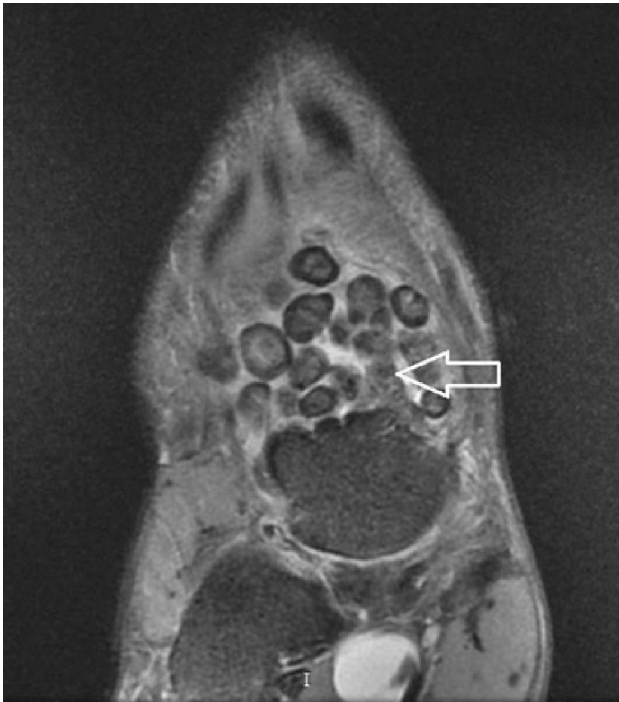**Figure 2:** MRI (Axial PD fat saturated image) of right ankle joint showing no loss of signal in loose bodies.



**Figure 1:** MRI (Axial T2 weighted image) of right ankle joint showing loose bodies with low signal intensity rim and relatively hyperintense centre (white arrow).



**Figure 3:** MRI (Sagittal GRE image) of right ankle joint showing increased prominence of loose bodies with typical target appearance.



**Figure 4:** MRI (Coronal PD fat saturated image) of right ankle joint showing frond like hypointense synovium in the posterior aspect of knee joint (white arrow).

## Discussion

Synovial chondromatosis can be primary or secondary. Primary Synovial osteochondromatosis is an unusual benign metaplastic disorder of the synovium which affects usually young and middle-aged men.<sup>3</sup> It is characterized by the presence of cartilaginous nodules in the synovium of joints, or extraarticular sites like tendon sheaths and bursae. There are a variety of names for this lesion. The most commonly accepted are synovial chondromatosis, synoviochondrometaplasia, synovial chondrosis, synovial osteochondromatosis, and articular chondrosis.<sup>4</sup> Usually a single joint is involved. Most frequently affected sites are knee, followed by hip, shoulder, elbow and ankle.<sup>2</sup>

Onset is insidious and occurs over months to years. Clinical manifestations include swelling, palpable mass, pain, tenderness, and limited joint motion. Complications include secondary degenerative osteoarthritis due to chronic mechanical irritation by loose bodies and rarely malignant transformation to chondrosarcoma.<sup>5</sup>

The exact cause is unknown. Data suggest neoplastic origin with chromosome 6 abnormalities. Milgram, in 1977, categorized the disease process into 3 distinct phases.<sup>6</sup> In phase I, metaplasia of the synovial intima occurs. Active synovitis and nodule formation is present, but no calcifications can be identified. In phase II, nodular synovitis and loose bodies are present in the joint. The loose bodies are primarily still cartilaginous. In phase III, the loose bodies remain but the synovitis has resolved. The loose bodies also have a tendency to unite and calcify.<sup>6</sup> Radiographic features of primary synovial chondromatosis are quite variable. In up to one third of cases of synovial chondromatosis no calcification is apparent on plain radiographs.<sup>5</sup> When mineralisation occurs multiple intra-articular and peri-articular loose bodies are seen, usually of similar sizes, with relatively less radiodense centres. Computerised tomography (CT) is more sensitive than conventional radiography. Tiny foci of calcification in a soft tissue mass either intra-articular or in adjacent bursa is highly suggestive of synovial chondromatosis.<sup>5</sup> MRI enables the diagnosis of the disease in the early stage. Unmineralised synovial chondromatosis is seen as mildly inhomogeneous lobular loose bodies often resembling fluid signal intensity. In calcified lesions, multiple foci or round bodies of low signal intensity is noted in all sequences which appear more prominent in gradient echo MR imaging.<sup>7</sup> Few authors have described the characteristic MRI findings as target appearance of some loose bodies with peripheral hypointense rim and the centre isointense to synovium on T1 images which do not change on T2 weighted image. Conversely other loose bodies were characterised by homogenous hyperintensity close to bone marrow on T1 weighted image with loss of signal on T2 WI.<sup>8</sup> The most common differential diagnosis of primary synovial chondromatosis is secondary synovial chondromatosis. Primary synovial chondromatosis is characterized by undifferentiated stem cell proliferation in the stratum synoviale in an otherwise normal joint.<sup>9</sup> Via immunostaining, it has been concluded that primary synovial chondromatosis is a caused due to metaplastic proliferation of synovial cells which then detach and calcify to form intra-articular loose bodies.<sup>10</sup> Recurrence following surgical excision may occur. Secondary synovial chondromatosis on the other hand is thought to be caused

by synovial proliferation secondary to irritation secondary to cartilage fragments which detach from the articular surface and get embedded in the synovium.<sup>7</sup> This form is usually associated with osteo-arthritis, osteochondritis dissecans and avascular necrosis.<sup>7</sup> Recurrence following surgical excision and malignant transformation are unlikely. Other differential diagnosis include pigmented villonodular-synovitis, synovial chondrosarcoma, synovial hemangioma, dystrophic soft tissue calcification and rarely lipoma arborescens with osseous metaplasia.<sup>5</sup> Surgical treatment depends on level of symptoms, patient's age and stage of disease. Due to risk of recurrence, asymptomatic disease is managed by watchful waiting. In young symptomatic individuals arthroscopic debridement is sufficient to achieve cure.<sup>7</sup> Resection of loose bodies and synovectomy is indicated if synovitis is present due to the increased recurrence rate in patients with synovitis.<sup>7</sup> Prognosis following surgical excision is reported to be excellent.<sup>2,7</sup>

## Conclusion

Primary synovial chondromatosis of the ankle is a rare entity and lack of awareness of this condition may lead to incorrect diagnosis and unnecessary surgery. Due to risk of malignant transformation regular follow up for such patients are mandatory.

## References

1. Taconis WK, van der Heul RO, Taminiau AMM: Synovial chondrosarcoma: report of a case and review of the literature. *Skeletal Radiol* 1997; **26**: 682-5.
2. Yu GV, Zema RL, Johnson RWS: Synovial Osteochondromatosis. A case report and review of the literature. *J Am Podiatr Med Assoc Journal* 2002; **92**: 247-54.
3. Milgram JW, Hadesman WM. Synovial osteochondromatosis in the subacromial bursa. *Clin Orthop Relat Res* 1988; **236**: 154-9.
4. Krebs VE: The role of hip arthroscopy in the treatment of synovial disorders and loose bodies. *Clin Orthop Rel Resch* 2003; **406**: 48-59.
5. Kiritsi O, Tsitas K, Grollios G A case of idiopathic bursal synovial chondromatosis resembling rheumatoid arthritis *HIPPOKRATIA* 2009, 13, **1**: 61-3.
6. Milgram JW: Synovial osteochondromatosis: A histopathological study of thirty cases. *J Bone Joint Surg* 1977, **59**: 792-801.
7. Shearer H, Stern P, Brubacher A, Pringle T. A case report of bilateral synovial chondromatosis of the ankle. *Chiropractic & Osteopathy*. 2007; **15**: 18.
8. Blandino A, Salvi L, Chirico G et al., "Synovial osteochondromatosis of the ankle: MR findings," *Clinical Imaging*, 1992; **16(1)**: 34-6.
9. Leu JZ, Matsubara T, Hirohata K: Ultrastructural morphology of early cellular changes in the synovium of primary synovial chondromatosis. *Clin Orthop* 1992, **276**: 299-306.
10. Davis RI, Foster H, Biggart DJ: C-erb B-2 staining in primary synovial chondromatosis: a comparison with other cartilaginous tumours. *J Pathol* 1996, **179**: 392-5.