

LITTLE SHINY DOTS IN THE FETAL HEART. SHOULD WE BE CONCERNED?

Kiran, Imrana Masroor, Zainab Hussain, Anam Khan

Department of Radiology, Aga Khan University Hospital, Karachi, Pakistan

PJR October - December 2015; 25(4): 149-153

ABSTRACT

OBJECTIVE: To evaluate the impact of fetal intracardiac echogenic focus (EIF) in relation to fetal outcome. **METHODOLOGY:** A descriptive cross-sectional study conducted at Radiology department of Aga Khan University Hospital (from January 2009 till January 2012). All fetuses found to have intracardiac echogenic focus during 2nd trimester anomaly scan were included in the study. The outcome was defined as echocardiography or post-delivery notes from confidential files. **RESULTS:** A total of 8000 fetuses were evaluated in 2nd trimester with ultrasound during the study period. In 138 fetuses echogenic intracardiac focus was identified. In 125 fetuses this was an isolated finding and in 13 (9.5 %) fetuses this was associated with other soft markers such as pyelectasis or choroid plexus cyst. A total number of 38 patients had echocardiography. Echo findings were abnormal in 10 (7.2%) fetuses. Karyotyping was performed only in two fetuses after birth because of clinical suspicious of aneuploidy and results were normal. All fetuses were reported to be normal at birth. **CONCLUSION:** All fetuses with isolated intracardiac echogenic focus or echogenic focus with other soft markers were reported as normal in their post natal period. Our results suggest that the presence of EIF has no significant association with abnormal fetal out come. Considering abnormal echocardiography findings in 6.5 % patients, we emphasize for further future studies to evaluate the hemodynamic significance of echogenic focus in fetal heart. **Keywords:** Echogenic intra cardiac focus, postnatal fetal outcome, prenatal ultrasound.

Introduction

Presence of intracardiac echogenic focus (EIF) in fetal heart has been controversial in the literature for the past years. Echogenic intracardiac focus identified in fetal heart appears as echogenic as calcium on ultrasound anomaly scan. Anomaly scan is detailed ultrasound screening for fetal abnormalities performed in second trimester.¹ Echogenic intracardiac focus in the fetal heart was first illustrated in the past in 1987 as a benign finding.²

This is present mostly as single discrete focus in ventricles commonly in left but occasionally seen in right or in both ventricle as multiple foci. It is commonly detected in fetal routine anatomical survey on ultra-

sound during 2nd trimester.³⁻⁵ On histological examination the foci are reported to be coarse, focal intra myocardial calcification surrounded by fibrotic issue without any ischemia, inflammation or hemorrhage. Echogenic cardiac foci are present near the papillary muscle and chordae tendinae or described as calcification present in papillary muscles. The cause of these pathological changes is still unknown.⁶ The prevalence of EIF is linked to racial variation and this is also confirmed by past studies. In South-East population, its reported prevalence is 30% in normal fetuses.⁶⁻⁸ The reported incidence is between 0.17%¹⁰ up to 30%.¹¹

Various previous studies showed its association with aneuploidy.¹²⁻¹⁵ These results are in contrast to those

Correspondence : Dr. Anam Khan
Department of Radiology,
Aga Khan University Hospital,
Karachi, Pakistan.
Tel: 34930051 - Ext.: 2020
Email: anam.khan@aku.edu

Submitted 14 May 2015, Accepted 5 June 2015

studies which suggested that isolated intracardiac echogenic focus is a least sufficient marker for aneuploidy.¹⁶⁻¹⁹ Currently only one study is done in Pakistan regarding this perspective, which targeted a specific high risk population who were referred by the primary physicians because of high risk factors.²⁰ No study has been done in Pakistan targeting the general population. Its significance is still ambiguous as a soft marker and its hemodynamic significance is still dubious especially in our low risk population. The most important dilemma is either these cases should be considered as benign findings or should be evaluated further. Further investigation are not only expensive and unnecessary but also cause parental apprehension and lead to additional counseling sessions with referring obstetricians. In some cases this may lead to unnecessary invasive investigations with a potential for fetal loss e.g. amniocentesis.

The objective of this retrospective study was to evaluate impact of EIF on fetal out come in general population and its prevalence in our population.

Material & Methods

A descriptive study conducted at Radiology department of Aga Khan University Hospital. All fetuses found to have intracardiac echogenic focus during 2nd trimester anomaly scan from January 2009 to January 2012 were included in the study.

An EIF was defined as a fetal intracardiac lesion that appeared as bright as bone.

Study cases were identified by computer based data search. All fetuses found to have intracardiac echogenic focus during 2nd trimester anomaly scan from January 2009 to January 2012 were included in the study. Patients with incomplete medical records were excluded.

All ultrasounds were performed Trans abdominally on Xario Toshiba ultrasound.

All scans were performed and interpreted by qualified radiologist with at least 2-5 years expertise in doing anomaly scans. Data was collected for each patient regarding maternal age, presence or absence of intracardiac echogenic focus, location either right or left ventricle, multiplicity, presence on prenatal follow

up ultrasound and presence or absence of other soft marker including pylectasis, short humerus, short femur, echogenic bowel, nuchal fold thickness and choroid plexus cyst. Records were also checked for amniocentesis, pre or post natal echocardiography and karyotyping if performed. The post natal impact of intracardiac echogenic focus on fetal outcome was assessed through echocardiography or post-delivery notes from confidential files for any post natal surgical or medical intervention.

Results

A complete anomaly ultrasound (US) scan was obtained in 8000 consecutive fetuses that were referred for routine anomaly scan to our department. Total 138 (1.73%) fetuses had echogenic focus in heart. Majority of fetuses 123 (89.1%) had single echogenic cardiac focus. Out of total 111 (80.4%) fetuses had left ventricular echogenic cardiac focus, 21 (15.2%) had right ventricular and 6 (4.4%) fetuses had echogenic cardiac focus in both right ventricles (Tab. 1).

ULTRASOUND FINDINGS

	Frequency	Percent
Echogenic Cardiac Focus (N = 8000)	138	1.7 (Prevalence)
Age		
≤ 35	129	93.4
> 35	9	6.6
Echocardiography		
Present	39	28.3
Absent	99	71.7
Multiplicity		
One	123	89.1
Two	12	8.7
More the Two	3	2.2
Location		
LV	111	80.4
RV	21	15.2
Both	6	4.4

Table 1: shows the basic characteristics of the sample as seen on ultrasound followed by echocardiography

On Follow up 29 (21%) fetuses had prenatal fetal echo and 10 (7.3%) fetuses had post natal echo within first week of life. Abnormal findings on echocardiography were seen in 9 /138 (6.8%) the details of which are presented in (Tab. 2).

ECHOCARDIOGRAPHY

Abnormal echocardiography findings	Frequency	Percent
Atrial septal defect	5	3.6
Ventricular septal defect	3	2
Tricuspid atresia	1	0.7
Total	9	6.5

Table 2: Echocardiogram was performed in only 39 patients out of whom 9 patients had abnormal findings as shown in the table

Out of 138 fetuses, other soft markers were present in 13 (9.5%) cases (Pyelectasis in 10 (7.3%) and Choroid Plexus Cyst in 3 (2.2%) cases).

Karotyping was performed only in two fetuses after birth because of clinical suspicious of ambiguous genitalia and in other one because of fetal ascites and body wall edema. Both neonates showed no chromosomal abnormality. Post natal fetal outcome of all fetuses was obtained from medical records and all were reported to be normal after birth.

Discussion

There is ranging controversy about whether fetal echogenic focus has clinical importance or not. Its presence is not only controversial but also a counseling dilemma. The relationship of intracardiac echogenic focus with aneuploidy has been investigated extensively in past.¹²⁻¹⁵ Some authors do not agree with its strong association with aneuploidy. The purpose of our study was not to build its association, rather evaluate its prevalence in general population who comes for routine fetal anomaly examination along with its impact on post natal fetal outcome. The prevalence of EIF was 1.7% in our study. Previous local study²⁰ reported prevalence of 0.86 % which is comparatively low we assume that this was possibly low due to their short study duration, limited and specific population with high risk factors. Previous international studies have reported its significantly

high prevalence in Asian population up to 30.4 %.²¹ In our study, ethnicity does not has any effect on prevalence in fact in our study prevalence was low and also comparable to any other ethnic group.²¹ In 80.4% of cases echogenic focus was found in left ventricle which suggests that this is most common location in fetal heart and also consistence with past studies.²² In 89.1% cases it was single in number and in 10.9 % cases it was more than two in number. In study done by Dena et al.²³ showed that multiplicity has significant effect on fetal out come in terms of aneupliody but considering our result we conclude that multiplicity or location do not have any effect on post natal fetal outcome.

In our 13 (9.5 %) patients EIF was associated with other soft markers (Pyelectasis in 10 (7.3%) and choroid plexus cyst in 3 (2.2%)) (Fig.1). Previously significantly high prevalence of these markers was reported in fetuses with trisomy 21 but in our study all these fetuses reported to be normal in post natal period.

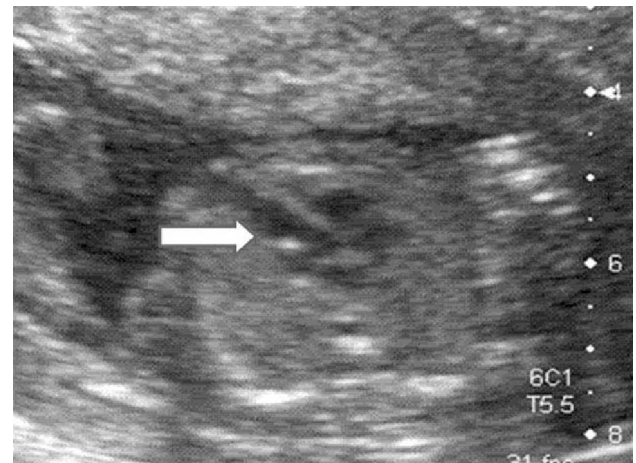


Figure 1A: Four chamber view of a fetal anomaly scan showing bright echogenic focus in left ventricle (white arrow)

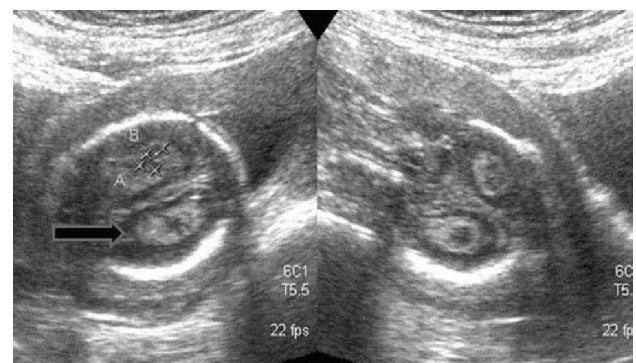


Figure 1B: Same fetus with additional finding of bilateral choroid plexus cysts (black arrow)

Majority of mothers were less than 35 years age at the time of scan but 9 mothers (8.1%) were >35 years of age at the time of scan. We did not find any influence of maternal age on fetal outcome. But this could be because of small number of patients >35 years of age in our study population as we did not stratify our study population on the basis of age because this was not the objective of this study.

Abnormal findings on echocardiography were seen in 9 /138 (6.8%) This prevalence is high in comparison with general population. We also assumed that this prevalence could be higher because only 38 fetuses with EIF had echocardiography in our study. The decision to perform echocardiography after detection of EIF on anomaly scan was solely based on referring obstetrician judgment and not pertaining to any established guidelines or protocol. A previous study²⁰ reports a high prevalence of 8.1% of congenital heart defects in fetuses with echogenic focus compared to general population. This supports the findings of our study. Therefore to assess the true impact of EIF and its association with cardiac anomalies which may be too subtle to be detected at birth such as small ASDs and VSDs, its correlation with echocardiography is recommended in larger patient cohorts. We identified some limitation in our study. Only two fetuses of our study had karyotyping not because they were clinically suspicious for aneuploidy. One had of ambiguous genitalia and other because of fetal body wall edema. But both of them were reported as normal on chromosomal analysis. The reason for not performing karyotyping on all these fetuses was that all of them were clinically normal on birth without any suspicious of aneuploidy as recommended in literature.²⁴ Echocardiography was only performed in limited cases as this was completely based on clinician judgment and preferences as no guidelines exist for this approach. Inter observer variability could not be ascertained due to the retrospective nature. We also believe that the low prevalence of EIF in our study could be because of different scan techniques as well as operator variability and reporting bias.

The prevalence of EIF is not significantly high in our population as reported in past. Our results suggest that the presence of EIF has no association with abnormal fetal out come. However considering abnormal echocardiography findings in 6.5 % patients, we

emphasize for further future studies to evaluate the hemodynamic significance of echogenic focus in fetal heart in relation to echocardiography.

Conflict of Interest

The authors report no conflicts of interest in this work.

Disclosures

The authors do not report any matter to disclose

References

1. Chitty LS. Ultrasound screening for fetal abnormalities. *Prenat Diagn.* Dec 1995; **15(13)**: 1241-57.
2. Schechter AG, Fakhry J, Shapiro LR, Gewitz MH. In utero thickening of the chordae tendinae. A cause of intracardiac echogenic foci. *J Ultrasound Med.* Dec 1987; **6(12)**: 691-5.
3. Vibhakar NI, Budorick NE, Scioscia AL, Harby LD, Mullen ML, Sklansky MS. Prevalence of aneuploidy with a cardiac intraventricular echogenic focus in an at-risk patient population. *J Ultrasound Med.* Apr 1999; **18(4)**: 265-8.
4. Levy DW, Mintz MC. The left ventricular echogenic focus: a normal finding. *AJR Am J Roentgenol.* Jan 1988; **150(1)**: 85-6.
5. Simpson JM, Cook A, Sharland G. The significance of echogenic foci in the fetal heart: a prospective study of 228 cases. *Ultrasound Obstet Gynecol.* Oct 1996; **8(4)**: 225-8.
6. Tennstedt C, Chaoui R, Vogel M, Goldner B, Dietel M. Pathologic correlation of sonographic echogenic foci in the fetal heart. *Prenat Diagn.* Apr 2000; **20(4)**: 287-92.
7. Shipp TD, Bromley B, Lieberman E, Benacerraf BR. The frequency of the detection of fetal echogenic intracardiac foci with respect to maternal race. *Ultrasound Obstet Gynecol.* Jun 2000; **15(6)**: 460-2.

8. Tran SH, Caughey AB, Norton ME. Ethnic variation in the prevalence of echogenic intracardiac foci and the association with Down syndrome. *Ultrasound Obstet Gynecol.* Aug 2005; **26(2)**: 158-61.
9. Rebarber A, Levey KA, Funai E, Monda S, Paidas M. An ethnic predilection for fetal echogenic intracardiac focus identified during targeted midtrimester ultrasound examination: A retrospective review. *BMC Pregnancy Childbirth* 2004; **4**: 12-14.
10. Bronshtein M, Jakobi P, Ofir C. Multiple fetal intracardiac echogenic foci: not always a benign sonographic finding. *Prenat Diagn.* Feb 1996; **16(2)**: 131-5.
11. Shipp TD, Bromley B, Lieberman E, Benacerraf BR. The frequency of the detection of fetal echogenic intracardiac foci with respect to maternal race. *Ultrasound Obstet Gynecol.* Jun 2000; **15(6)**: 460-2.
12. Sepulveda W, Cullen S, Nicolaidis P, Hollingsworth J, Fisk NM. Echogenic foci in the fetal heart: a marker of chromosomal abnormality. *Br J Obstet Gynaecol.* Jun 1995; **102(6)**: 490-2.
13. Bromley B, Lieberman E, Laboda L, Benacerraf BR. Echogenic intracardiac focus: a sonographic sign for fetal Down syndrome. *Obstet Gynecol.* Dec 1995; **86(6)**: 998-1001.
14. Manning JE, Ragavendra N, Sayre J, Laifer-Narin SL, Melany ML, Grant EG, et al. Significance of fetal intracardiac echogenic foci in relation to trisomy 21: a prospective sonographic study of high-risk pregnant women. *AJR Am J Roentgenol.* Apr 1998; **170(4)**: 1083-4.
15. Bromley B, Lieberman E, Shipp TD, Richardson M, Benacerraf BR. Significance of an echogenic intracardiac focus in fetuses at high and low risk for aneuploidy. *J Ultrasound Med.* Feb 1998; **17(2)**: 127-31.
16. Gupta G, Aggarwal S, Phadke SR. Intracardiac echogenic focus and fetal outcome. *J Clin Ultrasound.* Nov-Dec; **38(9)**: 466-9.
17. Bradley KE, Santulli TS, Gregory KD, Herbert W, Carlson DE, Platt LD. An isolated intracardiac echogenic focus as a marker for aneuploidy. *Am J Obstet Gynecol.* Jun 2005; **192(6)**: 2021-6.
18. Anderson N, Jyoti R. Relationship of isolated fetal intracardiac echogenic focus to trisomy 21 at the mid-trimester sonogram in women younger than 35 years. *Ultrasound Obstet Gynecol.* Apr 2003; **21(4)**: 354-8.
19. Coco C, Jeanty P, Jeanty C. An isolated echogenic heart focus is not an indication for amniocentesis in 12,672 unselected patients. *J Ultrasound Med.* Apr 2004; **23(4)**: 489-96.
20. Shakoor S, Ismail H, Munim S. Intracardiac echogenic focus and fetal outcome - review of cases from a tertiary care centre in Karachi, Pakistan. *J Matern Fetal Neonatal Med.* Jan; **26(1)**: 2-4.
21. Shipp TD, Bromley B, Lieberman E, Benacerraf BR. The frequency of the detection of fetal echogenic intracardiac foci with respect to maternal race. *Ultrasound Obstet Gynecol.* Jun 2000; **15(6)**: 460-2.
22. Bromley B, Lieberman E, Laboda L, Benacerraf BR. Echogenic intracardiac focus: a sonographic sign for fetal Down syndrome. *Obstet Gynecol.* Dec 1995; **86(6)**: 998-1001.
23. Towner D, Gerscovich EO, Chiong BB, Rhee-Morris L, McGahan JP. Comparison of single versus multiple echogenic foci in the fetal heart regarding risk of aneuploidy. *J Ultrasound Med.* Jul; **29(7)**: 1061-7.
24. McElhinney DB, Straka M, Goldmuntz E, Zackai EH. Correlation between abnormal cardiac physical examination and echocardiographic findings in neonates with Down syndrome. *Am J Med Genet.* Dec 2002; **113(3)**: 238-41.