

DARK CEREBELLAR SIGN: A CASE REPORT

Faiza Naz, Sadaf Irshad Khan, Imaad ur Rehman

Department of Radiology, Shifa International Hospital, Islamabad, Pakistan.

PJR July - September 2018; 28(3): 240-242

ABSTRACT

We are here to discuss a case of “dark cerebellar sign”, a rare sign in neuroradiology. Dark cerebellar sign is characterized by a hypoxic ischemic insult resulting in an edematous cerebellum that appears hypodense on CT scan. Our patient is a 13 year old male, known case of Acute lymphocytic leukemia (ALL) for 7 years, treated for relapse, recurrent febrile illnesses and discharged from hospital two days before presenting in ER in a collapsed state with metabolic derangements and dark cerebellar sign on CT scan. Etiology of this sign is not well established as isolated infarction of cerebellum is rare. A single case report has shown an association of TCA (tricyclic antidepressants) intoxication with dark cerebellar sign. Our case shows that metabolic derangements, hematological diseases and infections should be included in the list of differential diagnosis for isolated cerebellar infarction in children.

Key words: Dark cerebellum, Acute lymphoblastic leukemia.

Introduction

Dark cerebellar sign is characterized by a hypodense cerebellum compared to the normal density of the supratentorial brain which is a rare finding in neuro-radiology.

We present a 13 year old male, who presented with a dark cerebellar sign on non enhanced CT when compared to the CT cerebral and cerebellar findings in a healthy subject.

Case Report

A 13 year old male, a known case of ALL (Acute lymphoblastic leukemia), status post chemotherapy, has had multiple hospital admissions for recurrent febrile illnesses, discharged after a prolonged hospital stay for fungal ball in chest and oral thrush and was received in the emergency room in a collapsed state with cardiac arrest. Immediate CPR was done and normal cardiac rhythm was attained after seven minutes of CPR. Non enhanced CT scan showed a

significantly hypodense cerebellum, brainstem, with loss of cerebellar gray white matter differentiation. The cerebrum was diffusely edematous with effacement of cerebral sulci, ventricular chain and ambient cisterns. The fourth ventricle and basal cisterns were also compressed due to extensive cerebellar edema. Uncal herniation was also present. No hemorrhage or focal lesion was identified (Fig.1). This was compared to patient's previous CT scan which was normal (Fig. 2).

Biochemical analysis revealed severe hypokalemia (1.4 mmol/L). Patient had pancytopenia with a total leukocyte count of 1600, hemoglobin 9.5 and platelets 50,000. CSF routine analysis and CSF C/S examination were unremarkable. Patient remained on ventilatory and ionotropic support with a GCS of 3/15, until he expired on the fourth day of admission.

Discussion

Dark cerebellar sign is characterized by a hypodense cerebellum next to a dense supratentorial brain. The

Correspondence : Dr. Faiza Naz
Department of Radiology,
Shifa International Hospital,
Islamabad, Pakistan.
Email: faizagms@gmail.com

Submitted 15 February 2018, Accepted 2 April 2018

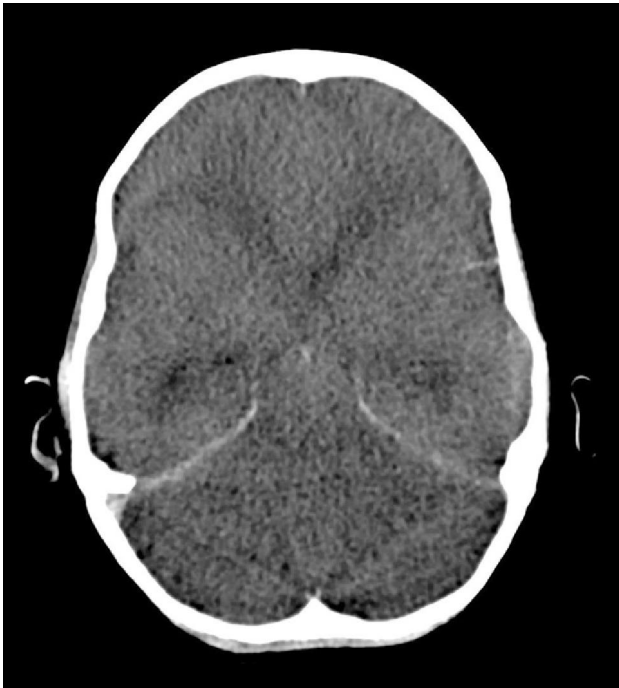

Figure 1: Dark cerebellar sign is characterized by hypodense cerebellum, which is a rare finding in neuroradiology.

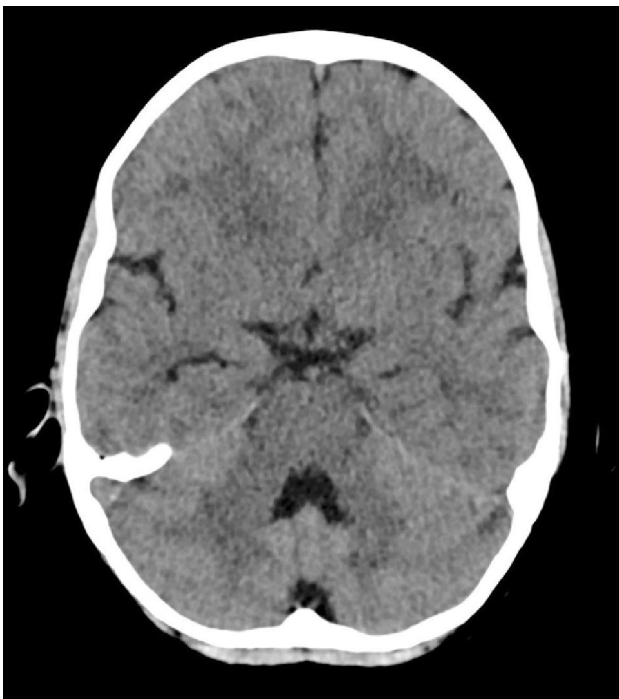

Figure 2: Normal density of cerebellum.

hypodensity of cerebellum can be attributed to the increased water content of injured brain. In regard to ischemic brain edema with each 1% increase in tissue water content X-ray attenuation will decline by

approximately 2 Hounsfield units.¹ The decrease in contrast between gray and white matter results from change in net water content which affects gray matter more than white matter. Isolated hypoxic ischemic insult of the cerebellum is most commonly caused by thromboembolic events within the vertebrobasilar vascular territory. Cerebellar infarction can be ischemic, among which 20% are related to cardiac and 70% to vascular disorders. Rest can be attributed to hematological diseases, coagulopathies, metabolic disorders or occasionally drugs² among which acute heroin intoxication has been associated and a single case report has shown an association with tricyclic antidepressant poisoning.

Our case indicates that hypoxic ischemic insult to the cerebellum may result from either infectious, metabolic or hematological disease. The etiology still remains unclear, possibility of metabolic derangements leading to cardiac arrest resulting in preferential ischemia of the cerebellum, relapsing acute lymphocytic leukemia causing selective cerebellar infarction or a combination of multiple factors.


Global hypodensity of cerebrum/cerebellum is seen in cases of prolonged cardiac arrest, profound and sustained hypoxia, or a complication of severe meningoencephalitis. The differentials may include acute cerebellitis,³ such children have acute cerebellar ataxia with diffuse cortical swelling of cerebellum. It is imperative to rule out possibility of infection in children presenting with a dark cerebellar sign.

In conclusion, isolated cerebellar infarction appears on a non-enhanced CT as a dark cerebellar sign. Isolated Cerebellar infarction is rare in children. Our case shows that metabolic derangements and hematological disease should also be included in the etiology of dark cerebellar sign.

Conflict of Interest: None

References

1. Huisman T, Kubat S, Eckhardt B. The "Dark Cerebellar Sign". *Neuropediatrics*. 2007; **38(3)**: 160-3.

-
- 
2. Krishnan PChowdhury S. "White cerebellum" sign - A dark prognosticator. *Journal of Neurosciences in Rural Practice*. 2014; **5(4)**: 433.
 3. Malik V, Murthy T, Raj V, Vyas S, Mehar U. 'White cerebellar sign' in immediate postpartum period. *Medical Journal Armed Forces India*. 2015; **71**: S163-S165.