

HYDATID CYST OF FLOOR OF MOUTH: A CASE REPORT

Sasui Memon, Nasreen Naz

Department of Radiology, Dow Medical College / Civil Hospital (DUHS), Karachi, Pakistan.

PJR April - June 2018; 28(2): 176-178

ABSTRACT

Hydatid cyst is caused by the larval stage of Echinococcus. There are four species of the Echinococcus that can produce infection in humans among them *E. granulosus* and *E. multilocularis* are most common. Hydatid cyst of floor of mouth is extremely rare. Here we present the case of hydatid cyst in 16 year female with history of swelling in floor of mouth for 1 year. This case report highlights the rare location of the hydatid cyst and its preoperative diagnosis for proper management.

Key words: Hydatid cyst, soft tissue masses, floor of mouth.

Introduction

Echinococcus granulosus is parasite that causes human hydatid disease. Dog is the definitive host and sheep is the intermediate host for parasite while humans are the accidental host.¹ Eggs enter to the portal venous system and affect liver which is most frequently involved organ (60-70%) and lungs which is second most common site (5-27%). If liver and lungs are bypassed by parasite then it may locate any organ in body which are rare locations and can have difficulties in diagnosis and management.² This unusual case of hydatid cyst emphasize the importance of radiological imaging in diagnosis and further management to avoid undue complications.

Case Report

A 16 year female patient was presented to radiology department Civil hospital, Karachi for CT scan of head and neck referred from surgical unit. She had complaint of swelling in floor of mouth for one year. There was no history of pain, fever, weight loss or trauma. Past medical and surgical history was unremarkable. There was no family history of any carcinoma. She had contact with domestic animal. On clinical examination

there was soft tissue swelling in the floor of mouth, which was non tender, firm in consistency and slightly movable. It was not adherent to skin with normal overlying skin. Routine laboratory studies were not significant.

Contrast enhanced CT scan of head and neck was performed (Fig. 1) which showed well defined cystic lesion with foci of calcification and multiple enhancing septae. It measured 2.9 x 3.4 x 3.5 cm, compressing the right submandibular gland and causing mass effect over right genioglossus, hypoglossus and mylohyoid muscle. Multiple lymph nodes were seen at cervical level IA, IB, and IIb. Complimentary ultrasound was done (Fig. 2) which showed multiseptated cystic lesion with internal echoes and floating membranes. Based on these findings possibility of hydatid cyst was raised and antibody titer IgG was advised which came to be increased. Based on clinical, radiological and patient's positive contact with domestic animals and laboratory findings diagnosis of hydatid cyst was made. Patient underwent excision of cyst and was kept on antihelminthic therapy. There were no post surgical complications and histopathology confirmed the diagnosis of hydatid cyst.

Correspondence : Dr. Sasui Memon
Department of Radiology,
Dow Medical College/Civil Hospital (DUHS),
Karachi, Pakistan.
Email: sassuimemon290@gmail.com

Submitted 6 January 2018, Accepted 3 March 2018

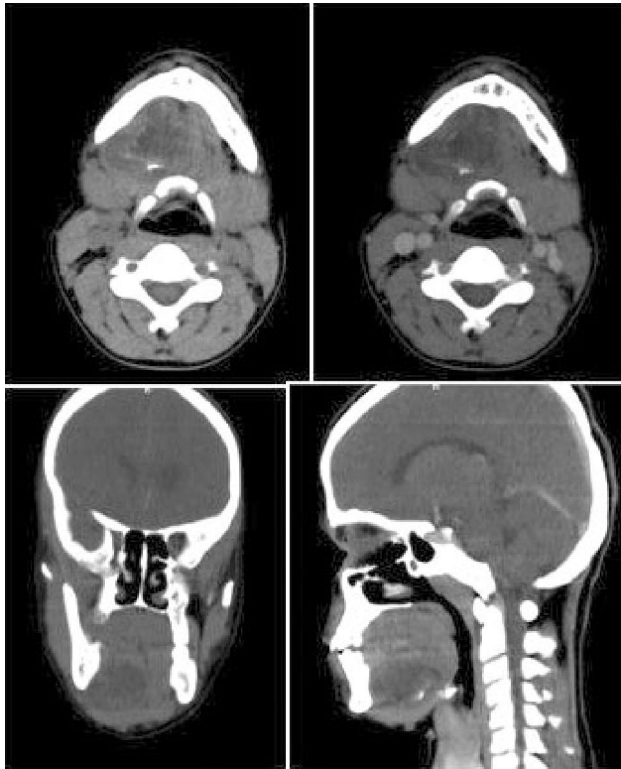


Figure 1

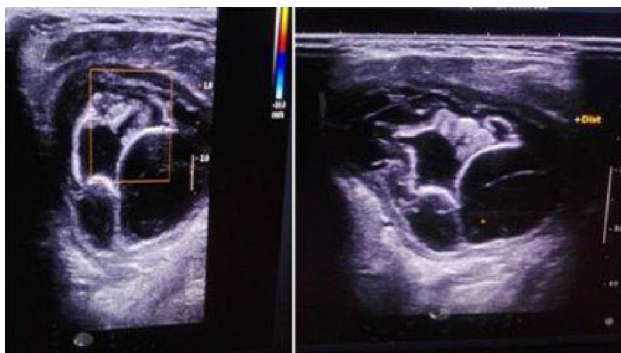


Figure 2

by lungs.³ Other locations are extremely rare and should be included in differential diagnosis of cystic lesions.⁴ Cystic lesions in the floor of the mouth can be congenital or acquired including ranulas, dermoid or epidermoid cysts, false sialoceles, hydatid cysts, and thyroglossal duct cysts.⁵ Only 2% of cases of hydatid cysts are seen in the oral and maxillofacial region. It is often symptomless but symptoms may depend upon site and size of the cyst. CT scan and ultrasound can detect the disease in early stages, however it is often confirmed by serologic test and histopathology.⁶ Hydatid cyst has variable appearance on ultrasound. 20-30% of the cyst shows calcification. The cyst may appear as well defined fluid filled collection with internal septae, and internal echoes which may settle down by repositioning the patient due to gravity, called snow storm sign. It may also show floating membrane due to detachment of endocyst from pericyst, called water lily sign. Ultrasound is said to be most sensitive modality for detection of septae, floating membranes and internal echoes.⁷ CT scan is done to detect any complications due to its high sensitivity and specificity. Hydatid cyst is seen as well defined water density round to ovoid lesion with increased attenuation of wall on unenhanced scan, however some enhancement of septae and cyst may be seen after contrast administration.⁸

Surgical removal of the cyst remains the mainstay of the treatment⁶ therefore preoperative diagnosis is mandatory which is based on clinical history, radiological findings and laboratory investigations to avoid any recurrence and complications like anaphylactic shock to patient.

Discussion

Hydatid disease is caused by the larval form of *Echinococcus granulosus*. Adult tapeworm is present in the intestine of the definitive host (carnivore) and larval form in intermediate host (herbivore). Humans are affected by ingestion of eggs in the faeces of definitive host. Liver is common affected organ followed

Conclusion

Hydatid cyst of floor of mouth is rare entity and is diagnosed on the basis of radiological imaging and serology. Surgical excision is necessary to avoid rupture and further complications. It should always be considered in patients with soft tissue mass.

References

1. Singh S, Khichy S, Singh M, Gill JS. Recurrent solitary hydatid cyst of the subcutaneous tissue. *Indian J Surg.* 2009; **71**: 162-4.
2. Kayaalp C, Dirican A, Aydin C. Primary subcutaneous hydatid cysts: A review of 22 cases. *Int J Surg.* 2011; **9(2)**: 117-21.
3. Silva A. Human Echinococcosis: A Neglected Disease. *Gastroenterology Research and Practice* Vol 2010 (2010).
4. Dirican A, Unal B, Kayaalp C, Kirimlioglu V. Subcutaneous hydatid cysts occurring in the palm and the thigh: two case reports. *J Med Case Reports.* 2008; **2**: 273.
5. La'Porte S, Juttla J, Lingam R. Imaging the Floor of the Mouth and the Sublingual Space. *Radiographics.* 2011; **31(5)**: 1215-30.
6. Alaparathi R, Yelamanchili S, Nunsavathu P, Sode U. Intraoral hydatid cyst: A rare case report. *J Indian Acad Oral Med Radiol.* 2015; **27(3)**: 457-60.
7. Pedrosa I, Saiz A, Arrazola J, Ferreirós J, Pedrosa CS. Hydatid disease: radiologic and pathologic features and complications. *Radiographics.* 2000; **20(3)**: 795-817.
8. Malik A, Chandra R, Prasad R, Khanna G, Thukral B. Imaging appearance of atypical hydatid cysts. *Indian J Radiol Imaging.* 2016; **26(1)**: 33-9.