

INCIDENTAL FINDING OF PERSISTENT LEFT SUPERIOR VENA CAVA

Farhana MS, Husna MZ, Mubarak MY

Diagnostic Imaging Department, Serdang Hospital, Selangor, Malaysia.

PJR October - December 2016; 26(4): 343-344

ABSTRACT

A case of persistent left superior vena cava was incidentally detected during computed tomography scan of the thorax for other medical reason. This patient is not known to have any congenital anomaly. The incidence of persistent left superior vena cava is rare in general population.

Keyword: Superior vena cava, Computed Tomography, congenital anomaly.

History

18-year-old teenager sustained closed fracture of the right tibia and fibula during motor vehicle accident three days prior to the admission. He had internal fixation surgery two days later and developed shortness of breath one day after the surgery. The thoracic examination was unremarkable and chest radiograph was normal.

Computed Tomography Pulmonary Angiography (CTPA) was performed to look for pulmonary embolism. There was no filling defect in the pulmonary arteries to suggest pulmonary embolism. Both lungs have no active lesion to suggest infection. Incidentally, there was a tubular dense enhancing structure lateral to the arch of aorta. This structure was continuous with the coronary sinus and drained into the right atrium. This structure was diagnosed as left superior vena cava (Fig. 1a & 1b).

The right superior vena cava was present but not enhancing because the intravenous contrast media was given from the left antecubital vein. There was a small atretic vessel connecting the right and left superior venas (Fig. 2a, 2b & Fig. 3a, 3b).

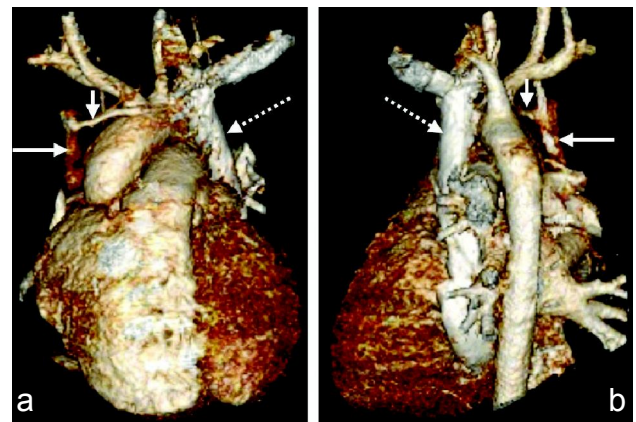


Figure 1

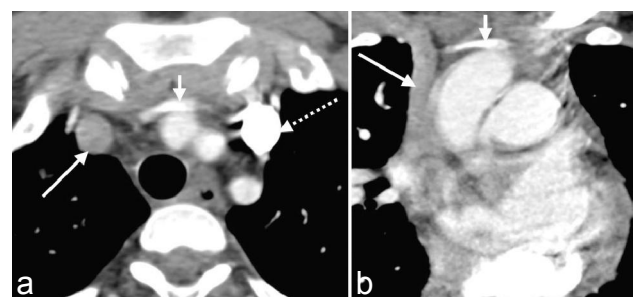


Figure 2

Correspondence : Siti Nor Farhana Mohd Shafie
Diagnostic Imaging Department,
Serdang Hospital, Puchong, Selangor, Malaysia.
Tel: +60123782472
Email: snfarhana@gmail.com

Submitted 24 April 2016, Accepted 31 May 2016

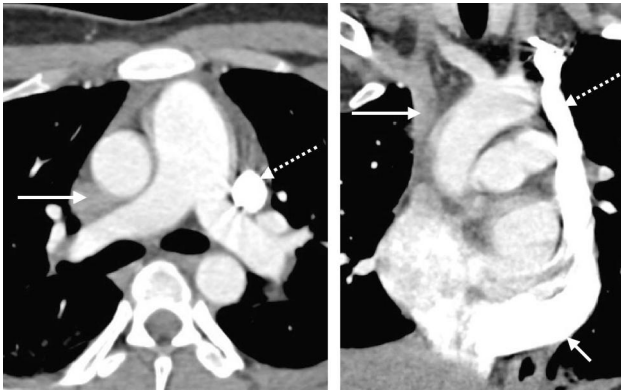

Figure 3

Discussion

Duplicated superior vena cava with persistent left superior vena cava is rare but is the most common congenital venous anomaly of the thoracic systemic venous return. The anomaly is an incidental finding and its frequency reportedly from 0.3% to 1.0% of general population.^{1,2} The incidence is higher approximately 4% to 12% in cases of congenital heart disease such as atrial and ventricular septal defects, coarctation of aorta and transposition of great vessels.²

Embryologically, the thoracic venous system has two large veins; the superior cardinal and inferior cardinal veins which return blood from the cranial and caudal aspect of embryo respectively.¹ These pairs of veins join to form the right and left common cardinal veins before entering the fetus heart.¹ During two months of gestation, there is anastomosis between the right and left superior cardinal veins to form the brachiocephalic vein. The cephalic portion of superior cardinal veins form the internal jugular veins. The caudal portion of right superior cardinal vein forms the right-sided SVC and the left superior cardinal vein regresses as "ligament of Marshall".^{1,3} A persistent left-sided SVC occurs when there is persistence of left superior cardinal vein and normally empties into the coronary sinus form by left common cardinal vein.¹

In 80% to 90%, the persistent left superior vena cava is associated with the presence of right and left superior vena cavas. Both superior vena cavas might have similar or different sizes. The left brachiocephalic

vein is completely absent in 65% of cases.³ In up to 90% the left superior vena cava drains into the right atrium via the coronary sinus.⁴ When there is left superior vena cava, the right superior vena cava is absent in 10% to 20% of cases.

As a conclusion, venous anomalies of the thorax are frequently shown on imaging studies. Most of the cases of left superior vena cava is asymptomatic.⁴ Although it may be present in up to 0.5% of the general population, persistent left superior vena cava in the absence of other congenital cardiac anomalies, is almost never diagnosed because it tends to be hemodynamically insignificant, rarely leading to symptoms.⁵

The finding is incidental either during CT scan or catheter placement of other clinical indication. More often the venous anomalies are subtle and some of the anomaly may stimulate abnormalities in the thorax.

References

1. Goyal SK, Punnam SR, Verma G, Ruberg FL. Persistent left superior vena cava: A case report and review of literature. *Cardiovasc Ultrasound*. 2008; **6**: 50.
2. Povoski SP, Khabiri H. Persistent left superior vena cava: Review of the literature, clinical implications, and relevance of alterations in thoracic central venous anatomy as pertaining to the general principles of central venous access device placement and venography in cancer patients. *World J Surg Oncol*. 2011; **9**: 173.
3. Demos TC, Posniak HV, Pierce KL, Olson MC, Muscato M. Venous anomalies of the thorax. *Am J Roentgenol*. 2004; **182(5)**: 1139-50.
4. Cooper CJ, Gerges AS, Anekwe E, Hernandez GT. Double superior vena cava on fistulogram: A case report and discussion. *Am J Case Rep*. 2013; **14**: 395-7.
5. S Bhatti, A Hakeem, U Ahmad, M Malik, P Kosolcharoen, SM Chang. Persistent left superior vena cava (PLSVC) with anomalous left hepatic vein drainage into the right atrium: role of imaging and clinical relevance. *Vascular Medicine* 2007; **12**: 319-24.