

INCIDENTAL IDENTIFICATION OF FIBRO-FATTY FALX BY COMPUTED TOMOGRAPHY IMAGING AND ITS CORRELATION WITH AGE AND GENDER

Sushil Kachewar

Department of Radiology, Rural Medical College, Pravara Institute of Medical Sciences (DU), Loni, Dt. Ahmednagar, Maharashtra, India.

PJR April - June 2018; 28(2): 115-119

ABSTRACT

OBJECTIVE: To determine the prevalence of fibro-fatty appearance of falx in subjects undergoing computed tomography (CT Scan) Imaging of brain. To correlate the prevalence with age and gender. **METHODS:** Total 290 subjects of different age groups who underwent CT scan of brain for different indications were included in this study. Data was stratified into nine groups on the basis of age and gender to observe the differences. **RESULTS:** We recruited 290 subjects (145 females, 145 males). When both genders were considered together, most subjects [67 (23.10%)] belonged to the age group of 31-40 years. This was also the commonest age group for females [32 (22.07%)] as well as for males [35 (24.14%)] when taken separately. In this study, fibro-fatty falx was seen from fourth decade onwards (31-40 years age group) and progressively increased thereafter. Females had greater prevalence [13 (8.96 %)] as compared to males [10 (6.89%)]. But this prevalence was not statistically significant for age or gender wise distribution ($p > 0.05$). **CONCLUSION:** Fibro fatty falx has a mean prevalence of 7.93 % in our population. It is more common in females and in elderly people.

Introduction

The falx cerebri is a sickle-shaped fold of meningeal layer of dura mater extending in the longitudinal fissure between the left and right human cerebral hemispheres. It has an anterior attachment at the crista galli and posterior attachment at cranial aspect of tentorium cerebelli. Cranially it is attached to internal surface of skull and encloses the superior sagittal sinus within and caudally has the inferior sagittal sinus as it curves over the corpus callosum.¹

Calcification of the falx is the commonest known benign physiological entity. In absence of any cause and often asymptomatic, the falx is known to show focal calcifications, usually in the elderly.²

Rarely neoplasm like meningioma is known to occur in falx.³ These grow with time and cause symptoms

due to pressure effects on adjacent brain parenchyma. Rarer still is a lipomatous meningioma of the falx.^{3,4}

Occurrence of fat in the falx is known as fatty falx cerebri. Embryologically the extradural neural axis lies between the two visceral layers of the falx. Fat is a content of this axis. Hence, although rare - fatty falx is possible. This condition has a reported incidence of 7.3%.⁵ It is usually asymptomatic and has a small size of few millimeters. It is seen on plain CT scan as a well defined, linear, hypo dense non enhancing lesion in the falx having C.T density values up to -30 H.U.

Some pathological conditions can have same appearance on CT scan- especially in their early phases and hence an imaging specialist must label the presence of this condition although asymptomatic at the time of reporting the CT scan.

Correspondence : Dr. Sushil Kachewar
Department of Radiology, Rural Medical College,
Pravara Institute of Medical Sciences (DU), Loni,
Dt. Ahmednagar, Maharashtra, India.
Email: sushilkachewar@hotmail.com

Submitted 6 January 2018, Accepted 23 February 2018

A ruptured intracranial dermoid can mimic a fibro-fatty falx-especially when the droplets are small in size in midline location. Multiplicity of these hypo dense (fat droplets) should alert the reporting about possibility of ruptured intracranial dermoid and not fatty falx.^{6,7}

An intracranial midline lipoma-when small can mimic fatty falx. Typical para falcine location and association of these condition with comma shaped / "C" shaped calcifications should alert the radiologist about possibility of lipoma rather than fibro-fatty falx. Corpus callosum agenesis is also known to exist with intracranial lipoma.⁸

Like calcification, falx may also undergo osseous metaplasia and when it does, the fat in medullary space of ossification can mimic fatty falx cerebri. This can be differentiated by the co-existent presence of ossifications in falx along with small hypo density of fat.^{9,10,11}

Last but not the least, presence of pneumocephalus in the falx may mimic fatty falx. But the history of trauma, density further lower than -120 H.U. and multiplicity as well as round or oval nature of lesion rather than elongated appearance indicates pneumocephalus rather than fatty falx.

It is therefore necessary to study this condition in detail so that on one hand mistakes of over reporting can be avoided and on the other pathological conditions mimicking this entity can be picked up early while they are still small.

Patients and Methods

This cross-sectional study was conducted at the department of Radiodiagnosis of this institute.

Total 290 subjects of different age groups who underwent CT scan of brain for different indications were included in this study. Patients with a history of craniofacial trauma, surgery or evidence of intracranial mass-occupying lesion were excluded from this study. Sampling duration was six months. Data was stratified into nine groups on the basis of age and gender to observe the differences.

Head was scanned on 16 Slice GE multidetector computerized scanning machine. All images were taken at 5 mm slice thickness and at 5 mm interval. The images were viewed on brain window image

setting of window width 80 H.U. and window Level 40 H.U.

Normal falx is seen as a 1-2 mm thin uniformly iso-hyper dense linear midline structure running in between the cerebral hemispheres. Fatty falx is seen as a thin linear hypo dense having C.T. density of -20 to -120 H.U. located within the iso-hyper dense falx. (Fig. 1, 2 and 3).

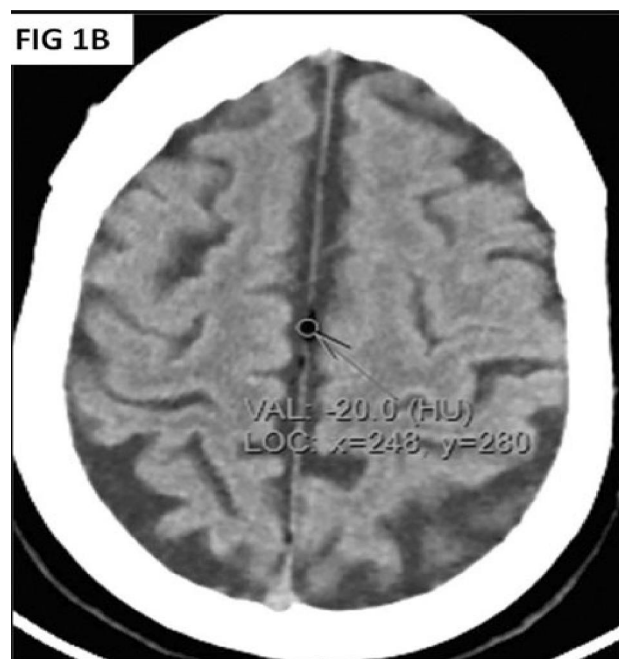
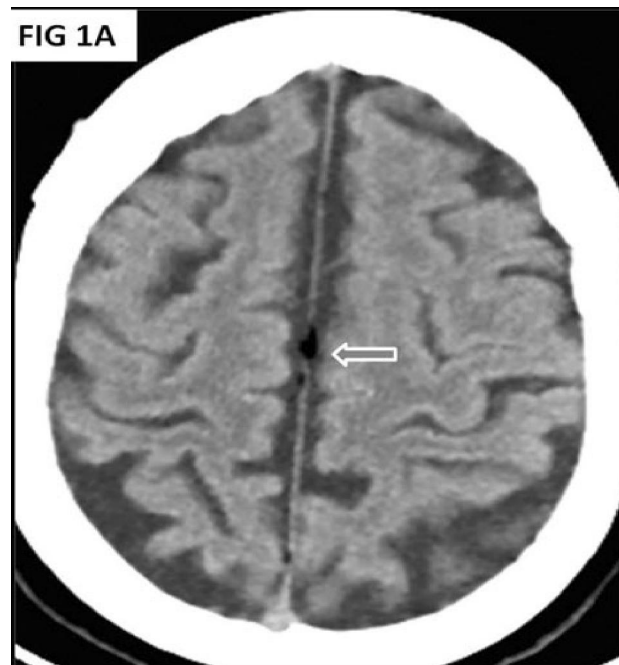


Figure 1A and 1B: NECT brain showing hypo dense fatty falx in midline having a CT density of -20 H.U.

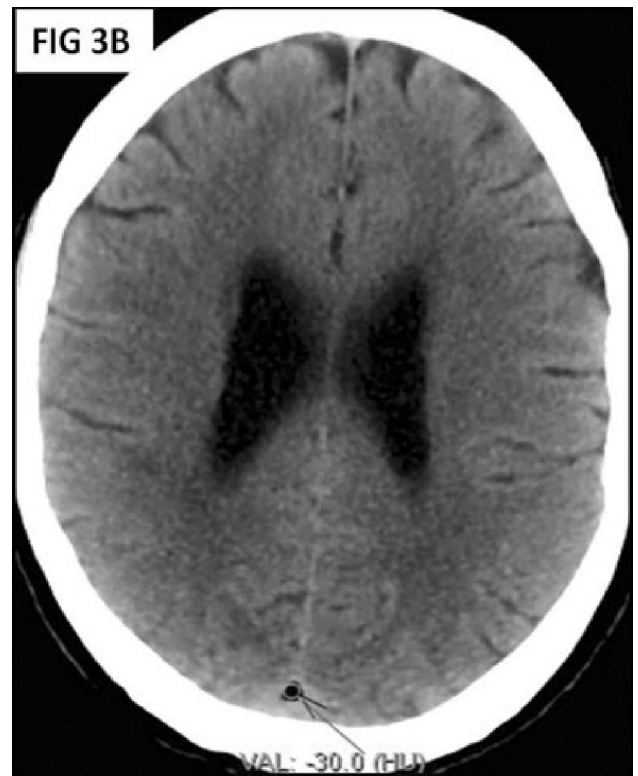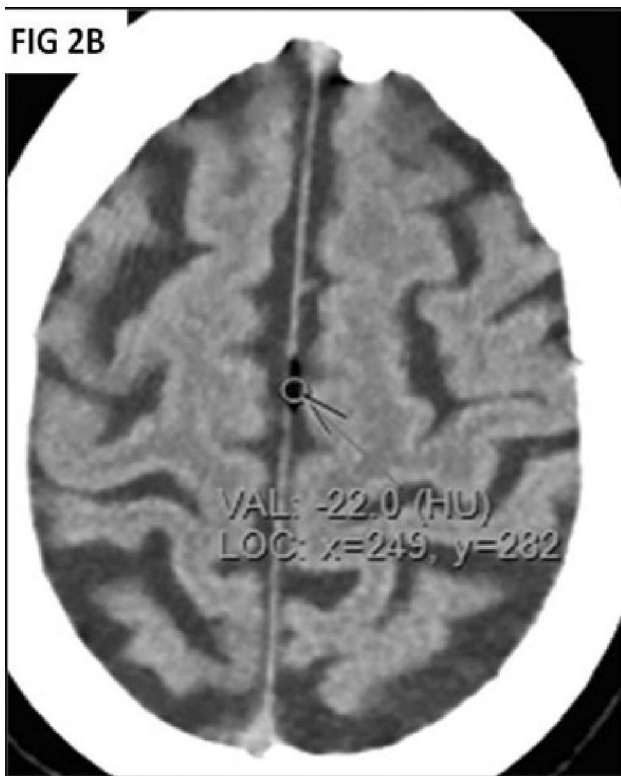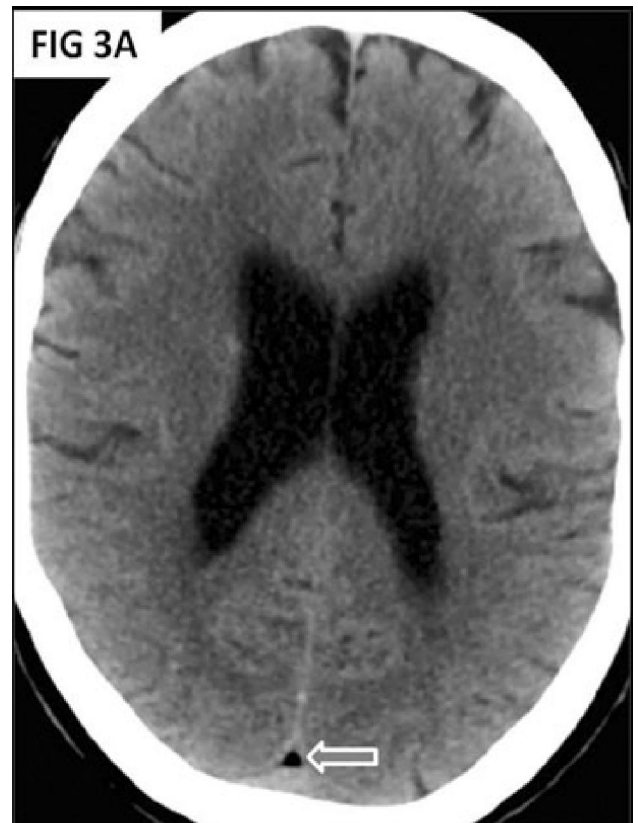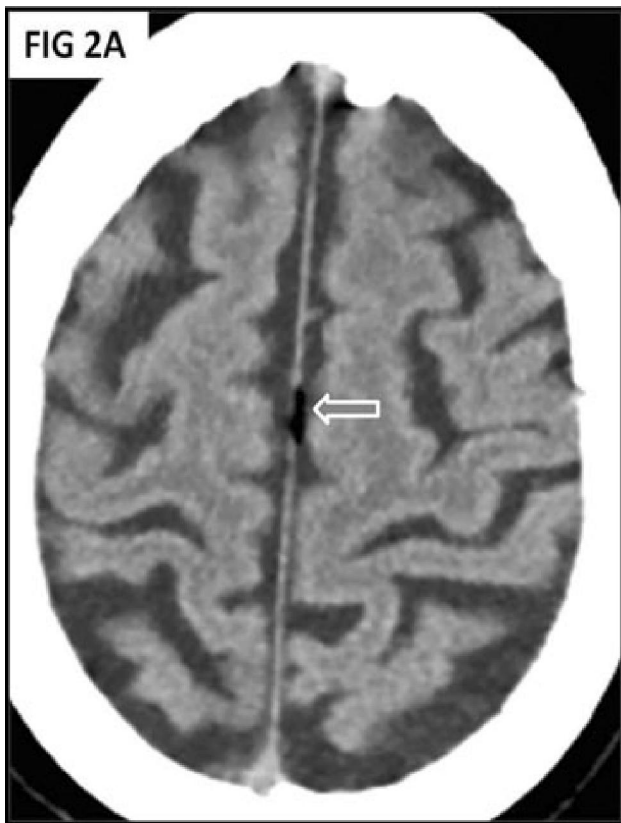


Figure 2A and 2B: NECT brain showing hypo dense fatty falx in midline having a CT density of -22 H.U.

Figure 3A and 3B: NECT brain showing hypo dense fatty falx in midline having a CT density of -30 H.U.

Statistical analysis

It was done by using SPSS software version 20. The patients were stratified on the bases of age and gender. Quantitative data was expressed as means and standard deviation and illustrated using tables. The relationship between prevalence of fatty falx with age quartiles and gender was evaluated using the Student's t-test. P-value less than 0.05 was considered to indicate a statistically significant difference.

Results

We recruited 290 subjects (145 females, 145 males). (Tab. 1) shows the age and gender wise distribution of all patients. When both genders were considered together, most subjects [67 (23.10%)] belonged to the age group of 31-40 years. This was also the commonest age group for females [32 (22.07%)] as well as for males [35 (24.14%)] when taken separately.

Age Quartiles (Years)	Females N (%)	Males N (%)	Total N (%)
10-20	18 (12.41)	12 (08.27)	30 (10.34)
21-30	16 (11.03)	15 (10.34)	31 (10.69)
31-40	32 (22.07)	35 (24.14)	67 (23.10)
41-50	25 (17.24)	24 (16.55)	49 (16.89)
51-60	26 (17.93)	27 (18.62)	53 (18.27)
61-70	28 (19.31)	32 (22.07)	60 (20.69)
Total	145	145	290

Table 1: Age and Gender wise distribution of all patients

(Tab. 2) shows the age and gender wise distribution of patients in whom the CT scan of brain showed fibro-fatty falx. In this study, fibro-fatty falx was seen from fourth decade onwards (31-40 years age group) and progressively increased thereafter. Females had greater prevalence [13 (8.96%)] as compared to males [10 (6.89%)]. But this prevalence was not statistically significant for age or gender wise distribution ($p > 0.05$).

Discussion

Presence of fat in the falx cerebri is a common incidental finding in the CT scans images of brain of patients. But this finding has not been well charac-

Age Quartiles (Years)	Females N	Males N	Total N	p value
10-20	00	00	00	-----
21-30	00	00	00	-----
31-40	02	01	03	$p > 0.05$
41-50	03	02	05	$p > 0.05$
51-60	03	04	07	$p > 0.05$
61-70	05	03	08	$p > 0.05$
Total	13 (8.96%)	10 (6.89%)	23 (7.93%)	$p > 0.05$

*p significant if <0.05

Table 2: Age and Gender wise distribution of patients with fatty falx

terized, researched or reported. Hence, this study was undertaken to determine the prevalence of fatty falx in routine CT brain studies.

To our knowledge, the last and the latest report of this entity was by Chen SS, Shao KN, Chiang JH, Chang CY, Lao CB, Lirng JF and Teng MM, that was published in 2000.⁵ They evaluated 1,570 cases and found 115 of them had small fatty falx which was confirmed by the negative Hounsfield value on CT scan. No calcified component was noted within. They found this most commonly in aged patients. The entity was found to be asymptomatic. In their study fatty falx had an incidence of 7.3%. they opined it to be an incidental finding in adults that required no further evaluation or treatment.

The findings in our study are in concordance with their findings. In our study of 290 subjects (145 females, 145 males, fibro-fatty falx was seen from fourth decade onwards (31-40 years age group) and progressively increased thereafter. Females had greater prevalence [13 (8.96 %)] as compared to males [10 (6.89%)]. But this prevalence was not statistically significant for age or gender wise distribution ($p > 0.05$). Fibro fatty falx had a mean prevalence of 7.93 % in our study. It was more common in females and in elderly people.

Limitations

Our study is limited by its small sample size and due to the fact that it was mono centric. Larger and multi centric studies are therefore suggested. Furthermore, it has been observed that fatty falx is sometimes the only finding in patients with headache. Correlation studies for possible explanation of general non specific headache or any specific type of headache and fatty falx would be worth considering.

Conclusion

Fibro fatty falx had a mean prevalence of 7.93 % in our study. As per our findings it is more common in females and in elderly people. Our study points to gender and age related variation in the finding of fatty falx on CT scans of brain of patients.

References

1. Saladin K. "Anatomy & Physiology: The Unity of Form and Function." New York: McGraw Hill, 2014. pp 512, 770-3.
2. Daghighi MH, Rezaei V, Zarrintan S, Pourfathi H. Intracranial physiological calcifications in adults on computed tomography in Tabriz, Iran. *Folia Morphol (Warsz)*. 2007; **66(2)**: 115-9.
3. Molina Fábrega R, Martínez Martínez JC, La Parra Casado C, Montoliu Fornás G. Lipomatous meningioma: An atypical presentation of meningioma. *Radiologia* 2008; **50**: 345-6.
4. Chung SB, Kim CY, Park CK, Kim DG, Jung HW. Falx Meningiomas: Surgical Results and Lessons Learned from 68 Cases. *J Korean Neurosurg Soc*. 2007; **42(4)**: 276-80.
5. Chen SS, Shao KN, Chiang JH, Chang CY, Lao CB, Lirng JF, Teng MM. Fat in the cerebral falx. 2000; **63(11)**: 804-8.
6. McArdle DJ, Karia SJ. Ruptured intracranial dermoid cyst. *Pract Neurol*. 2016; **16(6)**: 478-9.
7. Heger D, Scheer F, Andresen R. Ruptured, Intracranial Dermoid Cyst - A Visual Diagnosis? *J Clin Diagn Res*. 2016; **10(4)**: TD08-09.
8. Ichikawa T, Kumazaki T, Mizumura S et-al. Intracranial lipomas: demonstration by computed tomography and magnetic resonance imaging. *J Nippon Med Sch*. 2000; **67(5)**: 388-91.
9. Sands SF, Farmer P, Alvarez O, Keller IA, Gorey MT, Hyman RA. Fat within the falx: MR demonstration of falcine bony metaplasia with marrow formation. *J Comput Assist Tomogr*. 1987; **11(4)**: 602-5.
10. Al-Motabagani M, Haroun H, Meguid EA. Calcification and ossification of the convexity of the falx cerebri and related subdural space in human cadavers. *Neurosciences (Riyadh)*. 2004, **9(4)**: 261-4.
11. Debnath J, Satija L, George RA. Computed tomographic demonstration of unusual ossification of the falx cerebri: a case report. *Surg Radiol Anat*. 2009; **31(3)**: 211-3.