

BILATERAL BICONDYLAR OSTEOCHONDRITIS DISSECANS OF KNEE: A CASE REPORT

Temel Fatih Yilmaz,¹ Muhammet Salih Ayas,² Ahmet Ugur Turhan²

¹Department of Radiology, Bezmialem Vakif University, Turkey.

²Department of Orthopedics and Traumatology, Karadeniz Technical University, Turkey.

PJR April - June 2018; 28(2): 150-153

ABSTRACT

Osteochondritis dissecans is the disruption of bone tissue connection of the part containing the subchondral bone with cartilage. The early diagnostic schedule when an OCD lesion is supposed begins with an X-ray. MRI has high sensitivity for the detection of invisible lesions on the radiograph. This case of bilateral bicondylar osteochondritis dissecans of knee is a unique clinical presentation of OCD and has never been described previously.

Keywords: Osteochondritis dissecans, Knee, Bicondylar

Introduction

Osteochondritis dissecans is the disruption of bone tissue connection of the part containing the subchondral bone with cartilage. It is more common in young patients and in sports. It causes early degenerative osteoarthritis in joints with load bearing.¹ It is usually unilateral and about 75% of cases occur in the knee joint. 85% of the lesions are seen in the medial femoral condyle, especially at lateral aspect of medial femoral condyle.² 15-30% are bilateral.³ The diagnosis of the patients is made by conventional radiography, but the stability of the defect in the articular cartilage and the size of the affected area cannot be determined by radiography or clinical examination. Magnetic Resonance Imaging (MRI) should be performed to evaluate joint cartilage and staging in osteochondritis dissecans patients.¹ Previously, bicondylar osteochondritis dissecans were described in a single knee,⁴ but no bicondylar and bifemoral osteochondritis dissecans (OCD) were identified.

Case Report

A 22-year-old male patient was admitted to the orthopedics clinic with pain in both knees. The pain was usually during the onset of mobilization and then decreased. The joint movements were within normal limits. Neurovascular examination was natural. There was no obvious swelling and ballot on the knee. In the backward questionnaire, it was learned that knee aches started when playing football 4 years ago. Medical treatment was applied by the orthopedic physicians followed by the diagnosis of intratendinous rupture of anterior cruciate ligament in MRI performed at that time. There was no known illness and no medication that he used long time. On admission to our clinic cartilage lesion at femur condyles in both knee was determined at radiography [(Fig. 1) x-ray tunnel radiograph]. Bicondylar and bifemoral osteochondritis dissecans were diagnosed on the MRI (Fig. 2).

Correspondence : Dr. Temel Fatih Yilmaz
Department of Radiology,
Bezmialem Vakif University,
Turkey.
Email: temelfatihyilmaz@gmail.com

Submitted 24 December 2017, Accepted 31 January 2018

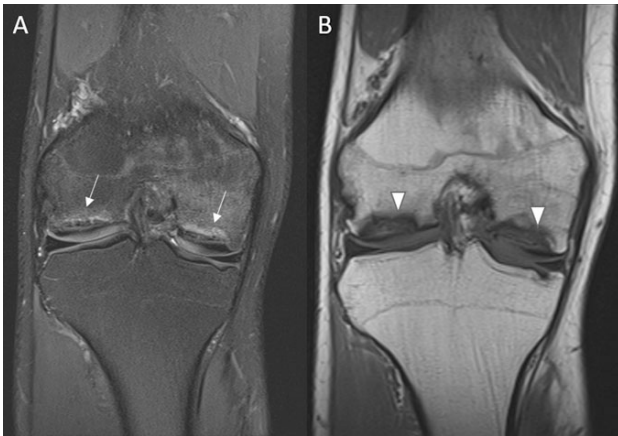

Figure 1: 22-year-old male patient was admitted to the orthopedics clinic with pain in both knees. Coronal Fat saturated proton density (PD) (A) and Coronal T1 weighted (B) images of right knee demonstrates bilateral and bicondylar hyperintense areas at PD images (arrows) with hypointense rim in T1 weighted images (arrowheads) at lateral and medial femoral condyle that compatible with osteochondritis dissecans. There is no loose body and surrounding fluid intensity that indicates stability.

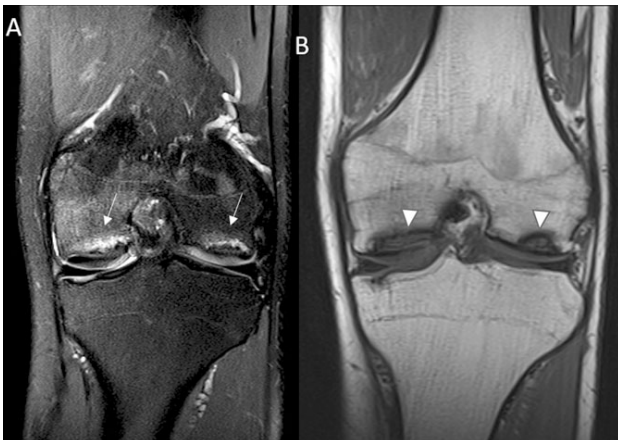


Figure 2: 22-year-old male patient was admitted to the orthopedics clinic with pain in both knees. Coronal fat saturated proton density (PD) (A) and Coronal T1 weighted (B) images of left knee demonstrates bilateral and bicondylar hyperintense areas at PD images (arrows) with hypointense rim in T1 (arrowheads) weighted images at lateral and medial femoral condyle that compatible with osteochondritis dissecans. There is no loose body and surrounding fluid intensity that indicates stability.

Discussion

Although osteochondritis dissecans are rare, they attract attention of orthopedic surgeons and have been studied extensively in literature. The term osteochondritis dissecans was first described by Franz König in 1887 at the knee, elbow and ankle as a cartilage defect in young adults. Since then, various

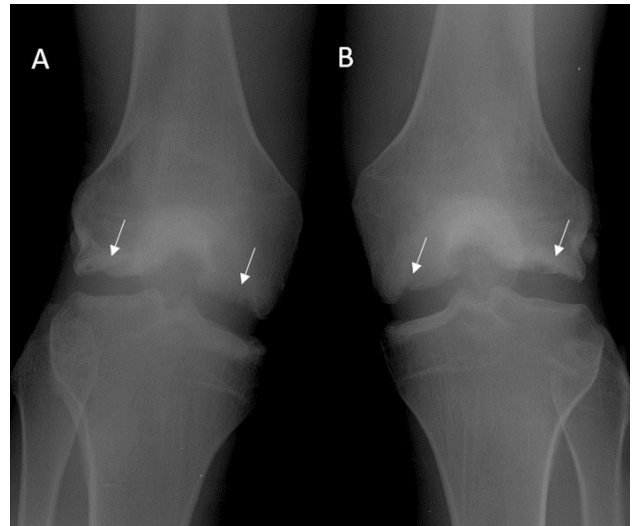


Figure 3: 22-year-old male patient was admitted to the orthopedics clinic with pain in both knees. Anteroposterior radiographs of right (A) and left (B) knee which were performed to the patient as first imaging modality show lucency and irregularity (arrows) at lateral and medial femoral condyles bilaterally.

theories about etiology have been put forward. Trauma, ischemia, ossificance defects and genetic reasons have been suggested. None of these proposed theories can explain precisely.⁴ The early diagnostic schedule when an OCD lesion is supposed begins with an X-ray in 2 orthogonal planes. The standard series contain a standing anterior-posterior (AP) view, a lateral view with the knee flexed 35°, and a 45° patella sunrise view. Extra special X-ray views could be valuable such as a tunnel view taking the area with the lesion more in line with the imaging plane up.⁵


MRI has high sensitivity for the detection of invisible lesions on the radiograph.⁴ MRI is needed to assess the stability and size of the lesion in patients scheduled for surgery. It is mostly seen in the medial femoral condyle but other localizations are talus, capitellum, patella, femur head, distal tibia, and wrist.⁶ It is rarely reported in the lateral femoral condyle.⁷⁻¹⁰ In literature, there are reports of osteochondritis dissecans at bicondylar of single knee of two patients,⁴ bilateral lateral condylar in one patient,⁷ medial femoral condylar and patellar of the same knee in one patient,² lateral condylar and at patellofemoral joint in the same knee of one patient,¹⁰ bilateral lateral trochlear in one patient¹¹ and at 3 regions including bicondylar and patellar in a patient.¹⁰

In the literature there are various treatment methods. These; autogenous chondrocyte implantation, fixation with Herbert screw, bio absorbable screw, autologous tendon grafting, mosaicplasty, K wire fixation, and arthroscopic debridement.¹²⁻²⁰

This case of bilateral bicondylar osteochondritis dissecans of knee is a unique clinical presentation of OCD and has never been described previously.

References

1. Singh S, Chowdhury V, Dixit R, Khera G. Images-osteochondritid dissecans of knee. *Indian J Radiol Imaging* 2005; **15**: 463-6
2. Kaya A, Guclu B, Karagüven D, Ataoglu O. Osteochondritis dissecans occurring in the patella and medial femoral condyle in the same knee. *acta orthopaedica et traumatologica turcica* 2009; **43(1)**: 72-6
3. Hefti F, Beguiristain J, Krauspe R, Möller-Madsen B, Riccio V, Tschauner C, et al. Osteochondritis dissecans: a multicenter study of the European Pediatric Orthopedic Society. *J Pediatr Orthop* 1999; **8**: 231-45.
4. Hanna S. A, Aston W. J. S, Gikas P. D, Briggs T. W. R. Bicondylar osteochondritis dissecans in the knee. *Bone & Joint Journal* 2008; **90(2)**: 232-5.
5. Bruns J, Werner M, Habermann C. Osteochondritis Dissecans: Etiology, Pathology, and Imaging with a Special Focus on the Knee Joint. *Cartilage*. 2017 Jun 1: 1947603517715736
6. Schenck RC Jr, Goodnight JM. Osteochondritis dissecans. *J Bone Joint Surg Am* Mar 1996; **78(3)**: 439-56.
7. Fischer M, Koller U, Krismer M. Die Verwendung von frischen Allografts bei der Osteochondrosis dissecans am lateralen Femurkondylus. *Operative Orthopädie und Traumatologie* 2006; **18(3)**: 245-58.
8. Deie M, Ochi M, Sumen Y, Kawasaki K, Adachi N, Yasunaga Y, Ishida O. Relationship between osteochondritis dissecans of the lateral femoral condyle and lateral menisci types. *Journal of Pediatric Orthopaedics* 2006; **26(1)**: 79-82.
9. Cetik O, Turker M, Uslu M. Bilateral osteochondritis dissecans of lateral femoral condyle. *Knee Surgery, Sports Traumatology, Arthroscopy* 2005; **13(6)**: 468-471.
10. Grimm N. L, Tisano B, Carey J. L. Three osteochondritis dissecans lesions in one knee: a case report. *Clinical Orthopaedics and Related Research* 2013; **471(4)**: 1186-90.
11. Maruyama Y, Kaneko K, Baba T. A case of osteochondritis dissecans of the lateral femoral condyle and patellofemoral joint surface occurring in the same knee. *European orthopaedics and traumatology* 2014; **5(2)**: 171.
12. Takahashi Y, Nawata K, Hashiguchi H, Kawaguchi K, Yamasaki D, Tanaka H. Bilateral osteochondritis dissecans of the lateral trochlea of the femur: a case report. *Archives of orthopaedic and trauma surgery* 2008; **128(5)**: 469-72.
13. Cook J. L, Gomoll A. H, Farr J. Commentary on "Third-generation autologous chondrocyte implantation versus mosaicplasty for knee cartilage injury: 2-year randomized trial". *Journal of Orthopaedic Research* 2016; **34(4)**: 557-8.
14. Murray J. R. D, Chitnavis J, Dixon P, Hogan N. A, Parker G, Parish E. N, Cross M. J. Osteochondritis dissecans of the knee; long-term clinical outcome following arthroscopic debridement. *The Knee* 2007; **14(2)**: 94-8.
15. Edmonds E. W, Polousky J. A review of knowledge in osteochondritis dissecans: 123 years of minimal evolution from König to the ROCK study group. *Clinical Orthopaedics and Related Research* 2013; **471(4)**: 1118-26.
16. Bentley G, Biant L. C, Vijayan S, Macmull S, Skinner J. A, Carrington R. W. J. Minimum ten-year results of a prospective randomised study of autologous chondrocyte implantation versus mosa-

-
- 
- icplasty for symptomatic articular cartilage lesions of the knee. *J Bone Joint Surg Br* 2012; **94(4)**: 504-9.
17. Barrett I, King A. H, Riester S, van Wijnen A, Levy B. A, Stuart M. J, Krych, A. J. Internal Fixation of Unstable Osteochondritis Dissecans in the Skeletally Mature Knee with Metal Screws. *Cartilage* 2016; **7(2)**: 157-162.
18. Abouassaly M, Peterson D, Salci L, Farrokhyar F, D'Souza J, Bhandari M, Ayeni O. R. Surgical management of osteochondritis dissecans of the knee in the paediatric population: a systematic review addressing surgical techniques. *Knee Surgery, Sports Traumatology, Arthroscopy* 2014; **22(6)**: 1216-1224.
19. Aydin H, Karahasanoglu I, Kerimoglu S, Turhan A. U. Treatment of capitellar osteochondritis dissecans with a tendon graft: a case report. *Eklem hastaliklari ve cerrahisi = Joint diseases & related surgery* 2012; **23(1)**: 55.
20. Turhan A. U, Aynaci, O, Turgutalp H, Aydin H. Treatment of osteochondral defects with tendon autografts in a dog knee model. *Knee Surgery, Sports Traumatology, Arthroscopy* 1999; **7(2)**: 64-8.