

FREQUENCY OF DIFFERENT ULTRASONOGRAPHIC PATTERNS IN PATIENTS PRESENTING WITH ACUTE SCROTUM

Murli Manohar, Amjad Sattar, Sohail Ahmed Khan, Hatem Adel

Dow Institute of Radiology, Dow University of Health Sciences (DUHS), Karachi, Pakistan

PJR April - June 2018; 28(2): 124-127

ABSTRACT

BACKGROUND: Acute scrotum is sudden onset of swelling and pain in the scrotum or its contents, accompanied by local signs or general symptoms and is commonly due to testicular torsion, epididymitis, orchitis or epididymo-orchitis. The difficulty arises due to the similarities between the presentations. It is important to recognize sonographic patterns of acute scrotum to reduce the need of exploratory surgery. **OBJECTIVE:** To determine the frequency of different ultrasonographic patterns in patients presenting with acute scrotum. **METHODS:** A cross-sectional study was conducted at Dow Institute of Radiology, Dow University of Health Sciences from 20th April 2016 till 20th October 2016. Male patients aged 16-45 years presenting with acute scrotum within 24 hours underwent scrotal ultrasound with color doppler imaging. Comparative axial and sagittal views of each scrotum were obtained. Images were interpreted by two radiologists in terms of echotexture, echogenicity, size of testes, hydrocele and blood flow of testes and epididymis by color doppler study. **RESULTS:** Mean age of the patients was 31.82 ±10.86 years. There were majority 89 (37.7%) of the patients with ≤30 years of age. Heterogeneous echo texture of testes was found in 127 (53.8%), epididymal enlargement in 205 (39.4%), hydrocele 166 (70.3%), increased degree of blood flow in testes 172 (72.9%) and increased degree of blood flow in epididymis was observed in 173 (73.3%) patients. **CONCLUSION:** Heterogeneous echotexture of the testes, presence of epididymal enlargement, hydrocele, increased blood flow within the testes and epididymis were frequently observed sonographic patterns in patients with acute scrotum.

Keywords: Acute scrotum, Sonographic patterns, Frequency, Hydrocele

Introduction

“Acute scrotum”, a pain of sudden onset in scrotum, may have local examination findings or general unwell symptoms.¹ Following diagnosis it can be treated appropriately. Testicular torsion, epididymitis, orchitis or epididymo-orchitis form a good chunk of acute scrotum cases. Similarities between the presentations cause difficult interpretation.^{2,3}

Testicular torsion, an emergency, requires prompt intervention by surgical team. The degree of torsion and infarction length i.e. (approx. less than 6 hours) are key factors in recovery of tormented testes.^{2,4} Ultra-

sound is valuable here to identify normal blood flow to the testis.^{4,6} Epididymitis and epididymo-orchitis have difficult differentiation from torsion, on basic physical examination. It is important to accurately diagnose them, as their management is nonsurgical. Ultrasound in epididymitis shows swollen epididymal head, body or tail with raised vascular flow. Testicular flow may be normal or raised. Advanced epididymo-orchitis, same as torsion, can cause ischemic changes in testes. Therefore, any case of ischemic testes requires surgical exploration. When diagnosed, epididymitis and orchitis or epididymo-orchitis are managed conservatively with medical management.

Correspondence : Dr. Murli Manohar
Dow Institute of Radiology,
Dow University of Health Sciences (DUHS),
Karachi, Pakistan
Email: mmdkhatri@gmail.com

Submitted 16 December 2017, Accepted 8 January 2018

Complication such as abscess may require surgical drainage and/or orchiectomy.^{7,8}

Surgeons tend to misclassify an ischemic from an inflamed testis on the basis of physical examination. Therefore past operative explorations in uncertain cases have led to a high surgery rate. Recently, ultrasonography with Doppler mode has become a valuable tool for acute scrotum evaluation. It is helpful in detecting ischemia, thus reducing the need for explorative surgery and patient morbidity.

Materials and Methods

This cross-sectional study was conducted at Dow Institute of Radiology, Dow University of Health Sciences, Ojha campus, Karachi from 20th April 2016 till 20th October 2016.

All male patients age between 16 and 45 years presented with acute scrotum within 24 hours were enrolled while, patients suffering trauma to testes, any prior surgical history/intervention to scrotum were excluded. Sample size was calculated through Epi Info sample size calculator with 33%⁹ prevalence, 95% CI % and 6% d, then the estimated sample size came out to be 236 patients.

After taking the signed informed consent, radiologists performed the scrotal ultrasound examination using the GE Voluson S6 or S8 machine with a high frequency linear probe. Doppler study was also utilized during examination. In a private room, after explaining the procedure, the examinations were performed while the patient lying supine. Initially, axial sections of testes were imaged, followed by axial and sagittal sections of each testis. Inguinal regions were also explored. The sonographic examinations were aimed at identifying and localizing the testicular pathology

or any pathology in the epididymides or extra-testicular soft tissues. The lesions were characterized in terms of parenchymal echotexture, parenchymal echogenicity and outline, the size, site and extent of the lesion, the perfusion (vascularity) of the epididymis, testis, and the pathology by color Doppler ultrasound examination. Images were saved in hard and soft copies.

Two radiologists, with more than five year experience in male imaging, interpreted the images. The abnormalities identified were noted. A diagnosis was made on the basis of characteristic ultrasound appearances of that ailment.

Results

Mean age of the patients was 31.82 ±10.86 years (minimum 16 years maximum 45 years). There were majority 89 (37.7%) of the patients with ≤30 years of age. Mean duration of symptoms was 9.35 ±6.72 hours (minimum 1 hours; maximum 24 hours). There were majority 160 (67.8%) patients with ≤10 hours of duration of symptoms.

Heterogenous echotexture of testes was found in 127 (53.8%), epididymal enlargement in 205 (86.9%), hydrocele 166 (70.3%), increased degree of blood flow in testes 172 (72.9%) and increased degree of blood flow in epididymis was observed in 173 (73.3%) patients.

Comparison was done to see the effect of age and gender on the outcome. Chi-square test was applied. Significant difference of age and epididymal enlargement (p-value <0.001), age and Degree of blood flow in testes (p-value 0.003), age and Blood flow Epididymis (p-value <0.001) was observed.

	Echotexture of Testes			Epididymal Enlargement		Degree of blood flow in testes			Blood flow Epididymis		
	Heterogenous	Hypoechoic	Normal	Absent	Present	Absent	Increased	Normal	Absent	Increased	Normal
	n=127	n=93	n=16	n=205	n=31	n=48	n=172	n=16	n=32	n=173	n=31
Age (years)	32.55 ± 10.64	29.95 ± 10.97	36.87 ± 10.32	33.17 ± 10.59	22.90 ± 8.21	28.64 ± 11.51	32.23 ± 10.51	36.93 ± 10.67	32.23 ± 11.75	33.32 ± 10.39	22.90 ± 8.21
	p-value 0.033 [†]			p-value <0.001 [‡]		p-value 0.019 [†]			p-value <0.001 [†]		
Duration of symptoms (hours)	9.27 ± 6.87	9.30 ± 6.80	10.31 ± 5.16	9.46 ± 6.74	8.61 ± 6.69	9.47 ± 7.16	9.35 ± 6.64	9.01 ± 6.65	9.84 ± 7.43	9.39 ± 6.63	8.61 ± 6.69
	p-value 0.842 [†]			p-value 0.511 [‡]		p-value 0.970 [†]			p-value 0.760 [†]		

All data presented as mean ± standard deviation, [†]One-way ANOVA applied, [‡]Independent t-test applied, p-value <0.05 was taken as significant

Table 1: Comparison of ultrasonographic patterns with age and duration of the symptoms (n=236)

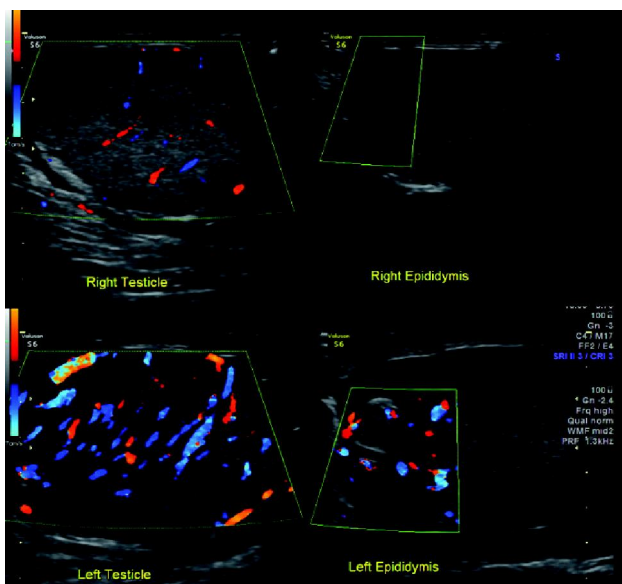


Figure 1: Ultrasound scrotum of a 31-year-old male presenting with scrotal pain for duration of 8 hours. It is showing swollen and hypoechoic left testis and epididymis with increased vascular flow on color doppler scan. He was diagnosed as having acute epididymoorchitis.

Discussion

This study determined the frequency of different patterns in patients presenting with acute scrotal pain. In our study echotexture of testes was heterogeneous in majority of the patients followed by hypoechoic texture. Another study done internationally support this finding.¹⁰ No hyperechoic texture was seen in any of the patient. This can be due to the fact that acute scrotal pain leads to testicular edema and enlargement of testes leading to reduction in testicular echogenicity or heterogeneous appearance.

Our study showed that enlargement of the epididymis occurred in majority of the patients. This has also been shown in previous study.¹⁰ Inflammation of epididymis is a common feature of acute scrotal pathologies such as epididymoorchitis or torsion. Epididymis is edematous leading to its swelling. This can be a reason attributed to this condition in our study.

Our study demonstrated that hydrocele was frequently found in patients presenting with acute scrotal pain. A previous study also reported that hydrocele is frequently found in patients with acute scrotum patients diagnosed as having testicular torsion or epididymoorchitis.¹⁰ Hydrocele is the fluid collection within the tunica vaginalis of the scrotum or along the sper-

matic cord. It typically presents as a soft, nontender and fluctuant swelling of the scrotum.

Current study showed that increase in blood flow within the testes is a frequent finding observed in patients with acute scrotal pain. This was also shown in previous study.¹⁰ Color doppler ultrasonography is currently the most important imaging modality available for the diagnosis of different scrotal pathologies. It allows accurate evaluation of scrotal conditions as well as vascular anatomy is well appreciated. Approximately twenty percent of the patients had no blood flow within the testes. These patients were diagnosed as having testicular torsion. Color doppler ultrasound reliably differentiates testicular torsion from acute epididymoorchitis based on the absence of blood flow in torsion to increased testicular blood flow in epididymoorchitis. It has a high sensitivity and specificity in diagnosis of testicular torsion.¹¹ Doppler ultrasound of scrotum significantly increases the predictivity of the diagnosis.^{12,13}

Our study also showed that majority of the patients with acute scrotal pain has increased blood flow in epididymis as well. This finding has also been supported by other study.¹⁰ This can be attributed to the fact that inflammation causes increase blood flow leading to increase in doppler vascularity of epididymis as well as testes. In cases of torsion more than ten percent had absent vascularity in epididymis also.

Few limitations need consideration. Only patients of acute scrotal pain were included in our study. Scrotal swelling is also a major cause of presentation to routine outpatient clinics and may have different other patterns on sonography. Also clinical presentations of the patient were not taken into account. A study utilized different clinical spectrums of acute scrotum.¹² Lower abdominal pain in children should also include differential of acute scrotum according to a study.¹⁴

In most of the cases of scrotal pathologies, adequate clinical history, physical examination findings and findings of ultrasonography are sufficient for correct diagnosis to be made.^{15,16} Furthermore, it is recommended that studies on sonographic patterns of non-painful scrotal conditions that mimic acute painful scrotal conditions should be carried out to differentiate them from acute causes of scrotal pain. Moreover, a study with correlation of sonographic findings with clinical presentation could further improve the understanding in this field.

Conclusion

Heterogeneous echotexture of the testes, presence of epididymal enlargement, hydrocele, increased blood flow within the testes and epididymis were frequently observed sonographic patterns in patients presenting with acute scrotal pain. Recognition of these patterns is important in diagnosing different clinical conditions for their prompt management.

DISCLOSURE

It is a dissertation based article.

References

1. Davis JE, Silverman M. Scrotal emergencies. *Emerg Med Clin North Am.* 2011; **29**: 469-84.
2. Boettcher M, Bergholz R, Krebs TF, Wenke K, Aronson DC. Clinical predictors of testicular torsion in children. *Urology.* 2012; **79**: 670-4.
3. Beni-Israel T, Goldman M, Bar Chaim S, Kozer E. Clinical predictors for testicular torsion as seen in the pediatric ED. *Am J Emerg Med.* 2010; **28**: 786-9.
4. Mellick LB. Torsion of the testicle: it is time to stop tossing the dice. *PediatrEmerg Care.* 2012; **28**: 80-6.
5. Lopez RN, Beasley SW. Testicular torsion: potential pitfalls in its diagnosis and management. *J Paediatr Child Health.* 2012; **48**: E30-2.
6. Kapoor S. Testicular torsion: a race against time. *Int J ClinPract* 2008; **62**: 821-7.
7. Tracy, C.R., Steers, W.D., Costabile, R. Diagnosis and management of epididymitis. *Urol Clin N Am.* 2008; **35**: 101-8.
8. Opio J, Byanyima RK, Kiguli-Malwadde E, Kaggwa S, Kawooya M. The sonographic pattern of diseases presenting with scrotal pain at Mulago Hospital, Kampala, Uganda. *East and Central African Journal of Surgery* 2008; **13**: 68-74.
9. Kaye JD, Shapiro EY, Levitt SB, Friedman SC, Gitlin J, Freyle J, et al. Parenchymal echo texture predicts testicular salvage after torsion: potential impact on the need for emergent exploration. *J Urol.* 2008; **180**: 1733-6.
10. Becker D, Burst M, Wehler M, Tauschek D, Herold C, Hahn EG. [Differential diagnosis of acute testicular pain using color-coded duplex ultrasonography: difference between testicular torsion and epididymitis]. *Dtsch Med Wochenschr.* 1997; **122**: 1405-9.
11. Becker D, Burst M, Wehler M, Tauschek D, Herold C, Hahn EG. [Differential diagnosis of acute testicular pain using color-coded duplex ultrasonography: difference between testicular torsion and epididymitis]. *Dtsch Med Wochenschr.* 1997; **122**: 1405-9.
12. Lemini R, Guanà R, Tommasoni N, Mussa A, Di Rosa G, Schleef J. Predictivity of Clinical Findings and Doppler Ultrasound in Pediatric Acute Scrotum. *Urology Journal.* 2016; **13**: 2779-83.
13. Mohammed WM, Davis NF, O'Connor KM, Kiely EA. Re-evaluating the role of Doppler ultrasonography in patients presenting with scrotal pain. *Irish Journal of Medical Science (1971-).* 2016; **185**: 705-9.
14. Pogorelic Z, Mrklic I, Juric I. Do not forget to include testicular torsion in differential diagnosis of lower acute abdominal pain in young males. *Journal of pediatric urology.* 2013; **9**: 1161-5.
15. Kühn AL, Scortegagna E, Nowitzki KM, Kim YH. Ultrasonography of the scrotum in adults. *Ultrasonography.* 2016; **35**: 180.
16. Liang T, Metcalfe P, Sevcik W, Noga M. Retrospective review of diagnosis and treatment in children presenting to the pediatric department with acute scrotum. *American Journal of Roentgenology.* 2013; **200**: W444-459.