

TRIGEMINAL NEURALGIA SECONDARY TO VERTEBROBASILAR DOLICHOECTASIA IN AN OLD MALE AND ITS MANAGEMENT BY MICROVASCULAR DECOMPRESSION

Amna Alvi,¹ Asma Alvi,² Salma Azam¹

¹ Department of Radiology, The Aga Khan University Hospital (AKUH), Karachi, Pakistan.

² Department of Radiology, King Edward Medical University, Lahore, Pakistan.

PJR January - March 2018; 28(1): 77-81

ABSTRACT

Trigeminal neuralgia (TN) is a severe paroxysmal pain disorder in the territory of one or more of trigeminal nerve branches. Etiology is not very well known, neurovascular conflict is found to be the most common cause in most studies. Vertebrobasilar dolichoectasia (VBDE) is a rare but treatable cause of TN and we found this in our 57 years old male patient.

Brain MRI is a key to its definitive diagnosis and it should be interpreted by expert neuroradiologist.

In patients resistant to medical therapy, microsurgical decompression is an effective therapeutic option.

Key words: Trigeminal neuralgia, vertebrobasilar, microvascular decompression surgery.

Clinical History

A 57 year old male, known hypertensive and diabetic, presented in neurosurgery clinic with the complains of left sided facial pain for the last 3 years.

Imaging Findings

Ectatic and tortuous vertebrobasilar circulation with basilar arterial diameter of 6.3 mm representing dolichoectasia (Fig. 1). Cisternal segment of left trigeminal nerve appears to be compressed and displaced by tortuous and ectatic basilar artery (Fig. 2). The ectatic basilar is also indenting the brain stem however no abnormal parenchymal signals.

Imaging findings represent vertebrobasilar dolichoectasia resulting in compression and displacement of the left trigeminal nerve cisternal segment (Fig. 3).

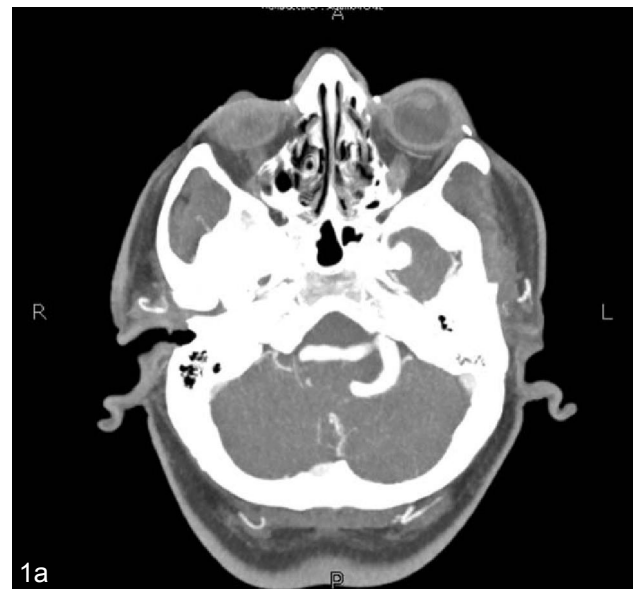

Figure 1a: CT brain with contrast Axial section. Dilated tortuous vertebrobasilar system

Correspondence : Dr. Amna Alvi
Department of Radiology,
The Aga Khan University Hospital (AKUH),
Karachi, Pakistan.
Email: aamnaalvi@gmail.com

Submitted 2 October 2017, Accepted 23 November 2017

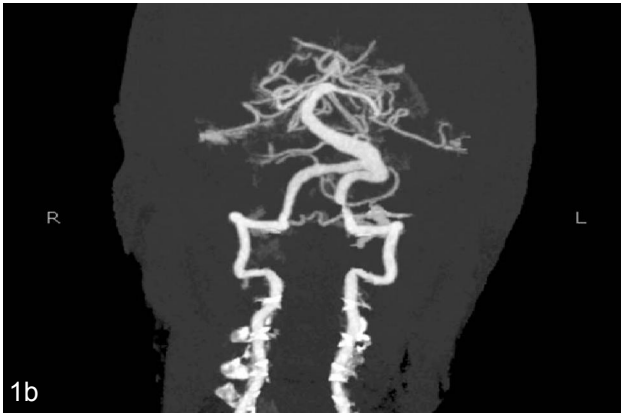


Figure 1b: CT brain with contrast Reformatted 3D. Dilated tortuous verteobasilar system

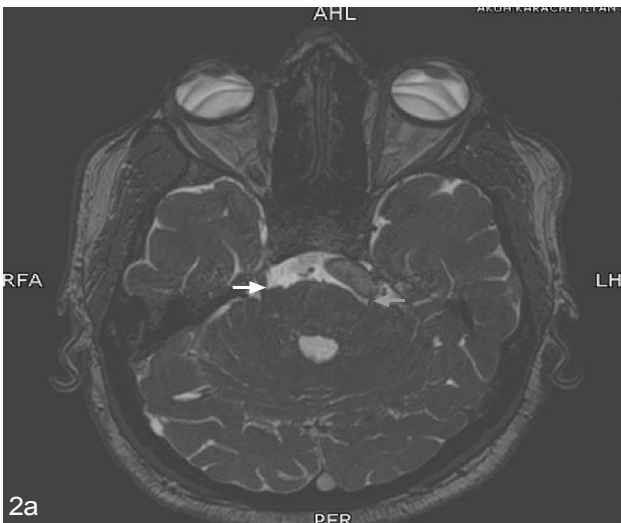

Figure 2a: MRI brain-CISS image CISS Axial image. White arrow indicating right trigeminal nerve. Gray arrow indicating left trigeminal nerve, being compressed by adjacent VBDE.

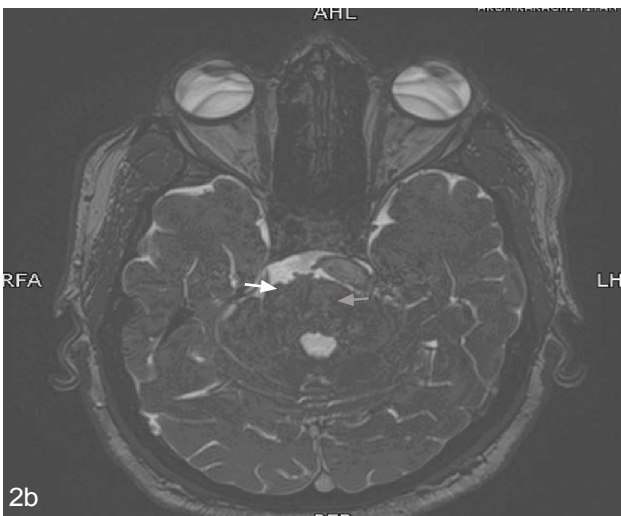

Figure 2b: MRI brain-CISS image CISS Axial image. White arrow indicating right trigeminal nerve. Gray arrow indicating left trigeminal nerve, being compressed by adjacent VBDE.

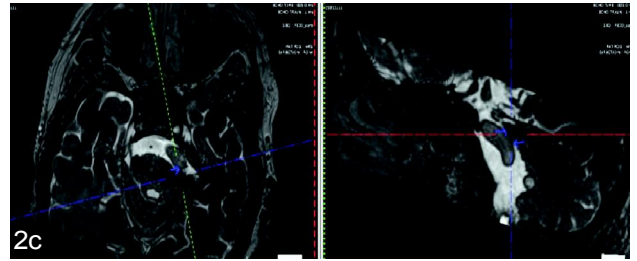


Figure 2c: MRI brain-CISS image CISS axial and sagittal images. Blue arrow indicating left trigeminal nerve.

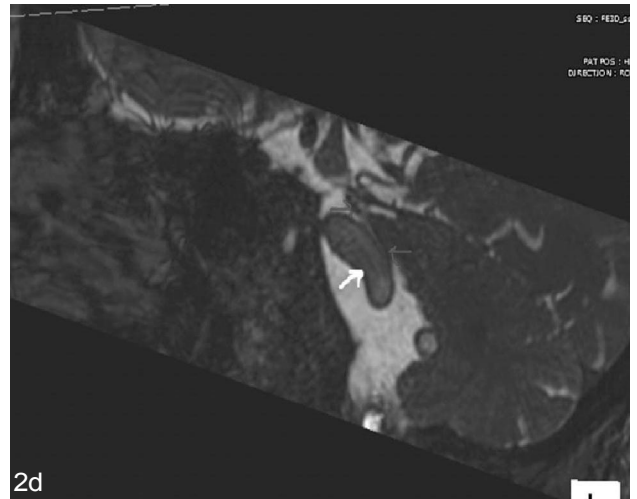


Figure 2d: MRI brain-CISS image CISS sagittal image. Gray arrow indicating left trigeminal nerve. White arrow shows VBDE.

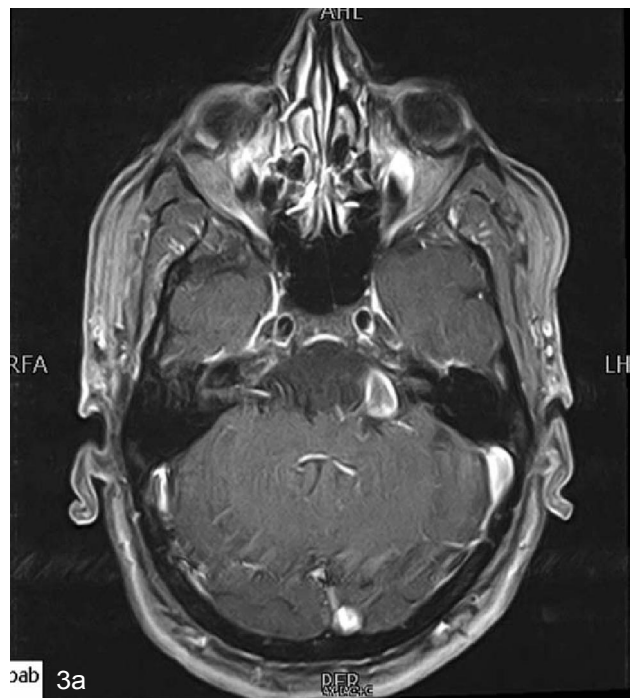


Figure 3a: Post contrast T1WI Axial section showing VBDE.

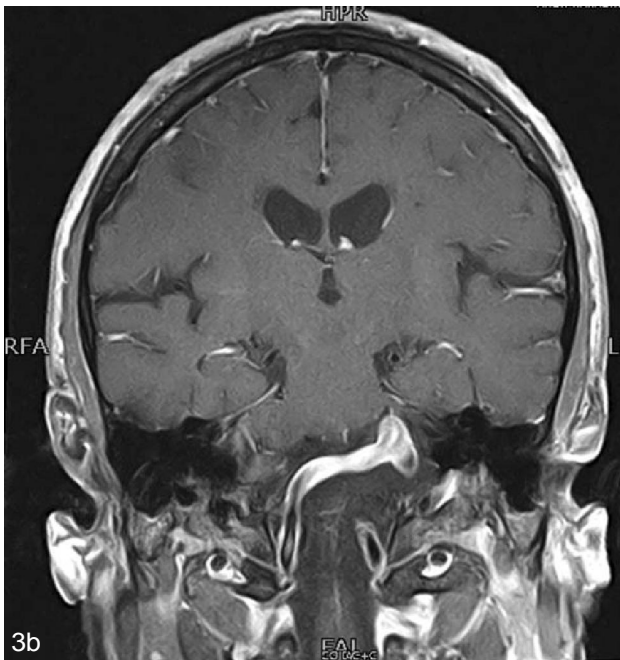


Figure 3b: Post contrast TIWI Coronal section showing VBDE

Background

Trigeminal neuralgia (TN) is a severe paroxysmal pain disorder characterized by attacks in the territory of one or more of trigeminal nerve branches. Annual incidence is 5 per 100, 000 people. Etiology is not very well known. Some studies suggest that more than 80% of cases are the result of neurovascular conflict,¹ in 75% by superior cerebellar artery, in 10% by anterior inferior cerebellar artery and in 7% by venous compression. Vertebrobasilar artery dolichoectasia (VBDE) is rare, causing only 2 to 2.4% of cases.^{2,3} A dolichoectatic artery is defined by a diameter >4.5 mm at any location along its course.⁴ Prolonged vascular compression leads to demyelination and axonopathy, resulting in hyperexcitability that can lead to pain paroxysms.⁵

Clinical Perspective

Usually affect middle or old age.^{6,7} TN by VBDE is commonly left sided because of dominant left vertebral artery, more common in hypertensive old males.^{8,9,10} Patient presents with attacks of electric shock-like

facial pain, occurring spontaneously or triggered by mild tactile stimuli. In majority pain is unilateral involving 2nd or 3rd division of nerve. Unlike other painful neuropathies, TN patients are often pain-free between attacks. With disease progression attacks become more frequent.¹¹

Imaging Perspective

Catheter angiography is gold standard,^{12,13} but due to associated risks of invasiveness, noninvasive modalities like CT, MRI have emerged with high adequacy. Brain MRI with 3D - CISS, 3D - TOF or angio-MRI (contrast-enhanced T1-weighted MRI) is usually the modality of choice.^{3,14} MRI sensitivity for diagnosing VBDE is 97% and specificity is 100%.¹⁵

Treatment

First-line is medical with carbamazepine. When it fails or patients develops side effects, then surgery is considered.¹⁶ Various surgical options include trigeminal nerve block, retrogasserian injection of glycerol, balloon compression or radiofrequency destruction of gasserian ganglion, microvascular decompression of trigeminal root.^{17,18,19} Microvascular decompression is gold-standard.^{20,21} There can be sensory loss or recurrence after surgery.^{22,23} In our patient initially attempt was made for left trigeminal balloon gangliolysis under fluoroscopic guidance but due to venous bleeding procedure was abandoned. He presented again with aggravated symptoms after 2 years and this time left retrosigmoid craniotomy and decompression of trigeminal nerve (teflon placement) was done.

OUTCOME:

Symptoms resolved completely. No post op complication.

FINAL DIAGNOSIS:


Vertebrobasilar dolichoectasia compressing and displacing left trigeminal nerve.

DIFFERENTIAL DIAGNOSIS:

- Arteriovenous malformation (AVM)
- Vertebrobasilar aneurysm

References

1. Love S, Coakham HB. Trigeminal neuralgia: pathology and pathogenesis. *Brain*. 2001 Dec 1; **124(12)**: 2347-60.
2. Borucki L, Szyfter W, Wrobel M, Sosnowski P. Neurovascular conflicts. *Otolaryngologia polska= The Polish otolaryngology*. 2006; **60(6)**: 809-15.
3. Apra C, Lefaucheur JP, Le Guérinel C. Microvascular decompression is an effective therapy for trigeminal neuralgia due to dolichoectatic basilar artery compression: case reports and literature review. *Neurosurgical review*. Jan 2017; **14**: 1-6.
4. Ubogu EE, Zaidat OO. Vertebrobasilar dolichoectasia diagnosed by magnetic resonance angiography and risk of stroke and death: a cohort study. *Journal of Neurology, Neurosurgery & Psychiatry*. Jan 2004; **75(1)**: 22-6.
5. Devor M, Govrin-Lippmann R, Rappaport ZH. Mechanism of trigeminal neuralgia: an ultrastructural analysis of trigeminal root specimens obtained during microvascular decompression surgery. *Journal of neurosurgery*. Mar 2002; **96(3)**: 532-43.
6. Mason WE, Kollros P, Jannetta PJ. Trigeminal neuralgia and its treatment in a 13-month-old child: a review and case report. *Journal of Craniomandibular Disorders*. Jul 1991; **5(3)**.
7. Childs AM, Meaney JF, Ferrie CD, Holland PC. Neurovascular compression of the trigeminal and glossopharyngeal nerve: three case reports. *Archives of disease in childhood*. Apr 2000; **82(4)**: 311-5.
8. Katusic S, Beard CM, Bergstralh E, Kurland LT. Incidence and clinical features of trigeminal neuralgia, Rochester, Minnesota, 1945-1984. *Annals of neurology*. Jan 1990; **27(1)**: 89-95.
9. Linskey ME, Jho HD, Jannetta PJ. Microvascular decompression for trigeminal neuralgia caused by vertebrobasilar compression. *Journal of neurosurgery*. Jul 1994; **81(1)**: 1-9.
10. Sindou M, Leston JM, Le Guerinel C, Keravel Y. Traitement de la névralgie trigéminal par décompression vasculaire microchirurgicale. *Neurochirurgie*. Apr 2009; **55(2)**: 185-96.
11. Bennetto L, Patel NK, Fuller G. Trigeminal neuralgia and its management. *BMJ: British Medical Journal*. Jan 2007; **334(7586)**: 201.
12. Yuh SJ, Alkherayf F, Lesiuk H. Dolichoectasia of the vertebral basilar and internal carotid arteries: A case report and literature review. *Surgical neurology international*. 2013; **4**.
13. Lou M, Caplan LR. Vertebrobasilar dilatative arteriopathy (dolichoectasia). *Annals of the New York Academy of Sciences*. Jan 2010; **1184(1)**: 121-33.
14. Leal PR, Froment JC, Sindou M. MRI sequences for detection of neurovascular conflicts in patients with trigeminal neuralgia and predictive value for characterization of the conflict (particularly degree of vascular compression). *Neuro-Chirurgie*. Feb 2010; **56(1)**: 43-9.
15. Horínek D, Brezova V, Nimsky C, Belšan T, Martinkovic L, Masopust V, Vrána J, Kozler P, Plas J, Krýsl D, Varjassyová A. The MRI volumetry of the posterior fossa and its substructures in trigeminal neuralgia: a validated study. *Acta neurochirurgica*. Jun 2009; **151(6)**: 669.
16. Cruccu G, Gronseth G, Alksne J, Argoff C, Brainin M, Burchiel K, Nurmikko T, Zakrzewska JM. AAN-EFNS guidelines on trigeminal neuralgia management. *European Journal of Neurology*. Oct 2008; **15(10)**: 1013-28.
17. Brown JA, McDaniel MD, Weaver MT. Percutaneous trigeminal nerve compression for treatment of trigeminal neuralgia: results in 50 patients. *Neurosurgery*. Apr 1993; **32(4)**: 570-3.
18. Kanpolat Y, Savas A, Bekar A, Berk C. Percutaneous controlled radiofrequency trigeminal rhizotomy for the treatment of idiopathic trigeminal neuralgia: 25-year experience with 1600 patients. *Neurosurgery*. Mar 2001; **48(3)**: 524-34.

-
- 
19. Zakrzewska JM, Jassim S, Bulman JS. A prospective, longitudinal study on patients with trigeminal neuralgia who underwent radiofrequency thermocoagulation of the Gasserian ganglion. *Pain*. Jan 1999; **79(1)**: 51-8.
 20. Spatz AL, Zakrzewska JM, Kay EJ. Decision analysis of medical and surgical treatments for trigeminal neuralgia: how patient evaluations of benefits and risks affect the utility of treatment decisions. *Pain*. Oct 2007; **131(3)**: 302-10.
 21. Tatli M, Satici O, Kanpolat Y, Sindou M. Various surgical modalities for trigeminal neuralgia: literature study of respective long-term outcomes. *Acta neurochirurgica*. Mar 2008; **150(3)**: 243-55.
 22. Zakrzewska JM, Akram H. Neurosurgical interventions for the treatment of classical trigeminal neuralgia. *Cochrane Database Syst Rev*. Nov 2008; 9.
 23. Fariselli L, Ghielmetti F, Bosetti D, Franzini A, Marchetti M. The role of radiosurgery in trigeminal neuralgia. *Neurological Sciences*. May 2017; **38(1)**: 63-5.