

CEREBROFACIAL ARTERIOVENOUS METAMERIC SYNDROME (CAMS) 2 RARE ENTITY : HOW TO DIAGNOSE

Saima Ahmad, Umair Rashid

Neuroradiology Department, Punjab Institute of Neurosciences, Lahore, Pakistan

PJR April - June 2018; 28(2): 163-167

ABSTRACT

Cerebrofacial arteriovenous metamerism syndrome (CAMS) is a recent classification of vascular malformations that encompasses a spectrum of phenotypic expression involving arteriovenous malformations (AVMs) of the cerebral, orbital and facial region. Recognizing the CAMS is important for diagnosing other AVMs along the same metamerism level. We present a case with intraparenchymal AVM and maxillofacial AVM without optic nerve involvement, characteristics of CAMS 2. The diagnosis of intracranial and facial AVM was made by magnetic resonance imaging of the brain and confirmed with digital subtraction angiography.

Key words: Cerebrofacial Arteriovenous Metamerism Syndromes (CAMS), natural history, angioarchitecture

Introduction

A rare case of Cerebrofacial Arteriovenous Metamerism Syndrome (CAMS) in a 28 years old man is described with arteriovenous malformation involving simultaneously brain and the face. This case represents CAMS 2 according to the classification described by Lasjaunias et Al. The metamerism distribution of the cerebrofacial arteriovenous syndromes is well illustrated in this case. The extracranial and intracranial involvement is described and appearance on imaging is detailed. In our opinion this case demonstrates a spectrum of disease expression of cerebrofacial vascular structures related by the same neural crest origin, named cerebrofacial arteriovenous metamerism syndrome (CAMS) by Bhattacharrya et Al.¹ We describe CAMS in terms of natural history, clinical presentation, angioarchitecture, intra cranial AVM and proper investigation to diagnose this suspicious case.

Case Report

A 28 year old man presented at the age of 28 years with facial asymmetry. This started at infancy as a

small mark on right face and developed into a very large maxillo-facial venous malformation. He underwent near total surgical debulking in 2008 (at 21 years of age). The swelling regrows after 3 months interval. Now for the past one year he had occasional episodes of bleeding from skin locally along with epistaxis and swelling becomes painful as well. A month ago patient was referred to our department for diagnosis and treatment purposes. During history taking he disclosed trivial headaches. As a part of investigation magnetic resonant imaging of brain done which revealed intracranial AVM which was missed. He works as car mechanic. There is no past history of seizures or any family history of venous malformation.

Clinical examination revealed a physically well developed 28 year old right handed man. He had an asymmetry of face due to swollen right cheek. He is neurologically intact. (Fig-1a-1b)

Imaging MRI examination done recently demonstrated a right sided facial venous malformation involving the soft tissues of the cheek and lower eyelid and extending into deeper structures of infratemporal fossa on right side. (Fig.2a-2b-2c)

Correspondence : Dr. Saima Ahmad
Neuroradiology Department,
Punjab Institute of Neurosciences,
Lahore, Pakistan.
Email: masterinfluencer@gmail.com

Submitted 18 September 2017, Accepted 3 January 2018

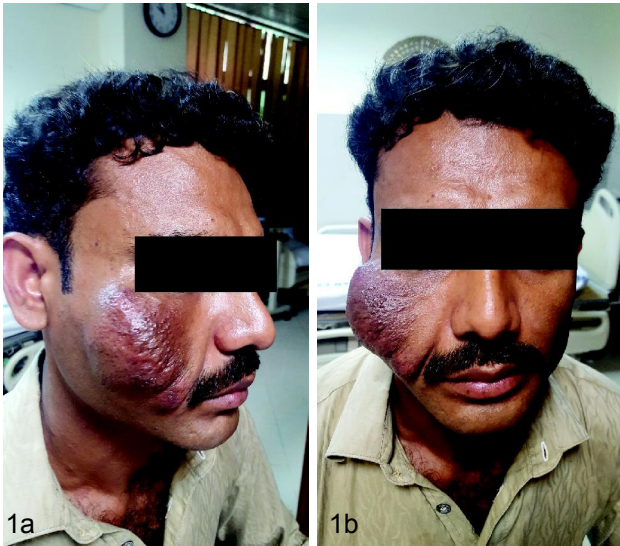

Figure 1a-1b: Clinical examination revealed a physically well developed 28 year old right handed man. He had an asymmetry of face due to swollen right cheek. He is neurologically intact.

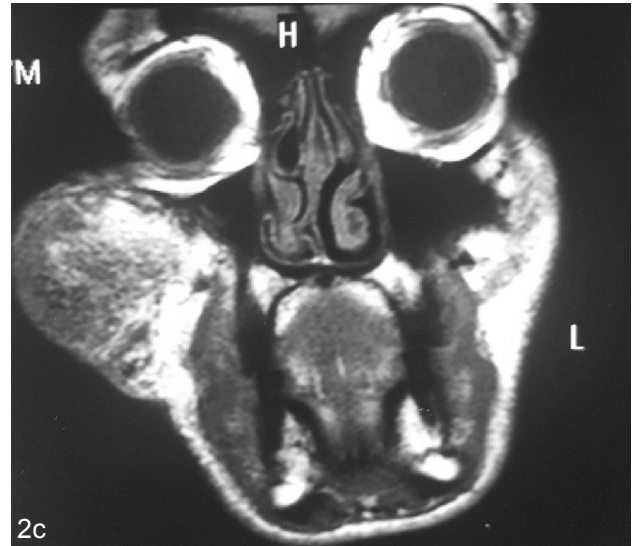
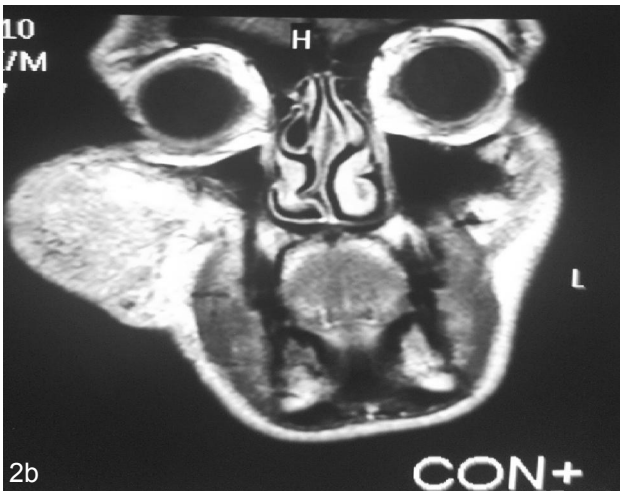
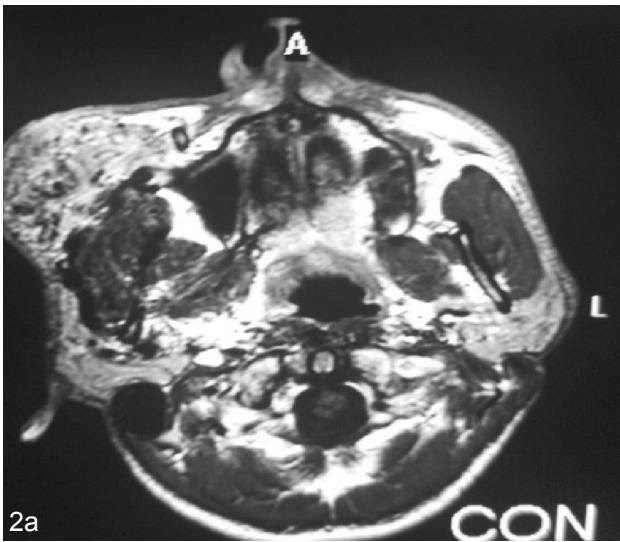
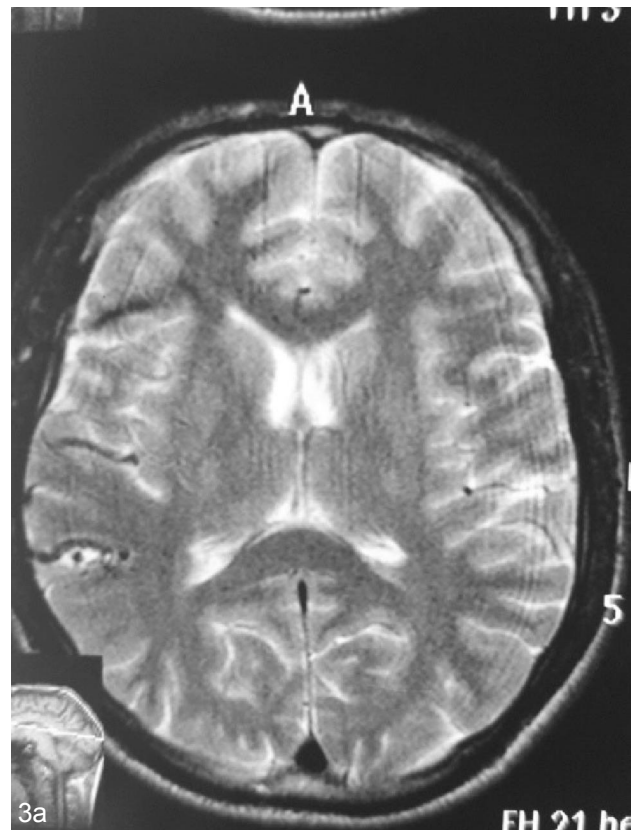


Figure 2a-2b-2c: Imaging MRI examination done recently demonstrated a right sided facial venous malformation involving the soft tissues of the cheek and lower eyelid and extending into deeper structures of infratemporal fossa on right side.



MRI of the brain revealed sulcal AVM right post temporal lobe along the marginal/triangular gyrus (Fig. 3a-3b).



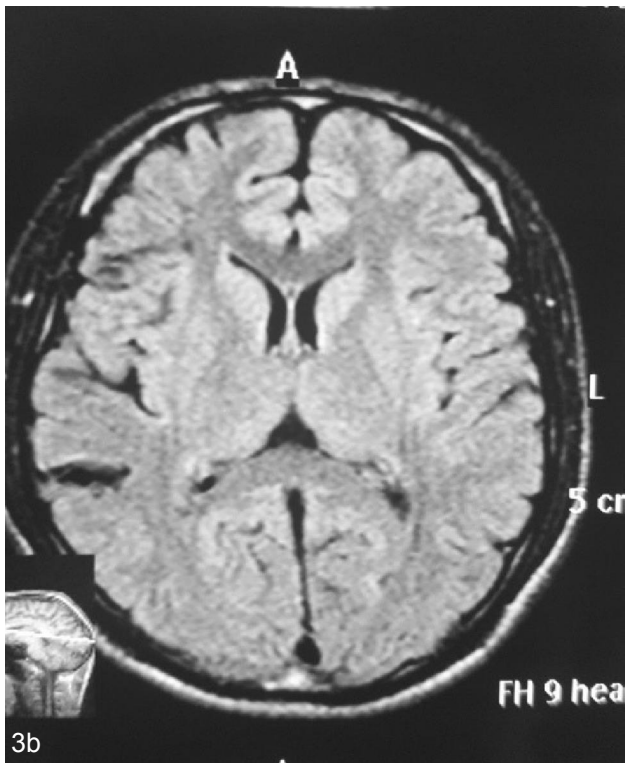


Figure 3a-3b: MRI of the brain showing sulcal AVM right post temporal lobe along the marginal/triangular gyrus.

CT angiography showed right cheek arteriovenous malformation and intracranial AVM which was missed on imaging. (Fig.4)

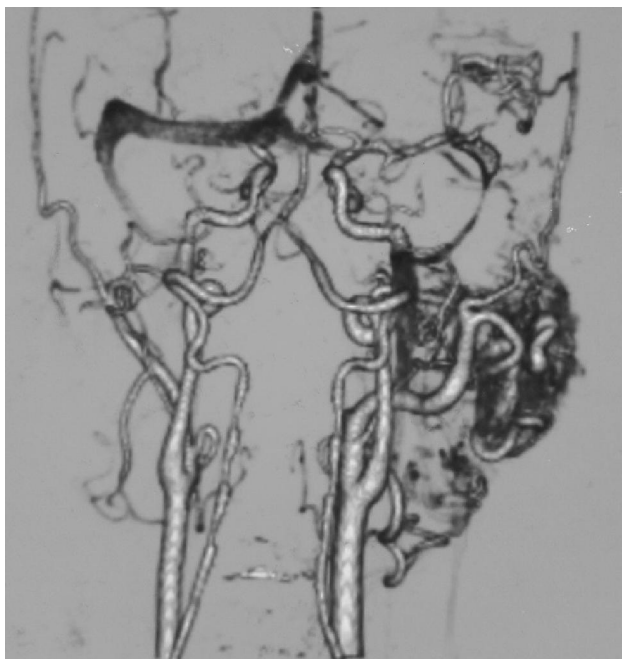

Figure 4: CT angiography showing right cheek arteriovenous malformation and intracranial AVM which was missed on imaging.

Diagnostic angiography showed the high flow arteriovenous malformation locating right cheek, fed by the right internal maxillary artery, draining through facial vein. Selective angiography of right internal carotid artery showed right posterior temporal lobe sulcal arteriovenous malformation, fed by the inferior trunk of middle cerebral artery, draining through superficial venous system. (Fig. 5a-5b-5c)

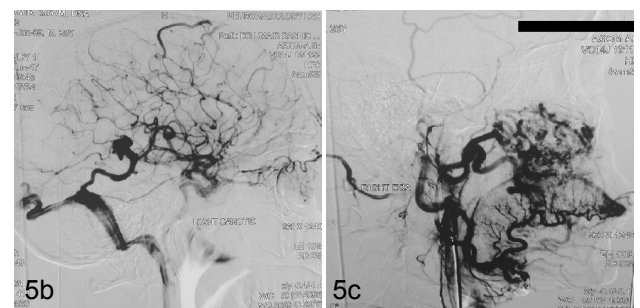
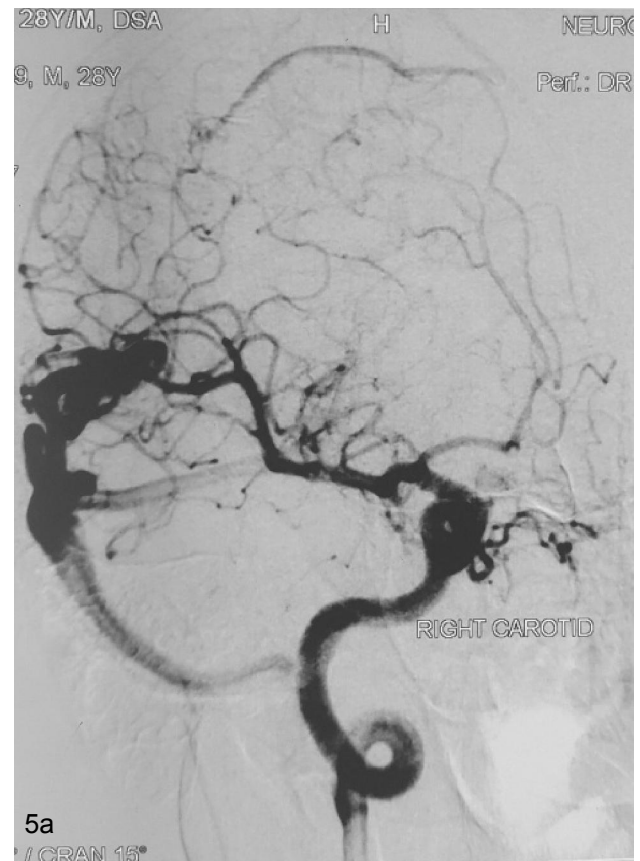


Figure 5a-5b-5c: Diagnostic angiography showing the high flow arteriovenous malformation locating right cheek, fed by the right internal maxillary artery, draining through facial vein. Selective angiography of right internal carotid artery showed right posterior temporal lobe sulcal arteriovenous malformation, fed by the inferior trunk of middle cerebral artery, draining through superficial venous system.

Discussion

An association between arteriovenous malformation of face, retina and brain was first recognized by Bonnet, Dechaume and Blanc in 1937 and Wyburn Mason in 1943.³ Furthermore, in 1995 Couly demonstrated that endothelial cells of cephalic region have a regionalized origin providing blood vessels to specific regions of face and brain.⁴ The neural crest and mesodermal cells arising from a certain transverse level occupy the same facial territories.⁵ Since the endothelium and media of blood vessels are derived from mesoderm and neural crest respectively, Lesjaunias group used this approach to regroup the neural tube and neural crest derivatives to associate between certain maxillofacial and central nervous system malformations.⁵⁻⁶⁻⁷ Moreover, the case report of Gupta et al⁸ describing two patients⁹ there were unilateral cerebral and orbital AVMs with facial involvement (a venous malformation in one case and a maxillofacial AVM in the other). One of these patients had optic atrophy but in neither did fundoscopy identify a retinal AVM.

Lesjaunias group suggested the name Cerebrofacial Arterial/venous Metameric syndrome (CAMS or CVMS) for conditions with arterial or venous malformations simultaneously involving the brain and the face. According to new classification three subgroups are identified within CAMS or CVMS. CAMS 1 or the "median prosencephalic group" involves the hypothalamus and the hypophysis as the intracranial component and nose as the facial component. CAMS 2 or the "lateral prosencephalic group" involves the occipital lobe, thalamus, optic tract and retina intracranially and the maxilla as its facial component. CAMS 3 or the "lateral rhombencephalic group" involves the cerebellum and pons intracranially and the mandible as the facial component.¹⁰ Using this classification our case represents CAMS 2.


The intracranial findings in our case, although predominantly ipsilateral to the facial involvement but does not involve retina. This could be explained by Couly's comment that the regionalization of the cephalic neural crest and mesoderm is not strict.⁴ According to him this may allow some fluidity in the final expression. Furthermore, this is supported by similar bilaterality reported by Boukobza et al in one of their unilateral facial malformation patients.¹¹

Conclusion

The diagnosis of cerebrofacial arteriovenous metamerism syndrome (CAMS 2) encompasses a spectrum of phenotypic expression. A portion of these patients manifest the complete expression of the disease with arteriovenous malformation of brain and additional high flow arteriovenous malformation of the maxillofacial region. These presents the additional risks of life threatening hemorrhage. We suggest any patient who present with facial arteriovenous malformation or venous malformation must be investigated further for intracerebral arteriovenous malformations.

References

1. Bhattachaya JJ, Luo CB, Suh DC. Wyburn-Mason or Bonnet-Dechume-Blanc as Cerebrofacial Arteriovenous Metameric Syndromes (CAMS). A new concept and new classification. *Interventional Neuroradiology*. 2001; **7**: 5-17.
2. Bonnet P, Dechaume J, Blanc E. L'anevrisme-cirsoide de la retine. (Anevrismeracemeux). Sesrelations avec l'anevrymecirsoide du cerveau. *Le Journal Medical de Lyon*. 1937; **18**: 165-78.
3. Wyburn-Mason R. Arteriovenous aneurysm of midbrain and retina, facial naevi and mental changes. *Brain*. 1943; **66**: 163-203.
4. Couly G, Coltey P, et al. The angiogenic potentials of the cephalic mesoderm and the origin of brain and head blood vessels. *Mech Develop*. 1995; **53**: 97-112.
5. Luo C, Bhattacharya J, et al. Cerebrofacial vascular disease. *Orbit*. 2003; **22(2)**: 89-102.
6. Ramli N, Sachet M, et al. Cerebrofacial venous metamerism syndrome (CVMS) 3: Sturge-Weber syndrome with bilateral lymphatic/venous malformations of the mandible. *Neuroradiology*. 2003; **45(10)**: 687-90.

-
- 
7. Jiarakongmun P, Alvarez A, et al. Clinical course and angioarchitecture of cerebrofacialarteriovenous metamerism syndromes: Three demonstrative cases and literature review. *Interventional Neuroradiology*. 2002; **8(3)**: 251-64.
 8. Patel U, Gupta SC. Wyburn-Mason syndrome. A case report and review of the literature. *Neuroradiology*. 1990; **31**: 544-6.
 9. Brown D, Hilal SK, Tenner MS. Wyburn-Mason syndrome: report of two cases without retinal involvement. *Arch Neurol*. 1973; **28**: 67-8.
 10. Lasjaunias P, Terbrugge KG, Berenstein A. Chapter 8: Venous anomalies and malformations. In: Lasjaunias P, Terbrugge KG, Berenstein A, editors. *Surgical Neuroangiography 3 clinical and interventional aspects in children*. Second. Heidelberg: Springer-Verlag Berlin; 2006. pp. 478-502.
 11. Boukobza M, Enjolras O, et al. Cerebral developmental venous anomalies associated with head and neck venous malformations. *Am J Neuroradiol*. 1996; **17(5)**: 987-94.