

EMBOLIZATION OF A SECONDARY UTERINE AVM POST DILATATION AND CURETTAGE FOR FIRST TRIMESTER PREGNANCY LOSS- A CASE REPORT

SK Samsuz Zaman, Debashis Dakshite

Department of Radio Diagnosis, Medical College, The West Bengal University of Health Sciences, Kolkata, West Bengal, India.

PJR January - March 2018; 28(1): 72-76

ABSTRACT

Uterine arteriovenous malformation (AVM) is a rare condition, with fewer than 100 cases reported in the literature.¹ A potentially life-threatening condition can be easily detected by colour doppler ultrasound (US) confirmed by diagnostic angiography. Additionally angiography provides the opportunity to perform minimally invasive interventions like embolization which is slowly becoming the procedure of choice for its advantage of preserving future fertility.

Key word: Uterine Artery Embolization, Uterine Arteriovenous Malformation, DSA, USG, D&E

Introduction

Uterine AVM is an abnormal connection between the uterine arteries & veins. It can be congenital or acquired (traumatic). Congenital AVM is very rare¹ but acquired cases are increasing due to D&C, cervical or endometrial carcinoma, trophoblastic disease. Some patients may present with profuse vaginal bleeding endangering life.

Treatment depends on age, symptoms, desire for conception, localization & size of lesion. In this case embolization of uterine artery is the 1st choice as the patient is young, in the reproductive age group with desirous of future pregnancy.

Here we report a case of acquired AVM following D&C which was treated successfully with uterine artery embolization.

Case Report

A 23-year-old Mrs.X presented to us with continuous vaginal spotting after D&C done after her first trimester pregnancy loss.

On examination, she was afebrile and hemodynamically stable with a haemoglobin (Hb) of 09.4 g/dL. Vaginal examination showed a small amount of blood at the external OS but no active bleed could be seen. Her beta-HCG level was less than 2 mIU/mL.

Trans abdominal US of the pelvis showed a bulky uterus measuring 7.9 cm × 5.3 cm × 6.5 cm with an endometrial thickness of 2.1 cm. There was increased vascularity of the uterus with a prominent vessel seen on the both anterior & posterior myometrium of uterus, with likely origin from B/L uterine arteries. Spectral Doppler US showed a peak systolic velocity (PSV) of 65 cm/s and resistive index (RI) of 0.84 (Fig. 1). A diagnosis of an AVM was considered and an angiogram was suggested for confirmation. The diagnostic angiography confirmed the presence of an arteriovenous malformation. There were multiple primary arterial feeders & branches, mainly from the right uterine arteries, with few minor feeders from the left uterine artery. An early draining vein was also noted at the fundal region of the uterus (Fig. 2).

Correspondence : Dr. SK Samsuz Zaman
Department of Radio Diagnosis, Medical College,
The West Bengal University of Health Sciences,
Kolkata, West Bengal, India.
Email: drsksamsuzzaman86@gmail.com

Submitted 31 July 2017, Accepted 11 October 2017

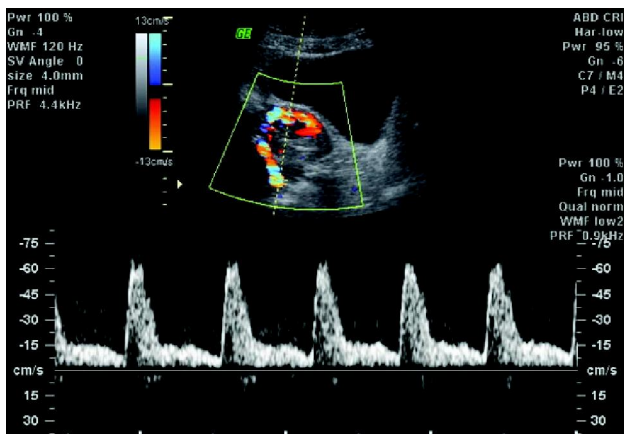


Figure 1: Trans abdominal ultrasound of the pelvis shows bulky uterus with increased vascularity and multidirectional flow on doppler.

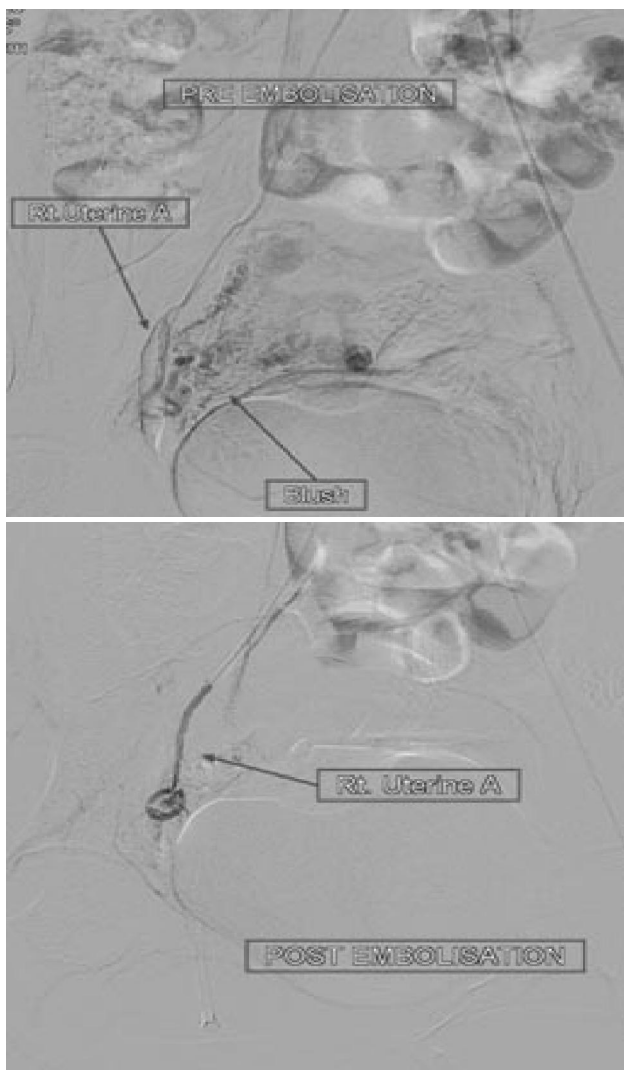


Figure 2: Angiogram of the right uterine artery showed a contrast blush suggestive of an arteriovenous malformation (AVM), which disappeared post-embolization indicating successful embolization.

We then proceeded with embolization of the AVM. Embolization of both uterine arteries were performed with a mix of 300-500 μ m and 700-1000 μ m poly-vinyl alcohol (PVA) particle. The post-embolization arteriogram showed no significant contrast blush, indicating successful embolization of the AVM (Fig. 2). No periprocedural/post procedural complications were seen. The patient's vaginal bleeding had decreased significantly on post-embolization period and hence she was discharged.

During follow up on 6th post operative day, patient was asymptomatic & trans abdominal USG revealed uterus with an endometrial thickness of 1.7 cm without any vaginal bleeding.

At 2 month follow up patient was asymptomatic with normal regular menstrual cycle.

Discussion

Uterine vascular abnormalities are rare group of disorders. It can be potentially life-threatening disorder with vaginal bleeding that may be so profuse to cause hemodynamic instability. It should also be suspected in women of reproductive age with unexplained vaginal bleeding and in post-menopausal women when anechoic structures are identified by US.²

Dubreuil and Loubat reported the first case of uterine AVM in 1926.³ To date, there are fewer than 100 cases reported in the literature.¹ AVM consists of proliferation of arterial and venous channels with fistula formation and a mixture of capillary-like vessels. Distinction between arteries and veins are difficult because secondary intimal thickening in veins occurs due to increased intraluminal pressure.³

Uterine AVM may be congenital or acquired.²⁻⁴ Congenital AVM is believed to arise from arrested vascular embryologic development resulting in anomalous differentiation of the capillaries and causing abnormal communication between arteries and veins.² Congenital AVMs can have multiple vascular connections and may invade surrounding structures. Most have been found as isolated cases, but few also been reported with multisite occurrence of AVMs.⁴ In contrast acquired AVM are more common and usually follows episodes of uterine trauma, such as curettage procedures, caesarean section, or pelvic surgery. Because of the potential to develop abnormal commu-

nication between arteries and veins occurs during the healing process. Acquired AVMs are also associated with infection, retained POC, gestational trophoblastic disease, gynaecologic malignancies, and exposure to diethylstilboestrol.

In this case, acquired AVM was likely due to dilatation & curettage after first trimester miscarriage.

Diagnoses of AVM have been traditionally diagnosed by laparotomy or during post hysterectomy examination of the uterus.⁴ However, with the easy & wide availability of colour doppler US, early non-invasive detection is possible. Digital subtraction angiography remains the gold standard of diagnosis.⁴

B mode ultrasound can detect the presence of multiple tubular or "spongy" anechoic or hypoechoic areas within the myometrium of a normal endometrium.^{2,4,5} However, other conditions may present a similar appearance, such as retained products of conception, haemangioma, gestational trophoblastic disease, multilocular ovarian cysts, or hydrosalpinx. Using colour and spectral doppler US help us for obtaining more accurate information. A normal myometrial signal will show a PSV of 9 - 44 cm/s and RI of 0.6 - 0.8. But, uterine AVM will exhibit intensely vascular and multidirectional flow (regions of juxtaposed reds and blues caused by multiple tortuous vessels of varying orientations). Spectral doppler US will show high velocity (mean PSV: 136 cm/s), low resistance (mean RI: 0.3) flow, low pulsatility of the arterial waveform, and pulsatile high-velocity venous waveform.^{4,5} Differentiation between the venous and arterial waveform is often difficult, and the pelvic veins distal to the AVM may show pulsatile flow instead of the normal monophasic flow.⁴

Retained products of conception may also give a hyper vascular appearance with turbulent flow & RPOC with AVM can coexist complicating diagnose further.⁶ Similarly Gestational trophoblastic disease (GTD), particularly in patients with associated uterine arteriovenous fistula, may also have similar US findings of increased uterine vascularity with a low RI.⁷ A rare form of GTD, called placental site trophoblastic disease (PSTT), does not produce high levels of b-HCG, and instead produces high levels of human placental lactogen (hPL).⁸ However, the hPL levels were not measured in this patient because GTD and PSTT were not considered in the differential diagnosis.

Gadolinium enhanced MRI demonstrates a hypervas-

cular arterial dominant flow. Similar to MRI, CT may be used to determine the size, extent, vascularity. Digital subtraction angiography (DSA) remains the gold standard for the diagnosis of AVM. Findings include hypertrophy of B/L uterine arteries that feed a tortuous, hypertrophic arterial mass with large accessory feeding vessels, and early drainage into enlarged hypertrophic veins.⁴ However, DSA is rarely performed for purely diagnostic purpose due to its invasive nature and is usually reserved when a patient requires surgical intervention or embolization.

The treatment changes depending on the age, desire for future fertility, localization, and size of the lesion.

The mainstay for management of uterine AVM has been hysterectomy or the embolization of uterine arteries. However, the uterine artery embolization (UAE) remains the first choice of treatment in women at reproductive age having expectation of future fertility.¹⁰ A wide spectrum of management plans have been proposed for uterine AVMs including observation, oral medications, UAE, laparoscopic bipolar coagulation, surgical ligation of uterine arteries, and hysterectomy.¹¹ Acute management involves stabilising the patient's hemodynamic status, and stopping blood loss. Traditionally, a hysterectomy was the treatment of choice. However, the patient's desire for future pregnancy is an important consideration, as there are options available now to avoid a hysterectomy. In stable patients who have the ability for close follow-up, expectant, and long-term medical management may be tried. Spontaneously resolved AVM have been reported in literature.⁶ Contraceptives like intramuscular and subsequent oral methylergonovine maleate have been associated with regression of lesions based on sonographic imaging.⁴

If episodes of recurrent bleeding occur, or experiences bleeding severe enough to cause hemodynamic instability, angiographic embolization is considered. Transcatheter arterial embolization has emerged as a highly effective technique for controlling obstetric and gynaecologic haemorrhages and has revolutionized the management of uterine AVMs. The size of the AVMs in imaging studies does not correlate with the need for embolization; this decision relies entirely on the clinical condition of the patient.

Since the first description of a successful embolization treatment for uterine AVM back in 1986, it has been commonly used in the emergent as well as urgent

circumstances. Various embolic materials have been used, including polyvinyl alcohol, histoacryl (glue), stainless steel coils, detachable balloons, and haemostatic gelatine. Some patients may require repeat embolization.⁴ Emergency hysterectomy is no longer necessary due to availability of embolization procedure. However, hysterectomy remains the treatment of choice in post-menopausal patients or as an emergency treatment in life-threatening situations.⁹

This case report highlights the use of USG and DSA for diagnosing an acquired uterine AVM in a female of a reproductive age group who presented with secondary post-partum haemorrhage. It also highlights our experience in performing embolization in this patient, which assured her the hope of future pregnancy.

In conclusion, Uterine artery embolization (UAE) is a safe and effective treatment for uterine AVMs when the patient has hemodynamic instability or refractory hemorrhaging. If the patient wants to preserve her reproductive ability, UAE is the first management of choice.

Embolization procedure is as follows: Using the Seldinger technique through the common femoral artery, initial pelvic angiography is performed followed by selective internal iliac angiography and uterine angiography on the side presumed to be affected during ultrasonographic examination. Embolic materials are carefully introduced into the uterine artery or other feeding arteries until stasis of flow is confirmed angiographically. Ipsilateral internal iliac angiography is repeated to exclude the possibility of additional feeding arteries, which occasionally, become apparent only after the major feeding artery is occluded.

Then, the contralateral internal iliac artery and uterine artery are examined in the same manner. Embolization of the contralateral uterine artery is performed because of the possibility of cross-filling, followed by contralateral internal iliac angiography. If bleeding does not stop or the vascular abnormality does not disappear, other feeding arteries, such as the ovarian artery, inferior epigastric artery, or middle sacral artery, should be examined. The treatment is usually successful after one or two sessions.

The advantages of transcatheter arterial embolization include outstanding success rates, low complication rates, avoidance of surgical risks, and preservation of fertility. The side effects of the procedure, such as

low-grade temperature, pain, infection, or symptoms, have been documented. Of these, pelvic pain was the main side effect, even requiring opiate and nonsteroidal analgesia. In addition, the procedure has the expected disadvantage of insufficient embolization, demanding a repeat procedure.

Neurologic deficits affecting the lower limb have been reported previously, and seem to be more commonly associated with the use of liquid embolization materials or very small particles. Other serious complications, such as perineal skin sloughing, uterovaginal and recto-vesico-vaginal fistulae, and bladder necrosis, have also been reported in series where the internal iliac arteries have been embolized with cryanoacrylate as the embolizing agent. Nevertheless, the complications of transcatheter arterial embolization are extremely uncommon, and the complication risk is negligible when it is performed by interventional radiology experts. Whether the failure of embolization is a result of the type of embolic material used, expertise of the intervention radiologist, a regrowth of AVMs or the persistence of inherent factors is unclear at present. This issue may be resolved after more of these cases are reported and analyzed.

Conclusion

Uterine AVM is a rare but potentially life threatening source of haemorrhage. So high index of suspicious & accurate diagnosis of the condition is essential to save the life of the patient.

Abnormal vaginal bleeding following induced abortion should be properly evaluated first with USG & colour Doppler, a non-invasive procedure than DSA. DSA is the gold standard for the diagnosis of the uterine AVM.

Prior to embolization expectant management & medication, unilateral/bilateral uterine artery ligation & hysterectomy were the management of choice. Now after the 1st reported case of trans catheter uterine artery embolization in 1982, it has become, the therapy or treatment of choice because having advantage of maintained fertility.

Acknowledgments

Department of Obstetrics and Gynaecology, Medical College, Kolkata.

References

1. Hickey M, Fraser I. Clinical Implications of Disturbances of Uterine Vascular Morphology and Function. *Baillieres Clin Obstet Gynaecol*. 2000; **14(6)**: 937-51.
2. Polat P, Suma S, Kantarcy M, Alper F, Levent A. Colour Doppler Ultrasound in the Evaluation of Uterine Vascular Abnormalities. *Radiographics*. 2002; **22**: 47-53.
3. Fleming H, Ostor A, Pickel H, Fortune D. Arteriovenous Malformations of the Uterus. *Obstet Gynaecol*. 1989; **73(2)**: 209-13.
4. Grivell R, Reid K, Mellor A. Uterine Arteriovenous Malformations: A review of the Current Literature. *Obstet Gynaecol Survey*. 2005; **60(11)**: 761-7.
5. Huang M, Muradali D, Thurnston W, Burns P, Wilson S. Uterine Arteriovenous Malformations: Gray-Scale and Doppler Ultrasound features with MR Imaging Correlation. *Radiology*. 1998; **206(1)**: 115-23.
6. Timmerman D, Bosch TVd, Peeraer K. Vascular Malformations in the Uterus: Ultrasonographic Diagnosis and Conservative Management. *Euro J Obstet Gynaecol Reprod Biol*. 2000; **92**: 171-8.
7. Ichikawa Y, Nakauchi T, Sato T, Oki A, Tsunoda H, Yoshikawa H. Ultrasound diagnosis of uterine arteriovenous fistula associated with placental site trophoblastic tumor. *Ultrasound Obstet Gynecol*. 2003; **21(6)**: 606-8.
8. Gillespie A, Hancock B. In: *Gestational Trophoblastic Disease*. 3rd ed. Hancock B, Seckl M, Berkowitz R, Cole L, editors. International Society for the Study of Trophoblastic Diseases: 2009. pp. 420-9.
9. Delotte J, Chevallier P, Benoit B, Castillon J, Bongain A. Pregnancy after Embolisation Therapy for Uterine Arteriovenous Malformation. *Fertility and Sterility*. 2006; **85(1)**: 228e1-6.
10. S. Soeda, H. Kyojuka, S. Suzuki, S. Yasuda, Y. Nomura, and K. Fujimori, "Uterine artery embolization for uterine arteriovenous malformation is associated with placental abnormalities in the subsequent pregnancy: two cases report," *Fuku-shima Journal of Medical Science*, 2014; **60(1)**: pp. 86-90.
11. Levy-Zaubermann Y, Capmas P, Legendre G, Fernandez H. Laparoscopic management of uterine arteriovenous malformation via occlusion of internal iliac arteries. *J Minim Invasive Gynecol*. 2012; **19(6)**: 785-8.