

ROLE OF TRANSRECTAL ULTRASOUND IN THE DIAGNOSIS OF CARCINOMA OF PROSTATE

Sohail Ahmed Khan,^{1,2} Amjad Sattar,¹ Waseem Akhtar Mirza,³ Syed Omair Adil,⁴ Murli Manohar¹

¹ Department of Radiology, Dow Institute of Radiology, (DUHS), Karachi, Pakistan.

² Department of Radiology, Liaquat National Hospital, Karachi, Pakistan.

³ Department of Radiology, Aga Khan University Hospital, Karachi, Pakistan.

⁴ Department of Research, Dow University of Health Sciences (DUHS), Karachi, Pakistan.

PJR January - March 2017; 27(1): 19-23

ABSTRACT

OBJECTIVE: To determine the diagnostic accuracy of transrectal ultrasound in detecting carcinoma of prostate
SETTING: A prospective, cross-sectional study was performed from 1st February 2006 to 31st July 2016. Transrectal ultrasound was performed with gray-scale and color doppler. Later on, histopathology of these patients was conducted either by surgery or after biopsy. **RESULTS:** Out of total 54 patients, mean age was 61 ±7.89 years (range 53 to 90 years). Diagnostic accuracy of color doppler transrectal ultrasound taking histopathology as gold standard showed sensitivity of 79.0%, Specificity 73.0%, Accuracy 77.0%. **CONCLUSION:** Color Doppler ultrasound found to be a very important adjunct to gray-scale ultrasound as it increases the diagnostic accuracy of carcinoma prostate.

Keywords: Transrectal Ultrasound, Carcinoma Prostate, Diagnostic Accuracy

Introduction

Incidence of prostate cancer is increasing significantly all over the world which is a most common malignancy in males and is largely reported in developed countries. However, in low and middle-income countries, its incidence and mortality have been on the rise.¹⁻⁶

Since the introduction of transrectal ultrasound guided biopsy (TRUS), a vast alteration in the presentation of prostate cancer has been noted.^{7,8} Under local anaesthetic and prophylactic antibiotics, TRUS is now the most extensively used method to diagnose prostate cancer. It is reported that currently, on average, more than 90% cases diagnosed at an asymptomatic early stage (stage T1).⁹

Modern transducers typically are end-firing probes scanning at frequencies of 5 - 10 MHz. The prostate is divided into distinct anatomical zones and these can be depicted by transrectal ultrasound.^{10,11}

The role of transrectal prostate ultrasonography in the detection of suspicious lesions usually underestimated,¹²⁻¹⁴ even a recent study has reported the efficacy of ultrasonography only in guiding the biopsy.¹⁴ However, the sonographic characteristics of nodules considered suspicious have been studied and defined, and hypoechoic solid nodules located in the peripheral region have the highest predictive value for cancer.^{13,15} Currently, with the technological advancement of ultrasound apparatus and intracavitary transducers

Correspondence : Dr. Sohail Ahmed Khan
 Dow Institute of Radiology,
 Dow University of Health Sciences
 Karachi, Pakistan
 Email: ahmedsohail.dr@gmail.com

Submitted 26 October 2016, Accepted 30 November 2016

with increasingly higher frequencies, the number of sonographically detected suspicious nodules has increased.^{16,17} For the same reason, this study was conducted with the aim to determine the diagnostic value of transrectal ultrasound in carcinoma of prostate taking histopathology as the gold standard.

Material & Methods

This cross-sectional study was conducted in Liaquat National Hospital during the period of 1st February 2006 to 31st July 2016. All adult male patients clinically suspected of having carcinoma prostate having more than 50 years of age were enrolled. All these patients underwent transrectal ultrasound on gray scale and colour doppler sonography, followed by ultrasound-guided biopsy of suspicious lesions as well as sextant biopsies. Later on, the final histopathological diagnosis of these patients was compared with transrectal ultrasound exam findings.

Transrectal ultrasound Technique:

All patients were counseled and informed written consent was obtained prior to the biopsy. The night prior to the biopsy, an oral fluoroquinolone antibiotic was given as the first dose, the second dose was given on the morning of the biopsy with two additional doses the night following the biopsy and the following morning. The patient was given enema, the morning of the biopsy and to attempt complete bowel evacuation. No dietary restrictions were placed prior to biopsy. The patients were asked to cease taking all medications that might alter bleeding time or blood clotting (aspirin, coumadin, motrin [ibuprofen]) for 7 to 10 days prior to the biopsy. Biopsies were performed on patients who had an abnormal DRE or elevated PSA or both, more than 4.0 ng/mL. The transrectal ultrasound evaluation and biopsies were obtained with the patient in the lateral position with knees and hips are flexed. No oral or intravenous sedation was used. 2% Xylocaine gel was injected into the ampulla of the rectum and allowed to set for several minutes. The ultrasonic probe was introduced and the prostate was evaluated and measured in both the transverse and sagittal planes. For a biopsy, the prostate was imaged in the sagittal plane.

Color doppler sonography (CDS) was performed at biopsy sites before the biopsy. Vascularity at color doppler sonography was prospectively graded on a scale of 0-2 (0 = no visible peripheral zone (PZ) flow, 1 = minimally increased vascularity in the peripheral zone, 2 = markedly increased PZ vascularity). CDS results were correlated with histologic findings from 300 separate biopsy sites that included 27 focal lesions. Core biopsies were performed in all focal PZ lesions (two to three tissue core specimens), followed by random or systematic core biopsies at four to six sites encompassing all quadrants of the gland. Eighteen gauges (Bard-Monoply; Bard, Covington, Ga) biopsy needles were used. All biopsy samples were visually inspected for adequacy of tissue core and then placed in formalin. The volume of the prostate was estimated in all cases. Volume is established by multiplying the transverse diameter by the length of the prostate and by the depth of the prostate. All patients were allowed to ambulate immediately following the biopsy and were seen again approximately 1 hour following the biopsy to ascertain that they were voiding satisfactorily without significant hematuria and had no significant rectal bleeding.

Image Interpretation Technique:

The image interpretation was done on the basis of diagnostic criteria for carcinoma prostate. The presence of following findings was interpreted as positive for carcinoma prostate in transrectal ultrasound; 1) Enlargement and heterogeneity of prostate architecture. 2) Single or multiple nodules which are Echogenic, hypoechoic or isoechoic in texture. Moreover, vascularity at color doppler sonography was prospectively graded on a scale of 0-2, as Grade 0 "no visible peripheral zone [PZ] flow", Grade 1 "minimally increased vascularity in peripheral zone" and grade 2 "markedly increased PZ vascularity".

Transrectal ultrasound results were compared with findings obtained at the histopathologic examination. The final diagnosis of carcinoma prostate was confirmed at the histopathologic examination.

Data Analysis:

Data initially collected on proforma was entered and analyzed in SPSS version 20. Diagnostic accuracy including sensitivity, specificity, positive predictive value (PPV) and negative predictive value (NPV) of

the transrectal ultrasound was calculated using histopathology as the gold standard.

Results

Initially, 54 patients were included in the study, out of these 4 patients were excluded. Three patients were excluded because of the history of anal fissures while one patient had a history of hemorrhoids. The final number of patients comprising the study was 50 patients.

The mean age of the patients was 61 ± 7.89 years (range 53 to 90 years). All patients had a histopathological diagnosis of either carcinoma prostate with or without associated findings or any of the alternative diagnoses after the transrectal ultrasound exam.

A total of 300 biopsies were taken from 50 patients including focal and sextant biopsies, out of which 180 (60%) were found to be pathological. The average weight of each prostate was 40.2 gm.

Color doppler transrectal ultrasound correctly diagnosed carcinoma prostate prospectively in 162 biopsies (True Positive) whereas color doppler transrectal ultrasound correctly excluded carcinoma prostate in 70 biopsies (True Negative). (Fig. 1) Overall accuracy was 77% for diagnosing carcinoma prostate.

A total of 25 biopsies were incorrectly interpreted as carcinoma prostate (False Positive) whereas 43 patients color doppler transrectal ultrasound could not detect carcinoma prostate. (False Negative).

Out of 25 misinterpreted carcinoma prostate, there were 3 hypoechoic areas which showed slight increase blood flow on color doppler study, these were found to be acute prostatitis, 18 isoechoic areas were found to be acute prostatitis, 4 hyperechoic areas were found to be chronic prostatitis.

Diagnostic accuracy of color doppler transrectal ultrasound taking histopathology as gold standard showed the sensitivity of 79.0%, Specificity 73.0%, Accuracy 77.0%. The positive and negative predictive values were 86.6% and 61.9% respectively. (Tab. 1)

Discussion

The findings of our study showed the good efficacy of transrectal ultrasound in detecting carcinoma of

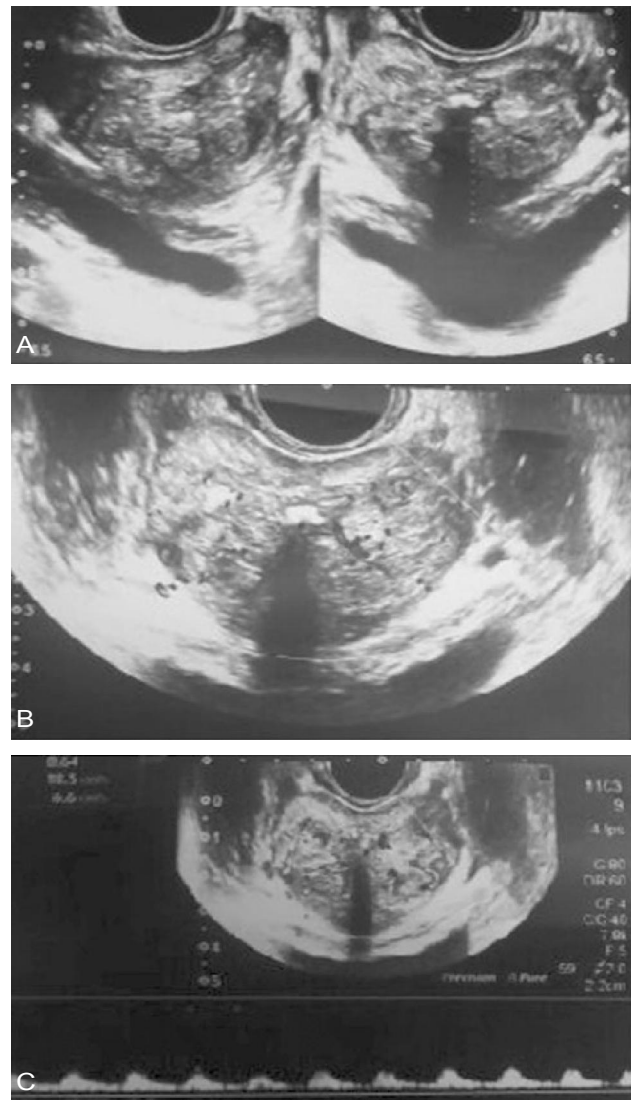


Figure 1: A 60 year old male with urinary retention. (A) Enlarged prostate gland showing heterogenous echotexture and calcification with hypo and hyperechoic nodule in peripheralzone. (B) These nodules show vascularity on color doppler. (C) The corresponding hypoechoic nodule showing arterial flow on pulse doppler.

CT Lymph Node	Histopathology		
	Positive	Negative	Total
Positive	162 (True +ve)	25 (False +ve)	187
Negative	43 (False -ve)	70 (True -ve)	113
Total	205	95	300
Sensitivity	79%		
Specificity	73%		
Positive Predicted Value	86.6%		
Negative Predicted Value	61.9%		
Overall Diagnostic Accuracy	73%		

Table 1: Sensitivity analysis of TRUS by histopathology (n=300 biopsies)

the prostate. Similar findings were reported by several studies.¹⁸⁻²¹ In a study between T2-weighted MRI and transrectal ultrasound for staging of prostate cancer, B-mode ultrasound demonstrates similar accuracy for depicting locally invasive disease as compared to T2 weighted MRI. The author also recommends this procedure more thoroughly when evaluating for an extracapsular extension.²¹ Another study has reported efficacy of TRUS and reported a more precise result in terms of tumor extracapsular extension with higher detection rate in patients with echographic sign of reverb ultrasound at posterior surface of prostate.²¹

In our study, all patients had a histopathological diagnosis of either carcinoma prostate with or without associated findings or any of the alternative diagnoses after the transrectal ultrasound exam. Similarly, in a comparative study of histological and ultrasonic appearances of the prostate, it was reported that in spite of the finding of a regular, well-defined ultrasonic capsule, the histological capsule was frequently either absent or correlated very poorly.¹⁷

Like our study, several recent studies has reported lower frequency of complications.^{22,23}

There are few limitations of this study. Firstly, patients with rectal ulcers, fissures, per-rectal bleeding, hemorrhoids and chronic constipation patients were not evaluated. Secondly, few of the potential patients did not give consent for TRUS.

However, there are several strengths of this study as well. Firstly, we have collaborated gray scale imaging with the color doppler ultrasound which ultimately increased the probability of detecting prostatic cancers. Secondly, our study comprised not only of focal lesions as shown by TRUS and doppler exam but it was also followed by random or sextant biopsies which have increased the yield of carcinoma prostate on biopsy that was not picked up on TRUS. In addition to this, our finding also showed the incidence of carcinoma prostate according to echogenicity of the lesion.

Hence, TRUS is an effective method used to have a direct visualization of the prostate, primarily because it is essential for imaging-guided prostate biopsies. In addition to its cost effectiveness, it is a real-time imaging technique, which is easy to handle and has the advantage of portability as well.

Future studies are recommended which investigate strategies to increase its diagnostic accuracy with

methods such as contrast-enhanced ultrasonography and elastography.²⁴

Conclusion

Color doppler ultrasound is suggested as a very important adjunct to gray-scale ultrasound as its increases the diagnostic accuracy of carcinoma prostate. Sextant biopsies are recommended following transrectal ultrasound for the ultimate diagnosis.

References

1. Haas GP, Delongchamps N, Brawley OW, Wang CY, de la Roza G. The Worldwide Epidemiology of Prostate Cancer: Perspectives from Autopsy Studies. *Can J Urol*. 2008; **15(1)**: 3866-71.
2. Deongchamps BN, Singh A, Haas GP. Epidemiology of Prostate Cancer in African: another step in the understanding of the disease? *CurrProbl Cancer*. 2007; **31(3)**: 226-36.
3. Northern Ireland Cancer Registry Cancer incidence and mortality. Belfast, UK: NICR; 2010.
4. Welsh Cancer Intelligence and Surveillance Unit Cardiff, UK: WCISU; 2010
5. ISD Online Information and Statistics Division, NHS Scotland Edinburgh, UK: ISD Scotland; 2010.
6. Office for National Statistics Registrations of cancer diagnosed in 2008, England. Series MB1 no. 39. London, UK: National Statistics; 2010.
7. Harvey CJ, Pilcher J, Richenberg J, Patel U, Frauscher F. Applications of transrectal ultrasound in prostate cancer. *Br J Radiol*. 2012; **85(1)**: S3-S17.
8. Ajzen S. Contribution of Contribution of transrectal ultrasonography-guided biopsy in the diagnosis of prostate cancer: looking backand ahead. *Radiol Bras*. 2015; **48(1)**: 7-11.

9. Hara R, Jo Y, Fujii T, Kondo N, Yokoyama T, Miyaji Y, et al. Optimal approach for prostate cancer detection as initial biopsy: prospective randomized study comparing transperineal versus transrectal systematic 12-core biopsy. *Urology*. 2008; **71**: 191-5.
10. Patel U, Rickards D. Handbook of transrectal ultrasound and biopsy of the prostate. London, UK: Martin Dunitz; 2002.
11. Patel U. The prostate and seminal vesicles. In: P Allan, G Baxter, M Weston., eds. *Clinical ultrasound*. 3rd edn. Edinburgh, UK: Churchill-Livingstone; 2011. 572-92.
12. Yacoub JH, Verma S, Moulton JS, Eggener S, Aytekin O. Imaging-guided prostate biopsy: conventional and emerging techniques. *Radiographics*. 2012; **32(3)**: 819-37.
13. Kuligowska E, Barish MA, Fenlon HM, Blake M. Predictors of prostate carcinoma: accuracy of gray-scale and color Doppler US and serum markers. *Radiology*. 2001; **220(3)**: 757-64.
14. Toi A. The prostate. In: Rumack CM, Wilson SR, Charboneau JW, editors. *Diagnostic ultrasound*. 4th ed. Philadelphia, PA: Elsevier Mosby; 2011; 392-428.
15. Pinto F, Totaro A, Calarco A, Sacco E, Volpe A, Racioppi M, et al. Imaging in prostate cancer diagnosis: present role and future perspectives. *Urol Int*. 2011; **86(4)**: 373-82.
16. Lopes PM, Sepulveda L, Ramos R, Sousa P. The role of transrectal ultrasound in the diagnosis of prostate cancer: new contributions. *Radiol Bras*. 2015; **48(1)**: 7-11.
17. Young MP, Jones DR, Griffiths GJ, Peeling WB, Roberts EE, Parkinson MC. Prostatic 'capsule' a comparative study of histological and ultrasonic appearances. *Eur Urol*. 1993; **24**: 479-82.
18. Dell'Atti L, Daniele C. Lidocaine spray administration during transrectal ultrasound guided prostate biopsy modified the discomfort and pain of the procedure: results of a randomized clinical trial. *Arch ItalUrolAndrol*. 2010; **82(2)**: 125-7.
19. Heijmink S, van Moerkerk H, Kiemeney L, Witjes JA, Frauscher F, Barentsz JO. A comparison of the diagnostic performance of systematic versus ultrasound-guided biopsies of prostate cancer. *EurRadiol*. 2006; **16(4)**: 927-38.
20. Jung AJ, Coakley FV, Shinohara K, Carroll PR, Carroll PR, Kurhanewicz J, et al. Local staging of prostate cancer: comparative accuracy of T2-weighted endorectal MR imaging and transrectal ultrasound. *Clin Imaging*. 2012; **36(5)**: 547-52.
21. Dellatti L. Role of transrectal ultrasound in the diagnosis of extracapsular prostate cancer. *J Ultrasound*. 2014; **17(1)**: 47-51.
22. Solha RS, Ajzen S, De Nicola H, et al. Morbidade da biópsia da próstata trans retal guiada por ultrassonografia. *Radiol Bras*. 2013; **46**: 71-4.
23. Tyng CJ, Maciel MJS, Moreira BL, et al. Preparo e manejo de complicações em biópsias de próstata. *Radiol Bras*. 2013; **46**: 367-71.
24. Pinto F, Totaro A, Calarco A, Sacco E, Volpe A, Racioppi M, et al. Imaging in prostate cancer diagnosis: present role and future perspectives. *Urol Int*. 2011; **86**: 373-82.