

# INFECTED URACHAL CYST PRESENTING AS AN ACUTE ABDOMEN – A CASE REPORT

Azra Laghari,<sup>1</sup> Navaid Ahmad<sup>2</sup>

<sup>1</sup> Atomic Energy Medical Centre (AEMC), JPMC, Karachi, Pakistan.

<sup>2</sup> Department of Radiology, Jinnah Post Graduate Medical Centre (JPMC), Karachi, Pakistan.

PJR July - September 2016; 26(3): 228-231

## ABSTRACT

The urachus, or median umbilical ligament, is a midline tubular structure that extends upward from the anterior dome of the bladder toward the umbilicus. Urachal tract remnants that abnormally remain patent are often subject to infection. Furthermore, these infected remnants are frequently confused with a wide spectrum of midline intra abdominal or pelvic inflammatory disorders at clinical examination. Imaging plays an important role in the diagnosis. We report a case of 8 year old boy who presented with lower abdominal pain. Diagnosis of infected urachal cyst was made on CT scan which was proven on histopathology.

**Key words:** urachus, urachal cyst, computed tomography.

## Introduction

The urachus is an embryologic remnant which is formed by the obliteration of the allantois and cloaca. This fibrous tubular structure is located in the midline and extends from the apex of the bladder to the umbilicus. The urachal abnormalities are caused by the defective obliteration of the urachus. An infected urachal cyst is one of a spectrum of presentations of urachal pathology. Patients tend to present in a heterogeneous fashion, making diagnosis difficult.<sup>1</sup> Delay in treatment may have serious consequences as complications include sepsis, fistula formation, and rupture leading to peritonitis.<sup>2</sup> We present a case of an infected urachal cyst presenting as an acute abdomen in an eight year old boy.

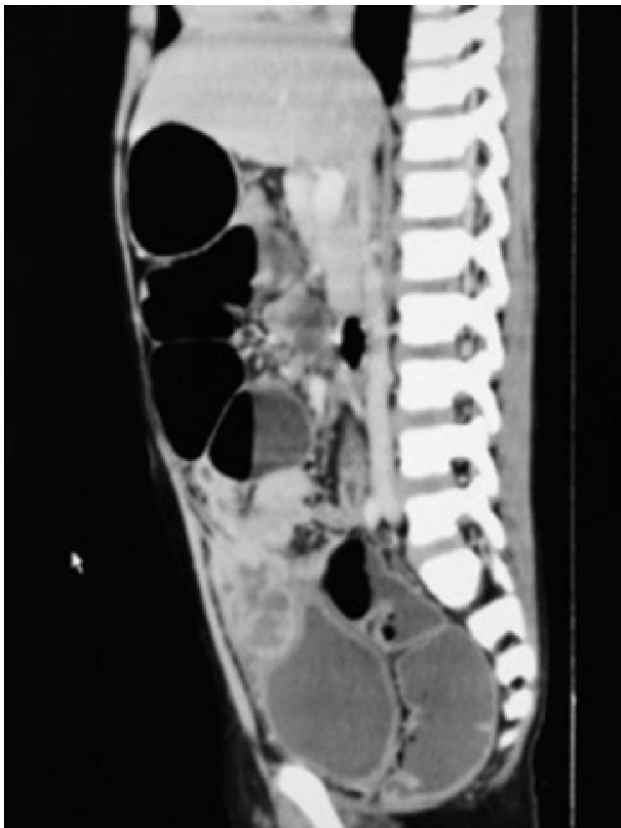
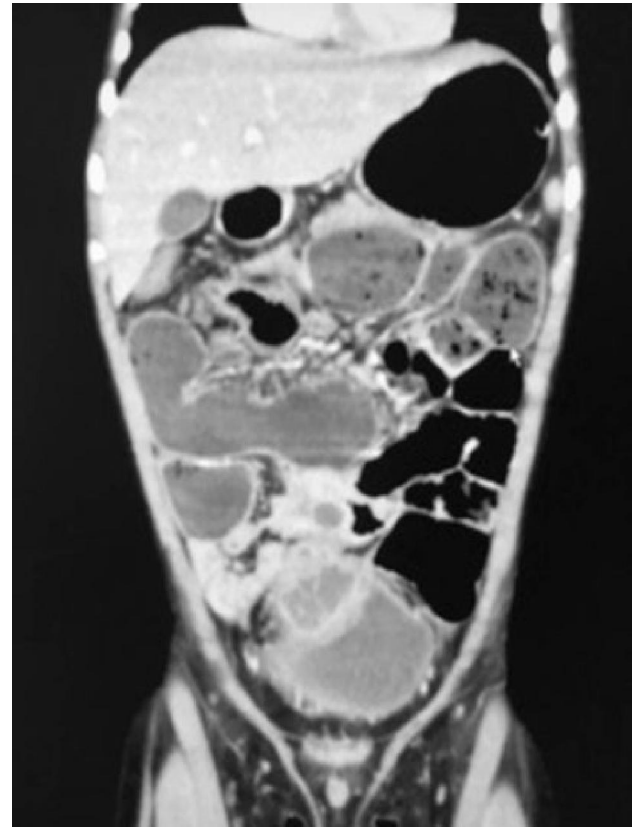
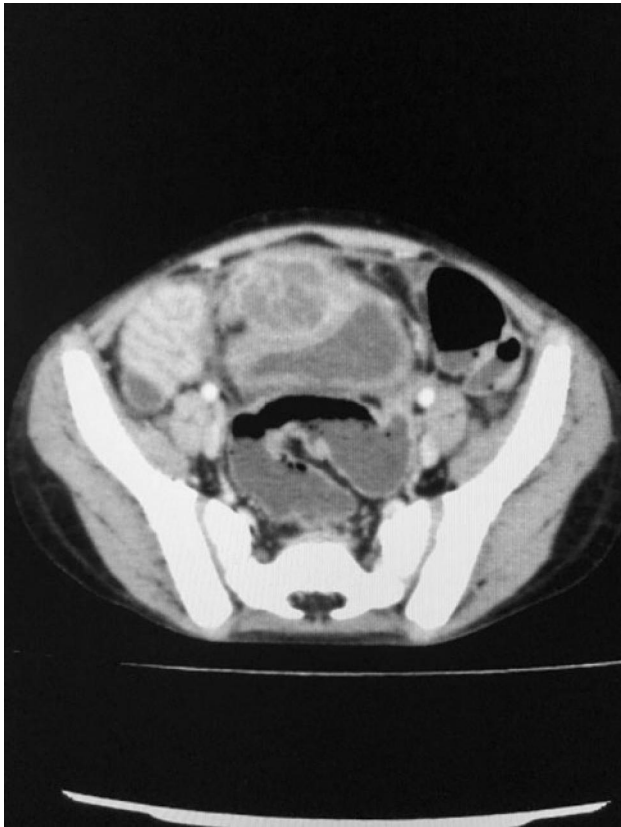
## Case Report

An eight year boy presented to the emergency department without prior relevant medical history, with lower

abdominal pain. The character of the pain was intense and persistent, accompanied with fever and vomiting. On examination patient was tender in the umbilical and hypogastric regions. Laboratory data revealed leucocytosis with 82% neutrophil predominance and a white blood cell count of 13,000/L. Patient was brought to radiology department for CT scan. CT scan demonstrated a multi loculated cystic mass in the hypogastrium in midline beneath the rectus sheath (Fig. 1). It showed thick enhancing walls and septa. No evidence of air or calcification was seen in the mass. It was inseparable from surrounding distal small bowel loops. It approximately measured 2.9 x 2.3 x 4.0 cm in axial and craniocaudal dimensions. Posteroinferiorly it appeared to be compressing the dome of urinary bladder without evidence of any communication with it. Superiorly it appeared to be connected with the umbilicus through a small narrow stalk of soft tissue density. Furthermore there was associated mesenteric fat stranding and multiple sub-

**Correspondence :** Dr. Azra Laghari  
Atomic Energy Medical Centre (AEMC),  
(JPMC), Karachi, Pakistan.  
Email: azralaghari@gmail.com

Submitted 17 November 2015, Accepted 28 December 2015



**Figure 1:** Contrast CT in axial (a), sagittal (b) and coronal (c) planes showing a multi-loculated cystic lesion anterosuperior to the urinary bladder. It is causing compression effect over dome of urinary bladder. Proximal small bowel loops are dilated. A small narrow stalk of soft tissue density is clearly visualized on sagittal image extending between the lesion and the umbilicus.

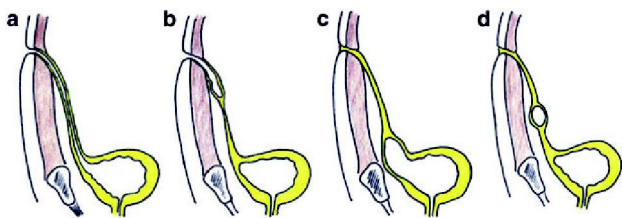
centimeter mesenteric lymph nodes. The proximal small bowel loops were dilated. Distal small bowel loops appeared collapsed. The large bowel appeared normal. A diagnosis of infected urachal cyst with involvement of pelvic small bowel loops was made on the basis of above findings. A treatment with antibiotics was started before the surgery. Laparotomy was performed by a paediatric surgeon. An extra-peritoneal cystic mass was mobilized and excised. Postoperative course of the patient was uneventful. Histopathology confirmed the radiological diagnosis of infected urachal cyst.

## Discussion

The urachus, or median umbilical ligament, is a midline tubular structure that extends upward from

the anterior dome of the bladder toward the umbilicus. It is a vestigial remnant of at least two embryonic structures: the cloaca, which is the cephalic extension of the urogenital sinus (a precursor of the fetal bladder), and the allantois, which is a derivative of the yolk sac.<sup>3</sup> Descent of the bladder from the 5<sup>th</sup> month of development into the foetal pelvis pulls the urachus with it resulting in the formation of the urachal canal. This canal progressively obliterates during foetal life, forming a fibrous tract in early adult life with no function. At the end of development, the urachus lies between the transverse fascia anteriorly and the peritoneum posteriorly (space of Retzius), surrounded by loose areolar tissue attaching the umbilicus to the bladder dome, being 3-10 cm in length and 8-10 mm in diameter.<sup>4</sup>

Histologically, it is composed of 3 layers; an innermost layer of modified transitional epithelium similar to urothelium, a middle fibroconnective tissue layer and an outer layer of smooth muscle continuous with the detrusor. Congenital anomalies occur when the urachus fails to obliterate. The pathology associated with congenital disorders of urachus is generally divided into four categories (Fig. 2)<sup>5</sup>. The first (a) is a patent urachus in which a communication between the bladder and the umbilicus exists. The next category (b) pertains to the umbilical sinus, in which the urachus opens into the umbilicus. Here, drainage from the umbilicus will often be present. The third category (c) is the vesico-urachal diverticulum, in which the urachus has a wide patent opening into the bladder. Urinary complaints are often cited with this type. The last category (d) is the urachal cyst, in which the urachus encompasses a cyst like structure within its length; this last disease state, the urachal cyst, becomes prominent when infection occurs or ruptures of the cyst.<sup>6,7</sup>



**Figure 2:** 4 Types of urachal anomalies: (a) patent urachus, (b) urachal sinus, (c) urachal diverticulum, (d) urachal cyst

Patients with infected urachal cysts can present with a wide range of symptoms, most commonly abdominal


pain, fever, umbilical discharge and the feeling of a midline mass. Owing to the low incidence and heterogeneous presentation patients can be misdiagnosed.<sup>8</sup> Complications of infection include sepsis, fistula formation, and rupture leading to peritonitis. Necrotizing fasciitis has also been reported as a rare complication of an infected urachal cyst.<sup>9</sup>

Because of the nature of the condition radiographic evaluation of urachal cyst by ultrasound, CT and/or MRI is essential for confirming diagnosis of urachal cyst or abscess. Abdominal tomography (CT) can accurately detect the pyo urachus which shows a mass located deep to the rectus abdominis between the bladder and the umbilicus with a conical shape, peripheral inflammatory changes in the surrounding tissues, and intraperitoneal fluid.<sup>10</sup>

In conclusion infected urachal cyst should be considered as a rare differential diagnosis for abdominal pain in children because its presence cannot be ruled out by physical examination only. The diagnosis is mainly clinical; however, radiological investigations such as CT scan play an important role. Due to its ability of multi-planar reconstruction, CT not only helps in diagnosis but also defines the surrounding anatomical relationship.

## References

1. Ashley RA, Inman BA, Routh JC, Rohlinger AL, Husmann DA, Kramer SA. Urachal anomalies: a longitudinal study of urachal remnants in children and adults. *J Urol.* 2007 Oct; **178(4 Pt 2)**:1615-8.
2. Ekwueme KC, Parr NJ. Infected urachal cyst in an adult: a case report and review of the literature. *Cases J.* Jun 2009; **2**: 6422.
3. Moore KL. The urogenital system. In: Moore KL, editor. *The developing human.* Philadelphia: Pa: Saunders; 1982; p. 255-297.
4. Qureshi K, Maskell D, McMillan C, Wijewardena C. An infected urachal cyst presenting as an acute abdomen—a case report *Int J Surg Case Rep.* 2013; **4(7)**: 633-5.

- 
- 
5. Tazi F1, Ahsaini M, Khalouk A, et al. Abscess of urachal remnants presenting with acute abdomen: a case series. *J Med Case Rep.* 2012 Jul 30; **6**: 226.
  6. Yu JS, Kim KW, Lee HJ, Lee YJ, Yoon CS, Kim MJ: Urachal remnant diseases: Spectrum of CT and US findings. *Radiographics.* Mar-Apr 2001; **21(2)**: 451-61.
  7. Avni EF, Matos C, Diard F, Schulman CC: Midline omphalovesical anomalies in children: contribution of ultrasound. *Urol Radiol.* 1988; **10(4)**: 189-94.
  8. Ash A, Gujral R, Raio C. Infected urachal cyst initially misdiagnosed as an incarcerated umbilical hernia. *J Emerg Med.* 2012 Feb; **42(2)**: 171-3.
  9. Testerman GM. Necrotizing fasciitis due to an infected urachal cyst in an adult. *South Med J.* Oct 2010; **103(10)**: 1066-7.
  10. Herman TE, Shackelford GD. Pyourachus: CT manifestations. *J Comput Assist Tomogr.* 1995 May-Jun; **19(3)**: 440-3.