

# MULTI-VISCERAL FISTULA FOLLOWING CESAREAN SECTION

Saba Sohail, Rabia Hafeez

Department of Radiology, Dow Medical College/Civil Hospital (DUHS), Karachi, Pakistan.

PJR January - March 2017; 27(1): 60-62

## ABSTRACT

A young married second para lady with known valvular heart disease and hepatitis C, presented with foul smelling pus- discharging sinus from previous cesarean section scar and fever since 20 days. X-ray sinogram was asked which showed complex fistula communicating with distal ileal loops and uterine cavity. Exploratory laparotomy showed an infected retained surgical swab, and uterine perforation along with gangrene of the descending colon and ileum. The foreign body was removed with gut resection and ileostomy. The postoperative course was marked by one episode of wound dehiscence. Distal loopogram after 6 months showed healed bowel loops without any fistulous communication. Ileostomy was then reversed and patient was discharged in stable state with advice for cardiology and hepatology referrals.

**Key words:** Abdominal wall sinus, retained gauze, bowel gangrene, complex fistula, cesarean section, complication.

## Introduction

Cesarean section often results in many complications including urogenital fistulae usually involving bladder and vagina, and rarely vesico-uterine fistulae.<sup>1</sup> Bowel injuries have been reported following induced abortion,<sup>2</sup> although complex fistula formation between bowel and genital tract following planned cesarean section has never been reported to the best of author's knowledge. We present a rare case of complex fistula formation between bowel and uterus following infection due to retained gauze piece after cesarean section in a young woman.

## Case Report

A 26-year old female patient presented to the out patient department Civil hospital Karachi with complain of foul smelling pus-discharging sinus from the site of previous caesarian section scar done two months back, fever for last 15 days and foul smelling vaginal

discharge last 15 days. She was a second para and known case of valvular heart disease and hepatitis C. On physical examination, she was found to be febrile with temp 100°F; blood pressure, pulse and rest of vitals were normal. On auscultation murmur was heard over precordium. Local examination showed a discharging sinus at the site of previous cesarean section scar measuring 1cm with excoriated skin. She was referred to Radiology department for x-ray sinogram.

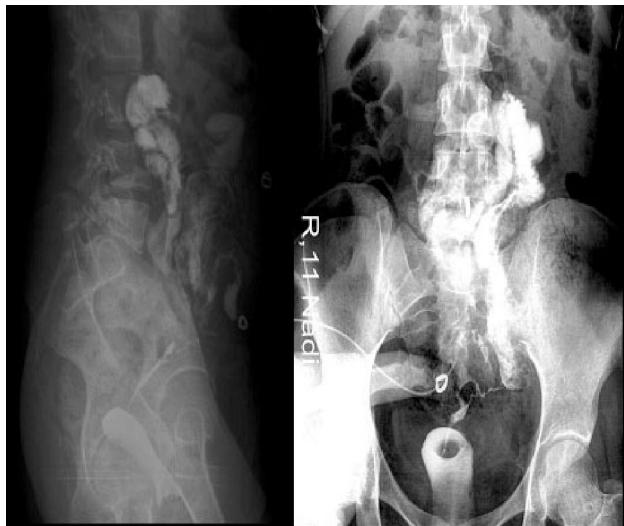She was given contrast though sinus opening located at suprapubic region 4 cm below umbilicus. Sinogram revealed complex fistula communicating with distal illeal loops and uterine cavity (Fig. 1).

She subsequently underwent exploratory laparotomy. Peroperatively an infected swab was found at site of large intestine and uterine scar on left side, which was removed. Uterine perforation was identified at the level of uterine scar line along with gangrene of descending colon and ileum. The gangrenous part

**Correspondence** : Dr. Saba Sohail  
Department of Radiology,  
Dow Medical College/Civil Hospital (DUHS),  
Karachi, Pakistan.  
Email: drsabasohail@hotmail.com

Submitted 25 August 2016, Accepted 25 October 2016

of descending colon was removed and primary anastomosis of bowel was done. The gangrenous part of ileum was also dissected and ileostomy made.



**Figure 1:** X-ray fistulogram AP and lateral views showing complex fistula between bowels and uterus with air in uterus.

Postoperatively, she was admitted in surgical ward with one episode of wound dehiscence which was managed and she was discharged after one week. She returned after six months for distal loopogram which was normal. She underwent ileostomy reversal and was discharged in stable state with advice for cardio-logy and hepatology referrals.


## Discussion

While complications posed by retained foreign bodies during surgery are not infrequent, this case is unique in terms of extent of fistula formation, the multiplicity of organs involved and the exteriorization of the lesion. Retained foreign bodies added to the specific complication of cesarean surgery. It was a planned, not an emergent surgery and it did not follow a prolonged labor. Fistula formation follows obstetric trauma be it a prolonged labor, cesarean section or even IUCD migrated to extra-uterine intra-abdominal locations.<sup>1-3</sup> However these mostly involve the urinary tract. Bowel fistula usually represent a complication of Crohn's disease,<sup>5</sup> but have been reported following endometriosis surgery.<sup>6</sup> Nevertheless the extensive fistula that involved a per-

forated or more likely a possible broken uterine scar and the extensive small intestine gangrene which tracked out through the anterior abdominal wall is not described earlier in English literature at least. The post operative course was therefore eventful and required multidisciplinary care involving the gynecological as well as general surgical care. There was an episode of wound dehiscence. Presence of wound is an important factor in the development of wound dehiscence and burst abdomen which constitutes significant morbidity and mortality among patients undergoing laparotomy.<sup>7</sup> This patient had the background set for this complication but fortunately she survived this catastrophic complication despite her co morbidities of congenital mitral valve stenosis and acquired HCV infection. She was successfully managed with surgery and after six months underwent a successful ileostomy reversal when the symptomatology had improved and imaging had testified the healing of the original wound.

## References

1. Tahir N, Afzal B, Kayan S. Vesico-uterine fistula - a complication of caesarian section. *Pak Armed Forces Med J* 2007; **57**: 230-2.
2. Rehman A, Fatima S, Gangat S, Ahmed A, Memon IA, Soomro N. Bowel injuries secondary to induced abortion; a dilemma. *Pak J Surg* 2007; **23**: 122-5.
3. Adiyeka M, Sausi M, Karaca I, Goku M, Toz E. Surgical management of intrauterine devices migrated towards intra-abdominal structures; 20 year experience of tertiary centre. *Clic Exp Obstet Gynaecol* 2015; **42**: 358-60.
4. Khan HS, Malik AA, Ali S, Naeem A. Gossypiboma as a cause of intestinal obstruction. *J Coll Physicians Surg Pak* 2014; **24(3)**: S188-9.
5. Dharamshi HA, Ali AAM, Raza T, Shahid N, Sheraz F, Sajid T, et al. multiple Entero-enteric fistulas - Crohn's disease - a case report. *Iran J Public Health* 2015; **44**: 1550-2.

- 
- 
6. Oliveira MA, Poreira TR, Gilbert A, Tulandi T, de Oliveir HC, Dewilde RL. bowel complications in endometriosis surgery. *Best Pract Res Clin Obstet Gynaecol* 2015; pii: S1521-6934 (15) 00203-5.
  7. Ali A, Saeeda, Israr M, Naimatullah H. Frequency of abdominal wound dehiscence and role of wound infection as a major causative factor. *Pak J Surg* 2014; **30(1)**: 4-8.