

SOLITARY RECTAL ULCER MIMICKING RECTAL CARCINOMA ON IMAGING

Javerya Sattar,¹ Saba Sohail,¹ Nasreen Naz,¹ Amjad Siraj Memon²

¹ Department of Radiology, Dow Medical College/Civil Hospital (DUHS), Karachi, Pakistan.

² Department of Surgery, Dow Medical College/Civil Hospital (DUHS), Karachi, Pakistan.

PJR January - March 2017; 27(1): 44-46

ABSTRACT

A 37-year lady presented with pain, per rectal bleeding and altered bowel habits. She was suspected to have a rectal growth on colonoscopy, contrast enhanced CT scan and MRI. However the CEA levels were normal and histopathology showed a solitary rectal ulcer. The report highlights the importance of this benign condition as confounding for rectal malignancy.

Keywords: Solitary Rectal Ulcer, Carcinoma rectum, MRI , CT scan, rectal wall thickening, CEA levels.

Introduction

Solitary rectal ulcer syndrome (SRUS) is a rare and benign entity usually misdiagnosed as rectal malignancy. It shows broad spectrum of clinicopathological abnormalities.¹ The diagnosis of SRUS depends on clinical features, proctosigmoidoscopy, biopsy and histopathology, defecating proctography, dynamic magnetic resonance imaging, manometry and electromyography. However histopathology is gold standard.

The radiological appearance of solitary rectal ulcer mimicks rectal malignancy both on MRI and contrast enhanced CT scan. The predilection of SRUS is in the anterior wall of the rectum,³ therefore mucosal thickening of anterior wall of rectum under relevant clinical context should raise a possibility of SRUS in the differentials which is the purpose of reporting this case.

Case Report

A 37-year married lady presented with complain of abdominal pain, per rectal bleed and altered bowel

habits for 4 months. The rest of the history and general and systemic examination was unremarkable. On digital rectal examination growth was palpable about 5 cm away from anal verge with normal anal tone. Colonoscopy shows rectal growth approximately 3 cm away from anal verge (Fig. 1). Biopsies were taken and sent for histopathology. Meanwhile, she was

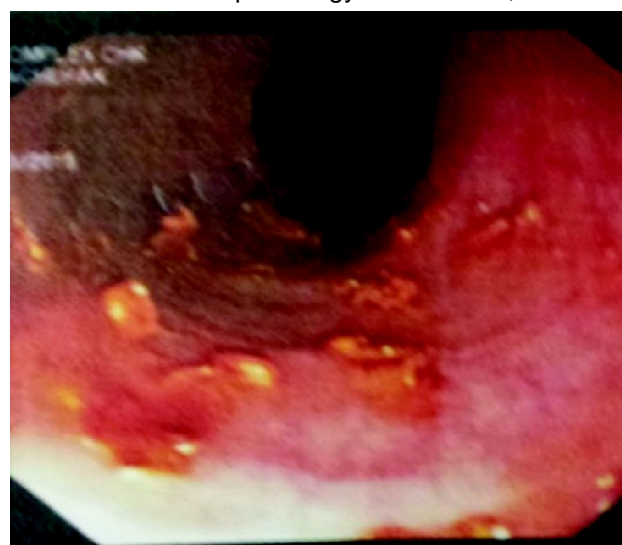


Figure 1: Colonoscopy findings in patient show a rectal growth at 3 cm from anal canal.

Correspondence : Dr. Javerya Sattar
Department of Radiology,
Dow Medical College/Civil Hospital (DUHS),
Karachi, Pakistan.
Email: jsattar99@yahoo.com

Submitted 18 August 2016, Accepted 18 October 2016

referred to our department for contrast enhanced CT scan of abdomen and pelvis. It demonstrated an irregular solid thickening involving anterolateral wall of mid to distal rectum for a length of 3 cm, ending 3 cm away from the anal verge. It was concluded as a possible rectal malignancy in the light of clinical scenario (Fig. 2a and b). MRI pelvis performed in another hospital, showed diffuse eccentric thickening of anal canal, anterior as well as right lateral rectal wall thickening which corroborated the CT findings with same possible diagnosis (Fig. 3). Defecation proctography performed showed short segment of smooth narrowing at mid rectum along with subtle mucosal irregularity. Her Carcino embryonic antigen (CEA) levels were within normal limits. The histopathology reported the lesion as "solitary rectal ulcer" without any evidence of malignancy, and the patient was managed conservatively.

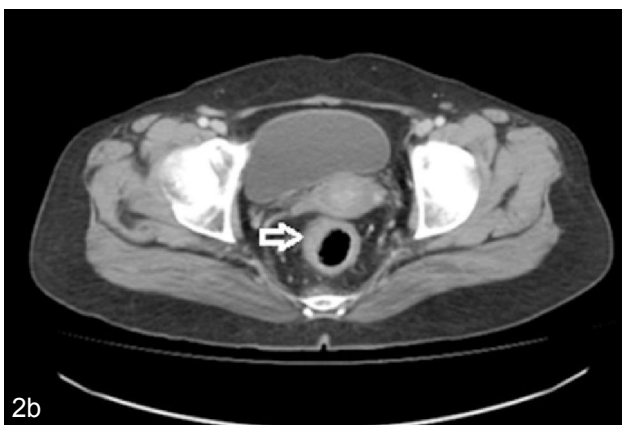
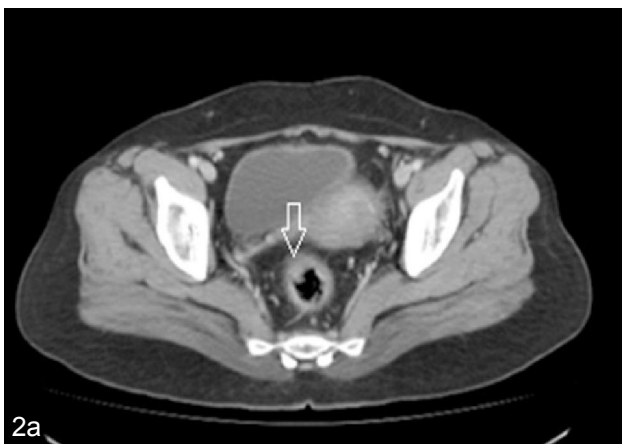

Figure 2a and b: Contrast enhanced CT scan showing lesion in anterior wall (thin arrow) and right lateral wall (thick arrow) of the rectum

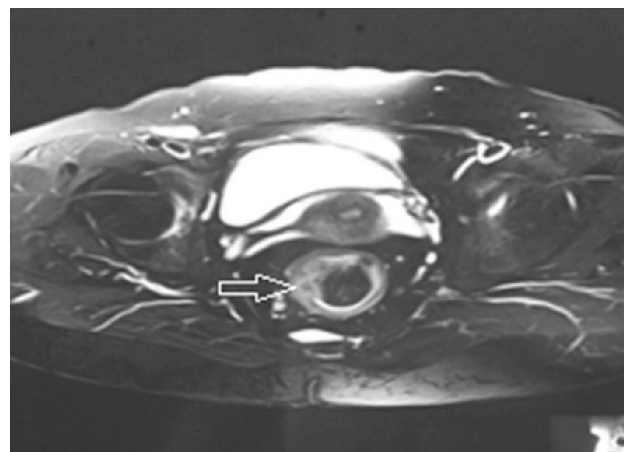


Figure 3: MRI appearance of the lesion (arrow)

Discussion

Solitary rectal ulcer is usually underdiagnosed. There is not much local literature available regarding this benign condition. A recent case series from Pakistan showed it is more prevalent in young adults with no significant gender difference.² However cases have been reported in children as well as adults after 4th decade. In this local case series the commonest presentation was bleeding per rectum which was similar in this patient. Clinically patients can present with any combination of the symptoms like lower abdominal pain, per rectal bleed, mucous discharge, sense of incomplete evacuation, constipation, excessive straining and rectal prolapse.³

Solitary rectal ulcer is considered as misnomer. On colonoscopy findings range from mucosal erythema, single or multiple ulcers, polypoidal lesion⁴ and can even appear as thickened mucosa and stricture mimicking malignant lesion.⁵ This case was also reported as a mass lesion on proctoscopy. Histopathology is considered the gold standard in differentiating from other pathologies including malignancy⁶ and inflammatory bowel diseases.

Other imaging modalities like magnetic resonance imaging, endoanal ultrasonography and defecation proctography are also performed to aid in evaluation of underlying pathology.

First line treatment include conservative management. It includes patient education, avoidance of straining, use of laxatives, high fibre diet and biofeedback. Surgery is considered if there is no improvement.

Mucosal resection or perineal proctectomy in cases with external prolapse while resection and rectopexy in cases with internal prolapse.

Diagnosis of solitary rectal ulcer should be considered in the differential diagnosis of rectal malignancy in order to institute early conservative management and to avoid unnecessary abdominoperineal surgery. The unique features of the presently reported case are its occurrence in an adult lady (rather than a young adult), location along anterolateral (rather only anterior) wall, extensive pararectal and soft tissue spread with involvement of mesorectal fascia and the positive looking enlarged lymph nodes in pelvis. Only the tumor marker levels were normal and histopathology was decisive in establishing the benign nature of this very aggressive looking lesion on imaging.

References

1. Amaechi I, Papagrigoriadis S, Hizbullah S, Ryan S. Solitary rectal ulcer syndrome mimicking rectal neoplasm on MRI. *Br J Radiol.* 2010; **83**: e221-4.
2. Abbasi A, Bhutto AR, Taj A, Baloch AA, Masroor M and Munir SM. Solitary Rectal Ulcer Syndrome: demographic, clinical, endoscopic and histological panorama. *Coll Physicians Surg Pak* 2015; **25**: 867-9.
3. Zhu QC, Shen RR, Qin HL, Wang Y. Solitary rectal ulcer syndrome: clinical features, pathophysiology, diagnosis and treatment strategies. *World J Gastroenterol* 2014; **20**: 738-44.
4. Wijffels NA, Chambers W. Solitary Rectal Ulcer Syndrome and obstructed defecation: Common Pathology. *Pelvic Floor Disorders: Surgical Approach*: Springer; 2014. p. 103-10.
5. Geramizadeh B, Baghernezhad M, Afsher AJ. Solitary rectal ulcer: a literature review. *Annals of Colorectal Research* 2015; **3(4)**: e33500
6. Baskonus I, Maralcan G, Gokalp A, Sanal I. Solitary rectal ulcer syndrome: an unusual cause of rectal stricture. Case report. *Chirurgia Italiana* 2000; **53**: 563-6.
7. Dehghani SM, Malekpour A, Haghghat M. Solitary rectal ulcer syndrome in children: a literature review. *World J Gastroenterol* 2012; **18**: 6541-5.