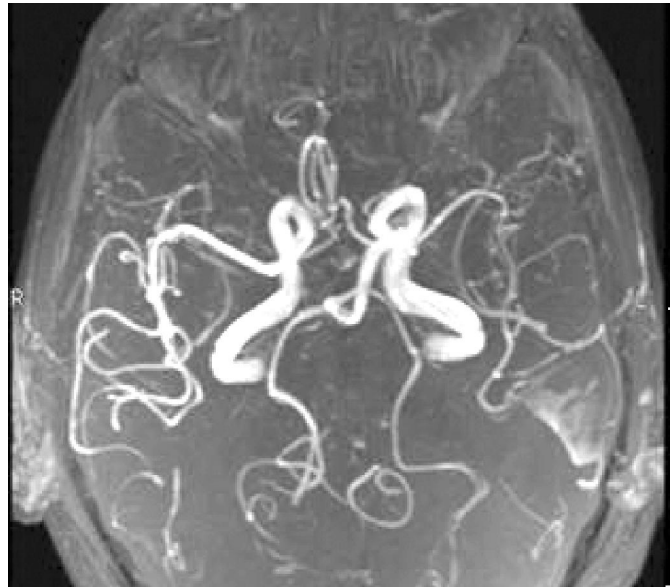


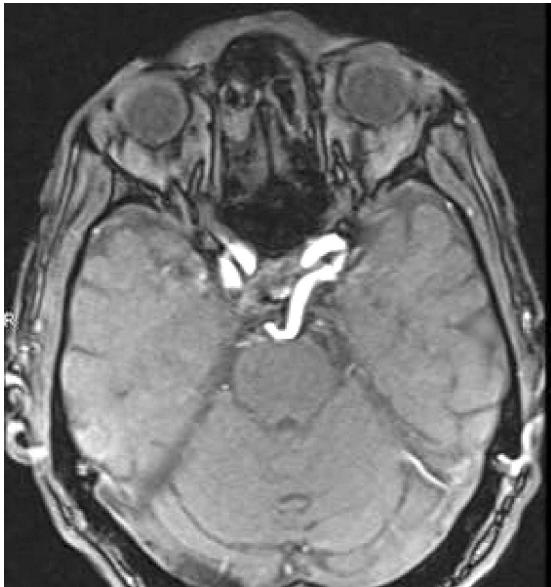QUIZ 1

Muhammad Shahbaz Alam, Zahid Anwar Khan

Department of Radiology, Aga Khan University Hospital, Karachi, Pakistan.

PJR January - March 2011; 21(1): 46-47



Question _____

- Q1. What is the normal variant on this MRA examination?
- Q2. Is there any clinical significance of this vascular variant?

QUIZ 1

Answers

Answer 1: This is persistent trigeminal artery arising from cavernous portion of left ICA and communicating with Basilar artery. Proximal Basilar artery is hypoplastic.

Answer 2: Clinically important because transphenoidal surgery for pituitary adenoma is dangerous in patients who have this variant.

Discussion

Persistent trigeminal artery is not very uncommon and incidence is up to 0.6% in large angiography series. It has two types, lateral and medial. Lateral type arises from the precavernous portion of ICA and courses posterolaterally and anastomose with mid basilar artery. Medial type arises from precavernous ICA and courses posteromedially and compresses the pituitary gland, pierces dorsum sella and anastomose with midbasilar artery.

References

1. Ucinho A, Sawada A, Takase Y, Kudo S. MR Angiography of anomalous branches of internal carotid artery. *AJR* 2003; **181**: 1409-14
2. Luh GY, Dean BL, Tomsick TA, Wallace RC. The persistent fetal carotid–vertebrobasilar anastomoses. *AJR* 1999; **172**: 1427-32
3. Saltzman G. Patent primitive trigeminal artery studied by cerebral angiography. *Acta Radiol* 1959; **51**: 329-36