

UTERINE ARTERY EMBOLIZATION FOR THE TREATMENT OF UTERINE FIBROIDS: INITIAL EXPERIENCE

Imaad ur Rehman, Tanveer ul Haq, Rana Shoaib Hamid, Muhammad Azeemuddin, Waseem Akhtar, Darakhshan Kanwal

Department of Radiology, Aga Khan University Hospital, Karachi, Pakistan.

PJR January - March 2011; 21(1): 01-05

ABSTRACT

PURPOSE: To evaluate the initial results of uterine artery embolization for the treatment of symptomatic uterine fibroids in our local population. **MATERIALS AND METHODS:** Medical records and radiological images of all patients undergoing uterine artery embolization (UAE) in Aga Khan University Hospital (AKUH) between January 2003 and December 2009 were retrospectively analyzed. Fourteen patients (Age range: 19-50 years) with sonographic diagnosis of uterine fibroids associated with menorrhagia and/or pelvic pain underwent uterine artery embolization with use of polyvinyl alcohol (PVA) particles. Single femoral access technique was used in all patients. Clinical improvement was assessed by detailed questionnaire for symptomatic improvement and follow up ultrasounds. **RESULTS:** All 14 patients underwent technically successful embolization. Five patients were lost to follow up and were not included in the final analysis. Out of remaining 9 patients, eight patients had initially presented with menorrhagia with pelvic pain while one patient had presented with menorrhagia alone. On follow up after one year menorrhagia was significantly reduced in 7 out of 9 patients (77%). Pelvic pain was improved in 7 out of 8 patients (89%). Majority of patients experienced post procedure pain of various intensities which was treated conservatively. One patient developed scanty periods, a known complication of this procedure. No other procedure related significant complications were seen. **CONCLUSION:** Uterine fibroid embolization represents a promising method of treating fibroid-related menorrhagia and pelvic pain. Further studies with larger patient population will be required for definitive results.

Keywords: Fibroids, Uterine artery embolization, Menorrhagia, Pelvic pain.

Introduction

Uterine fibroids are the most common benign tumors of the female pelvis and the leading indication for abdominal hysterectomy. Embryologically, they are of Mullerian duct origin, composed of smooth muscle and fibrous connective tissue, and are present in 25–50% of women older than 40 years.¹⁻³

Present guidelines for treatment of fibroids recommend that only symptomatic fibroids or those with rapid growth should be treated. Currently available options for treatment of fibroids include non-surgical as well as surgical procedures.

For those patients who have completed their family,

definitive treatment is hysterectomy. However, it has certain drawbacks including risk of infection and morbidity. The risk of mortality associated with hysterectomy done for benign indications is 1/1000 procedures.⁴ For patients who wish to preserve their uterus the treatment must be conservative, either medical or surgical. Gonadotrophin releasing hormone (GnRH) analogues are effective in reducing size and symptoms associated with fibroids, but the side effects prevent their long-term use. Myomectomy preserves reproductive function but has increased incidence of recurrence of symptoms requiring further surgical intervention.

In 1995, Ravina et al. proposed uterine artery embolization (UAE) as an alternative to surgical treatment of uterine fibroids. It is a relatively newer,

Correspondence : Dr. Tanveer ul Haq
Department of Radiology,
Aga Khan University Hospital,
Stadium Road, P.O. Box 3500, Karachi 74800
Pakistan. Tel. No: 34930051 - Ext. 2020
E-mail: tanveer.haq@aku.edu

nonsurgical treatment option for premenopausal women with fibroid-related symptoms who wish to retain their uterus, avoid side effects associated with prolonged medical therapy, and are reluctant to undergo surgery. The hypothesis behind this procedure is that bilateral reduction of uterine arterial blood flow results in infarction of fibroids and control fibroid-related symptoms.^{5,6}

Many studies have been done in the west for determining the efficacy of UAE and have shown promising results.⁷⁻⁹ This procedure is also being done in Pakistan in limited centers for a few years but no data has yet been published indicating its success or failure in our Pakistani population. The purpose of this study is to evaluate the results and outcome of this procedure in our local population.

Materials and Methods

2.1 Patient selection and assessment:

Through online radiology database 14 patients (Age range: 19-50 years) were identified who had undergone UAE between January 2003 and December 2009 for menorrhagia and / or pain attributable to fibroids. Indications to UAE included: heavy menstrual bleeding (n=9) and or pelvic pain (n=8) associated with fibroids. All women were premenopausal and had been evaluated by a gynecologist including a medical history, physical examination and laboratory studies. The diagnosis of fibroids was confirmed by pelvic ultrasound. Clinical assessment was made by a detailed questionnaire for assessment of symptomatic improvement post UAE. Patients (n=5) who were lost to follow up were excluded from the final analysis.

2.2 Embolization Procedure:

Pre procedure evaluation included complete blood count, PT, APTT, INR and serum creatinine. Before the procedure, all patients were administered broad spectrum antibiotics prophylactically and continued antibiotics for 5 to 7 days after procedure. All procedures were performed by senior interventional radiologists in angiography suite on a monoplane flat panel DSA unit (Axiom Artis angiography machine, Seimen's corporation). Single femoral access technique was

used in all patients. Pre embolization angiographic runs were performed in all patients.

After placing a 5 Fr vascular access sheath, a 5 Fr C1 catheter (Cordis corporation) was advanced over hydrophilic guide wire (Terumo Medical corporation) into bilateral internal iliac arteries and diagnostic pelvic angiography was carried out. Subsequently a Progreat micro catheter (Terumo Medical Corporation) was placed in uterine arteries by co axial technique and 200-350 μ m Polyvinyl alcohol (PVA) particles (Boston Scientific) were slowly infused. Cessation of flow in uterine arteries was considered as the end point of procedure (Fig. 1).

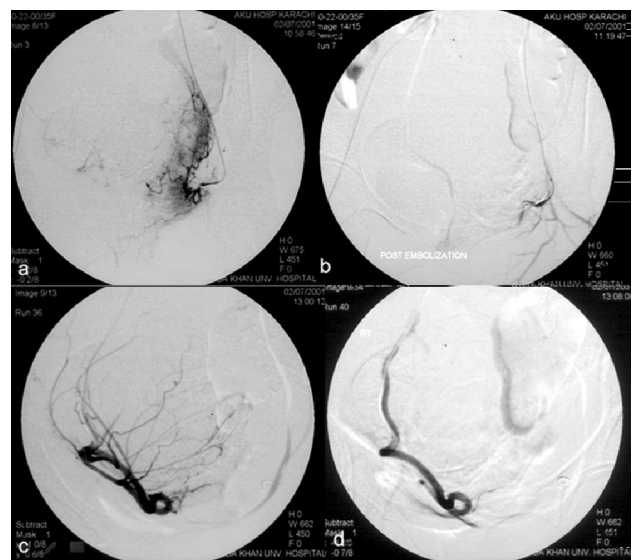


Figure 1: Bilateral uterine artery embolization in patient with a large uterine fibroid. Pre embolization angiograms of left (a) and right (c) uterine arteries show abnormal vascular supply to the large uterine fibroid. Post embolization angiograms of left (b) and right (d) uterine arteries show cessation of contrast in right and left uterine arteries due to occlusion by PVA particles.

During procedure if patient complained of pain injection Fantanyl was administered. After the procedure, hemostasis was achieved by manual compression. Most patients reported post procedure pain which was managed with continuous parenteral administration of Flurbiprofen, narcotics and antiemetics. Patients were kept in hospital for 2 to 3 days for observation and pain management and discharged once their clinical condition was satisfactory.

Follow Up:

All patients were advised to have clinical and sonographic follow up one year after UAE. Compliance

of patients regarding follow up, however, was sub-optimal and five patients were lost to follow up. Follow up results of rest of the patients were recorded in a Performa which contained a standard set of questions used to evaluate the clinical effectiveness of the procedure and follow up ultrasound results.

Results

All 14 patients had technically successful embolization. Eleven patients had undergone bilateral uterine artery embolization, while 3 had undergone unilateral UAE. Majority of patients experienced post procedure pain of various intensities which was treated conservatively. There were no significant procedural complications. Clinical follow up was available in 9 out of 14 patients. Out of these 9 patients, eight patients had initially presented with menorrhagia with pelvic pain while one patient had presented with menorrhagia alone. On clinical follow up after one year, menorrhagia was significantly reduced in 7 out of 9 patients (77%). Pelvic pain was improved in 7 out of 8 patients (89%). The results were assessed either as success or failure by improvement in course of symptoms based upon clinical follow up and reduction in fibroid size based upon sonographic assessment. (Tab.1).

Case	Age (years)	Symptoms	Course
1	36	Menorrhagia / pelvic pain	Success
2	34	Menorrhagia / pelvic pain	Success
3	37	Menorrhagia / pelvic pain	Success
4	44	Menorrhagia / pelvic pain	Success
5	30	Menorrhagia / pelvic pain	Failure
6	32	Menorrhagia / pelvic pain	Success (Developed scanty periods)
7	25	Menorrhagia / pelvic pain	Failure
8	44	Menorrhagia	Success
9	40	Menorrhagia / pelvic pain	Success

Table 1: Summary of patient information, symptoms and follow up.

Regarding sonographic follow up, post procedure ultrasounds were done in five patients approximately one year after the procedure. In three of these patients large reductions in fibroid size (Ranging between 40

to 90%) were reported ; one patient had no decrease in size of fibroid while increase in number and sizes of fibroids were reported in one patient.

One patient (Age: 32 years) developed scanty periods after UAE, a known complication of this procedure.

Discussion

Uterine artery embolization is now an established procedure in the west with proven efficacy for reducing menorrhagia and controlling bulk related symptoms related to uterine fibroids.⁷⁻⁹ In Pakistan this procedure is being performed in limited centers during recent years, and this study describes our initial experience of this procedure in a series of nine patients.

There have been several single center studies that have shown 80 to 95 % patients showed improvement in both heavy bleeding and pelvic pain¹⁰⁻¹³ (Tab. 2).

Author	Total Patient	Improvement Menorrhagia	Improvement in pelvic pain
Messina et al. ¹⁰	26	87.5%	84.2%
Worthington-Kirsch et al. ¹¹	53	88%	94%
Prolius et al. ¹²	61	90%	88%
Goodwin et al. ¹³	59	81%	81%

Table 2: Comparison of post UAE improvement in menorrhagia and pelvic pain published in different single center studies.

Our results of 77% reduction in menorrhagia and 89% reduction in pelvic pain are comparable to other studies. We used the single-femoral artery approach with a single catheter to cannulate contralateral and then ipsilateral uterine arteries. This technique is reported to be safe and costs less than embolization with multiple catheters.¹⁴

The average duration of hospital stay was 2 to 3 days in our series and was similar to those previously reported.^{5,15} Patients experienced minor complications including symptoms of pain, fever, nausea, vomiting and anorexia. However, no incidence of serious infection necessitating prolonged hospital stay was observed.

Although all patients underwent technically successful embolization, in two patients the embolization treatment failed to give symptomatic relief and there was

persistence of abnormal bleeding without reduction in fibroid size on follow up ultrasounds. One of these patients (case 5) had a large fibroid while the other one had multiple fibroids (case 7).

The occurrence of new fibroids was reported on ultrasound in one patient (case 7) after embolization. The new fibroids probably existed before treatment but may have been too small to be visualized on the first sonographic examination. This finding, however, has been reported previously and indicates that uterus always has the capacity to develop new fibroids.¹⁵ One patient (case 6) developed scanty periods after the procedure. Exact cause of this could not be determined as patient did not give consent for biochemical analysis; however, some studies have reported loss of ovarian function after UAE, manifested as transient or permanent amenorrhea, possibly from non target embolization into ovarian arteries.¹⁶ This complication appears to be age related. Premature menopause has been reported in 2 to 3 percent of patients under the age of 45, and in approximately 8 percent of women over the age of 45 following UAE.^{17,18} One case report has described amenorrhea following UAE that was secondary to endometrial atrophy despite normal ovarian function.¹⁹


This study has certain limitations; it has a small sample size and is a single centre study. Compliance of patients regarding follow up was sub optimal and few patients were lost to follow up, further reducing the sample size.

Conclusion

As an initial experience, uterine artery embolization has shown promising results and appears to be a reasonable alternative to traditional surgical procedures. Another longitudinal multicenter study with larger patient population is required for definitive results in our local population.

References

1. Akhtar S. Short and long term complications of Abdominal and Vaginal Hysterectomy for benign disease. Pak Armed Forces Med J Jun 2004; **54(1)**:71-5.
2. Gambone RC, Reiter RC, Lench JB, Moore JB. The impact of a quality assurance process on the frequency and confirmation rate of hysterectomy. Am J Obstet Gynecol 1990;**163**:545-50.
3. Buttram VC, Reiter RC. Uterine leiomyomata: etiology, symptomatology and management. Fertil Steril 1981;**36**:433-45.
4. Dicker RC, Greenspan JR, Strauss LT, Cowart MR, Scally MJ, Peterson HB. Complications of abdominal and vaginal hysterectomy among women of reproductive age in the United States. Am J Obstet Gynecol 1982;**144**:841-8.
5. Ravina JH, Herbreteau D, Ciraru-Vigneron N, Bouret JM, Houdart E, Aymard A. Arterial embolisation to treat uterine myomata. Lancet 1995;**346**: 671-2.
6. McLucas B, Goodwin S, Adler L. Pregnancy following uterine fibroid embolization. Int J Gynaecol Obstet 2001; **74**:1.
7. Walker WJ, Pelage JP. Uterine artery embolization for symptomatic fibroids:clinical results in 400 women with imaging follow up. Br J Obstet Gynecol 2002;**109**:1262-72.
8. Pron G, Bennett J, Common A, Sniderman K, Asch M, Bell S, et al. Technical results and effects of operator experience on uterine artery embolization for fibroids: the Ontario Uterine Fibroid Embolization Trial. J Vasc Interv Radiol 2003;**14**:545-54.
9. Pron G, Mockarski E, Cohen M, Colgan T, Bennet J, Common A, et al. Hysterctomy for complications after uterine artery embolization for uterine leiomyoma: results of a Canadian multicentre clinical trial. J Am Assoc Gynecol Laparosc 2003;**10**: 99-106.

-
- 
10. Messina ML, Bozzini N, Halbe HW, Pinotti JA. Uterine artery embolization for the treatment of uterine Leiomyomata. *International Journal of Gynecology and Obstetrics*. 2002;**79**: 11-6.
 11. Worthington-Kirsch R, Popky G, Hutchins F. Uterine arterial embolization for the management of leiomyomas: quality-of-life assessment and clinical response. *Radiology* 1998;**208**:625-9.
 12. Prollius A, Vries, Loggenberg C, Plessis NA, Rensburg DJ, Wessels PH. Uterine artery embolization for symptomatic fibroids. *International Journal of Gynecology and Obstetrics*. 2004; **84**: 236-40.
 13. Goodwin SC, McLucas B, Lee M, Chen G, Perrella R, Vendanthan S. Uterine artery embolization for the treatment of uterine leiomyomata-midterm results. *J Vasc Interv Radiol* 1999;**10**: 1159-65.
 14. Pelage JP, Soyer P, Le Dref O. Uterine arteries: bilateral catheterization with a single femoral approach and a single 5-F catheter. *Radiology* 1999;**210**: 573-5.
 15. Brunereau L, Herbreteau D, Gallas S, Cottier JP, Lebrun JL, Tranquart F, Fauchier F, Body G, Rouleau P. Uterine Artery Embolization in the Primary Treatment of Uterine Leiomyomas: Technical Features and Prospective Follow-Up with Clinical and Sonographic Examinations in 58 Patients. *AJR* 2000;**175**:1267-72.
 16. Chrisman HB, Saker MB, Ryu RK. The impact of uterine fibroid embolization on resumption of menses and ovarian function. *J Vasc Interv Radiol* 2000; **11**:699.
 17. Bradley LD. Uterine fibroid embolization: a viable alternative to hysterectomy. *Am J Obstet Gynecol* 2009; **201**:127.
 18. Spies JB, Ascher SA, Roth AR. Uterine artery embolization for leiomyomata. *Obstet Gynecol* 2001; **98**: 29.
 19. Tropeano G, Litwicka K, Di Stasi C. Permanent amenorrhea associated with endometrial atrophy after uterine artery embolization for symptomatic uterine fibroids. *Fertil Steril* 2003; **79**:132.