

# PARAMEDIAN TYPE OF FRONTAL ENCEPHALOCELE WITH ASSOCIATED CLEFT LIP, CONGENITAL CHOLELITHIASIS AND ABSENT TWO DIGITS OF FOOT- A RARE COMBINATION

Shahnawaz Bashir,<sup>1</sup> Shah Naveed,<sup>2</sup> Tanveer H. Bandy,<sup>3</sup> Hasina Quari,<sup>4</sup> J.P.Singh<sup>5</sup>

<sup>1</sup> Department of Radiodiagnosis and Imaging, ASCOMS & Hospitals, Sidhra, Jammu, Jammu & Kashmir.

<sup>2</sup> Department of Surgery, ASCOMS & Hospitals, Sidhra, Jammu, Jammu & Kashmir.

<sup>3</sup> Department of Medicine, ASCOMS & Hospitals, Sidhra, Jammu, Jammu & Kashmir.

<sup>4</sup> Department of Health Services, Jammu & Kashmir.

<sup>5</sup> Department of Neurosurgery, ASCOMS & Hospitals, Sidhra, Jammu, Jammu & Kashmir.

PJR April - June 2011; 21(2): 77-80

## ABSTRACT

**INTRODUCTION:** A cephalocele is defined as a protrusion of intracranial contents through a defect in the skull or dura.<sup>1</sup> An anomaly that contains neural elements is termed encephalocele, neural elements and meninges; meningoencephalocele, meninges and subarachoid space; meningocele.<sup>2</sup> Approximately 90% cases involve the mid-line, rare subtypes are paramedian in location. Other malformations and / or chromosomal anomalies are noted in at least 60% of patients of encephalocele.<sup>3</sup> Currently most cases are diagnosed antenatally. Maternal serum alpha fetoprotein is raised only in 3 % cases as these defects are covered by skin.<sup>4</sup> **CASE PRESENTATION:** Here we present a 6 month old male infant with frontal encephalocele with rare paramedian location with associated cleft lip and absent 2 digits of right foot with congenital gall stones, an association reported first time in literature.

**Keywords:** Encephalocele; cleft lip; cholelithiasis.

## Case Report

A six-month old male child presented with a painless swelling on right side of frontal region since birth (Fig. 1, 2, 3 & 4). This swelling showed slow growth in size. His developmental milestones were normal. On examination he had an approximately 6 x 4 cm swelling on the right side of the forehead. It was firm and only slightly mobile in both horizontal and vertical direction. Also there was cleft lip and absent first 2 digits of right foot (Fig. 5 & 6). His respiratory and cardiovascular examination was normal. Per abdomen examination did not reveal any abnormality. His ophthalmic examination was also normal. His bowel and bladder habits were normal. Radiograph of skull showed a bony defect on right side in frontal region with an overlying soft tissue density shadow (Fig. 2 & 3). MRI was done (using a Hitachi Aperto Eterna 0.4T unit) which showed a large defect in the frontal region on right side with herniation of brain parenchyma along

with meningeal coverings and anterior horn of right lateral ventricle (Fig. 7 & 8). Routine Preoperative Ultrasound of the abdomen showed multiple stones in gall bladder. CBD was normal and rest of the ultrasound scan was unremarkable.

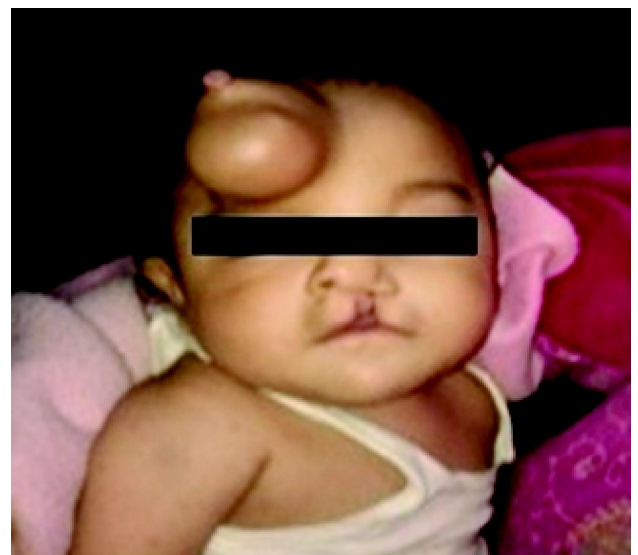
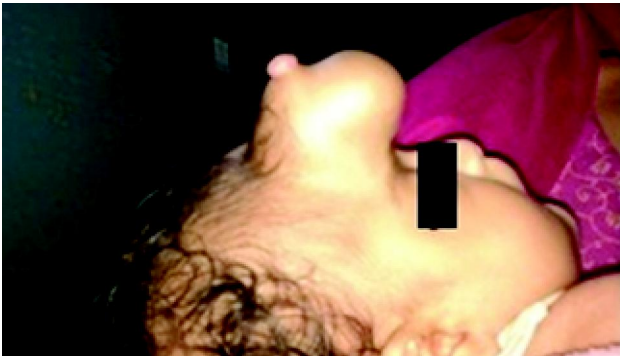
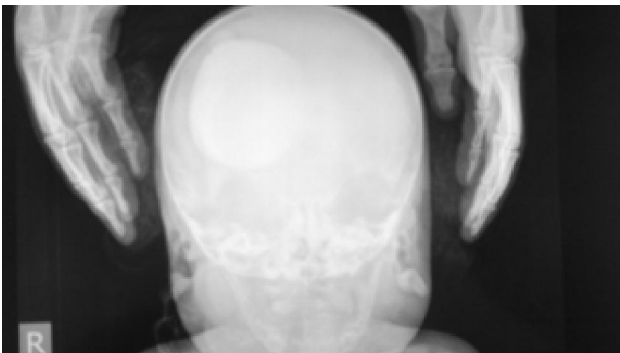Figure 1:

**Correspondence :** Dr. Shahnawaz Bashir  
Department of Radiodiagnosis and imaging,  
ASCOMS & Hospitals, Sidhra, Jammu,  
Jammu & Kashmir.  
E-mail: shahnawazbashir@gmail.com

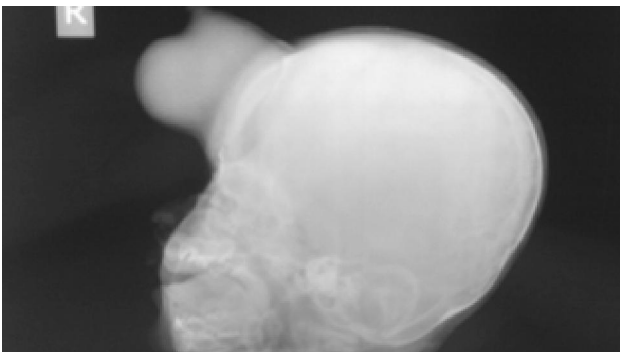

**Figure 2:**

**Figure 1 & 2:** Picture of 5 months old baby showing a large globular swelling on the right side of fore head



**Figure 3:**



**Figure 4:**

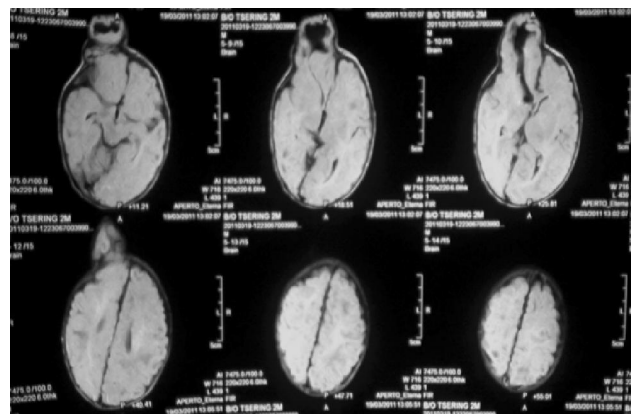
**Figure 3 & 4:** X-ray skull AP and Lateral views showing a soft tissue radiopaque shadow



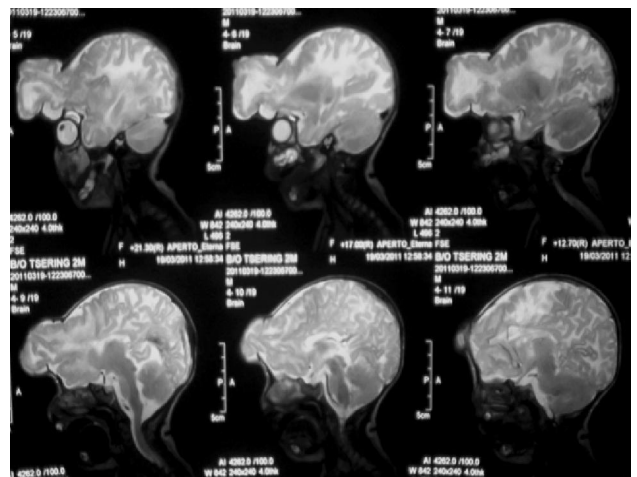
**Figure 5:** Picture of the feet showing absent Great and second toe of the right foot.



**Figure 6:** X-ray showing five metacarpals but absent Great and second toe.



**Figure 7:** T2 Weighted IR axial MR images( TR=100, TE=7475)



**Figure 8:** T2 weighted sagittal images(TR=100,TE=4262) showing herniation of frontal lobe through a paramedian skull defect. Note the elongated right frontal horn- typical of cephalocele.

A repair of the encephalocele was planned which was done on the 4th day of admission. Cleft lip repair was planned in the next available date. However the follow-up CT scan showed partial recurrence of the cephalocele (Fig.9 & 10).

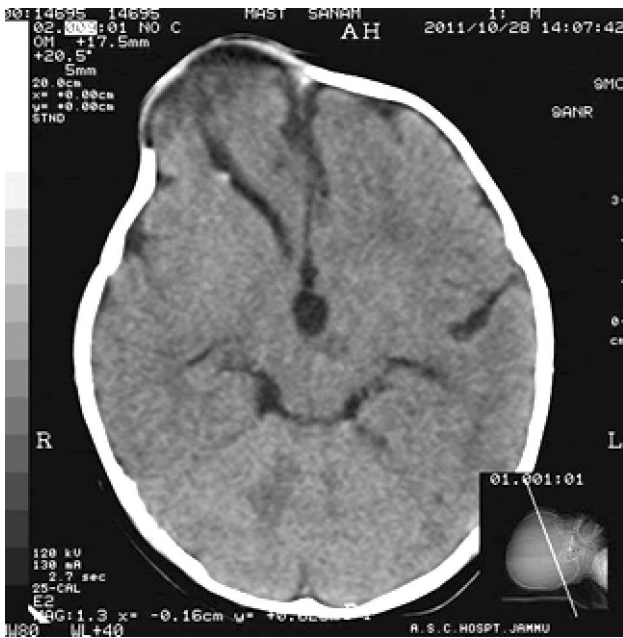

Figure 9:

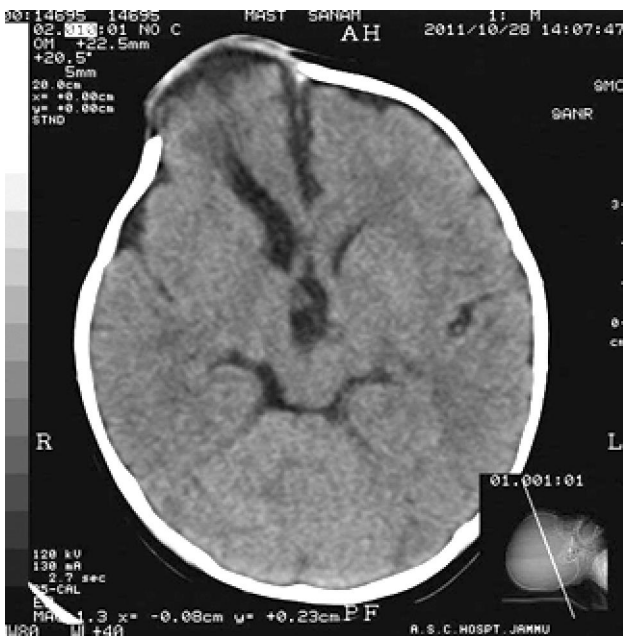

Figure 10:

Figure 9 & 10: Follow up Non-contrast CT scan, 3 months later shows a small recurrent encephalocele.

## Discussion

The cephalocele represents a prototype of disorders of dorsal induction (neurulation). During the third and fourth week of gestation closure of neural tube begins in cervicomedullary region and proceeds rostrally and caudally. The cephalic end of neural tube (anterior neuropore) closes at approximately 25 days of gestation

followed by caudal end (posterior neuropore) at approximately 28 days gestation. Limited failure of anterior neural tube closure results in formation of cephalocele with protrusion of intracranial structures from a skull defect. Cephaloceles are named for the location of the bone defects through which they course. The categories of cephaloceles include: (a) occipito-cervical (involving the occipital bone, foramen magnum, and posterior arches of upper cervical vertebrae); (b) occipital; (c) parietal; (d) frontal; (e) temporal (along the superior surface of the petrous ridge); (f) sphenomaxillary (through orbital fissures into pterygopalatine fossa); (g) sphenoorbital (through defect in sphenoid bone or optic canal/orbital fissure into orbit); (h) nasopharyngeal (through ethmoid, sphenoid, or basiocciput into nasal cavity or pharynx); and (i) lateral (along coronal or lambdoid sutures).<sup>5</sup> The lesions occur most often in occipital region (70%) followed by frontal, parietal, nasal and nasopharyngeal locations. Cephaloceles occur about once in 4000-5000 live births. Geographic differences in the distribution of cephalocele indicate additional racial and perhaps environmental factors in the formation of encephalocele. Cephaloceles are most common in occipital location in Europe and America and more frequently frontal in location in Russia and South East Asia.<sup>2</sup> The absence of brain tissue within the herniated sac is the single most favorable prognostic feature for survival.<sup>4</sup> Fifty-percent cephaloceles are complicated by hydrocephalus. Dandy Walker and Chiari malformation (Type 3) are commonly associated with occipital cephalocele and dysgenesis of corpus callosum is associated with frontoethmoidal and sphenoidal encephalocele. Cephaloceles may be isolated anomalies, may be seen in conjunction with other anomalies, or may be part of a syndrome<sup>6</sup> or Neurofibromatosis I, interhemispheric lipoma and subependymal heterotopic gray matter.<sup>7</sup> Other known associations are genetic syndromes such as Meckel-Gruber, Von Voss, Chemke, Roberts, and Knobloch syndromes, Amniotic band syndrome, maternal rubella and Diabetes. The most common associated chromosomal anomaly is Trisomy 18.<sup>4</sup> On the basis of location of the osseous defect one may distinguish four groups of frontal cephaloceles as Naso-frontal, Naso-ethmoidal, Naso-orbital and interfrontal.<sup>2</sup> Most of the frontal encephaloces are in the midline; rare subtypes are paramedian in location. Off-midline lesions usually indicate an association with the amniotic band syndrome.<sup>8</sup> Meckel syndrome is a term used when an



occipital encephalocele is associated with microcephaly, microphthalmia, cleft lip and palate, polydactyly, polycystic kidneys and ambiguous genitalia.

Histopathologically herniated brain tissue is abnormal and distorted but may have functional tissue. The protruded brain has the unmyelinated white matter.<sup>7</sup> Neuroradiological investigation centres on providing information regarding the content of the sac (presence or absence of brain or major blood vessels) and delineation of associated anomalies.<sup>2</sup> Cephaloceles are commonly seen in patients with neurofibromatosis I; these patients may have functioning neural tissue within the cephalocele.<sup>6</sup>

The plain radiographic appearance of a cephalocele is that of a midline cranial defect with sclerotic margins. If a large amount of brain is present within the cephalocele, the craniofacial ratio will be diminished.<sup>6</sup> This appearance is quite nonspecific more over plain radiographs rarely provide diagnostic information about contents of encephalocele.

Post natal CT gives excellent depiction of bony defect particularly with coronal, Sagittal and 3D reconstruction. But it is less capable in showing soft tissue components within an encephalocele. Water soluble contrast material that is placed within the theca and that flows into encephalocele may allow better evaluation of contents. CT cisternography often demonstrates a communication of herniated sac with the intracranial subarachnoid space. CT is also useful in demonstration of associated

Postnatal MRI is most sensitive and accurate imaging modality.<sup>4,7</sup> Exquisite detail of cranial defect and herniated contents is seen. Contents of herniated sac may include CSF, disorganized brain tissue and even ventricles. They are visualized clearly on MRI. MRI is also useful in demonstrating associated anomalies.<sup>4</sup> Typical findings are tissue is seen protruding towards the bony defect is distorted, there is general tendency of the ventricles to be elongated and point towards the defect.<sup>7</sup>

Antenatal sonography shows demonstration of cranial defect with varying degree of brain herniation. Classic sonographic appearance is that of a mass in midline of skull with most case occurring in the occipital and less commonly the frontal region. Size is variable. Consistency may be purely cystic or may contain internal echoes. Because skull ossification begins at 10 weeks diagnosis is not usually possible before this time. Frontal encephalocele always contain brain tissue

and involve bridge of nose (60%) and nasal cavity (30%).

Radionuclide ventriculography and / or cisternography has been used to demonstrate intracranial extension of an encephalocele. Currently MRI can demonstrate this effectively. Radionuclide cisternography can be performed via lumbar puncture or ventricular injection using TC<sup>99m</sup>MDPA followed by planar or single photon emission computed tomography. Angiography may be needed to evaluate intracranial and extracranial vasculature before surgical repair is performed. Angiography is helpful if concern exists regarding the displacement of the dural venous sinus in the sac.<sup>4</sup>

## References

1. Ketonen L, Hiwatashi A, Sidhu R. Pediatric brain and spine, an atlas of MRI and spectroscopy. Springer- Verlag Berlin Heidelberg, 2005, pp 28-33.
2. Haaga J.R et al. CT and MRI of whole body, 5th ed. Mosby Elsevier 2009; 705-6.
3. Phatak SV, Rajderkar D. IMAGES: Rare type of frontal encephalocele (paramedian). Indian J Radiol Imaging 2006; **16**: 309-11.
4. Diebler C, Dulac O. Cephaloceles: clinical and neuroradiological appearance: associated cerebral malformations. Neuroradiology 1983; **25**:199-216.
5. Simpson DA, David DJ, White J. Cephaloceles: treatment, outcome and antenatal diagnosis. Neurosurgery 1984;**15**:14-21. PMID: 6472590
6. Scott W Atlas. MRI OF Brain And Spine ,4th edition, Lippincott Williams and Wilkins, 2009, 226-7.
7. Classification of congenital abnormalities of the CNS. van der Knaap MS, Valk J. AJNR Am J Neuroradiol. 1988 Mar-Apr; **9**(2): 315-26.
8. Mahony BS, Filly RA, Callen PW, Golbus MS.:The amniotic band syndrome: antenatal sonographic diagnosis and potential pitfalls. Am J Obstet Gynecol. 1985 May 1; **152**(1): 63-8.