

GASTRIC DUPLICATION CYST-A RARE CAUSE OF GASTRIC OUTLET OBSTRUCTION

Ameet Kumar Jesrani, Mahira Yunus, Asma Zafar, Syed Mohammad Faiq, Shabbir Naeem, Anwar Naqvi

Sindh Institute of Urology and Transplantation (SIUT), Karachi, Pakistan.

PJR April - June 2011; 21(2): 75-76

Introduction

Gastric duplication (GD) is an uncommon malformation of gastrointestinal tract with incidence of 7% of all alimentary tract duplication, usually presenting as gastric outlet obstruction. It is usually cystic and most common site is greater curvature of the stomach (65%).

Case Report

We report a case of 27 year old female who presented with complain of epigastric pain, nausea and vomiting. Her general physical examination and lab investigation (Hb, TLC and ESR) were normal. Her CT scan showed a hypodense cystic lesion involving the greater curvature of stomach, with loss of intervening fat planes between the lesion and gastric wall with another small exophytic intra mural hypodense lesion arising from fundus of stomach. No calcification is seen within the cysts. The HU of cysts are 8-10 and enhancement of the cyst wall seen after IV contrast, please see (Fig. 1 a & b) and (Fig. 2). These two intramural cystic appearing lesions represent duplication cysts.

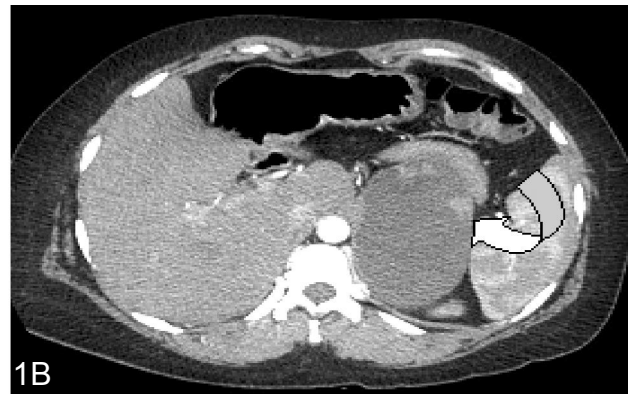
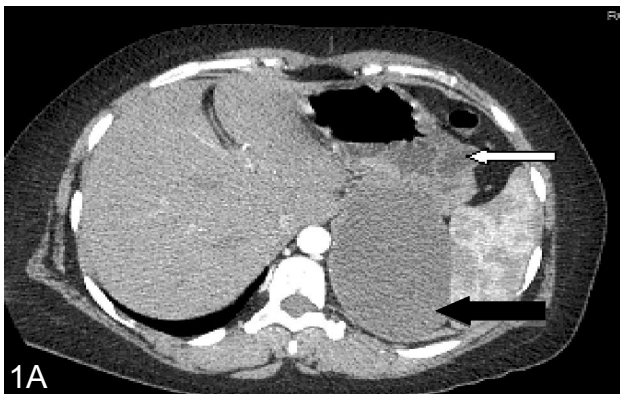
Figure 1a & b: Axial CT scan post contrast showing larger hypodense cystic area with mild enhancement of walls (curved arrow) along greater curvature and posterior wall of stomach (black arrow). another small intramural cystic lesion is seen within the wall of greater curvature and anterior wall of stomach (white arrow).



Correspondence : Dr. Ameet Kumar Jesrani
Department of Radiology,
Sindh Institute of Urology and
Transplantation (SIUT), Karachi, Pakistan.
Ph: 0300-2727967
Email: ameer.jesrani@hotmail.com

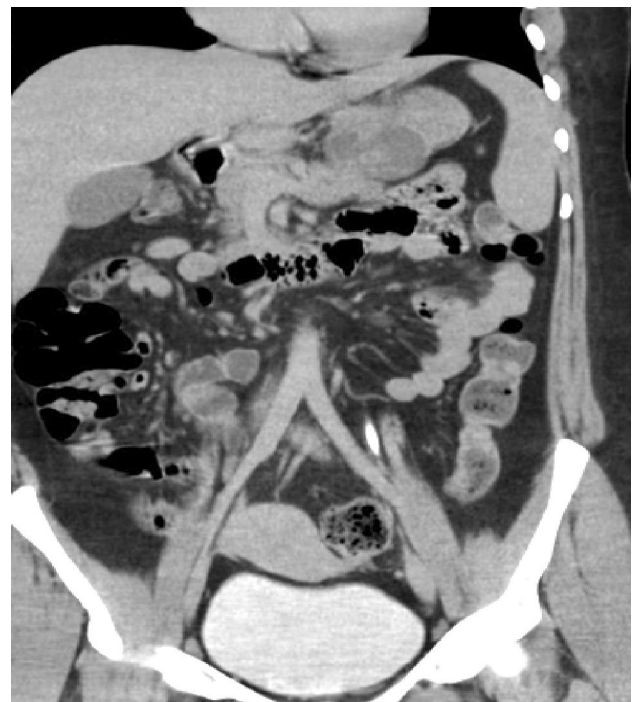


Figure 2: Coronal CT scan showing cystic lesion involving greater curvature.

Discussion

Duplications can be found along the entire alimentary tract, the most common site being ileum (30-33%), other sites are esophagus (17-20%), colon (13-3%), jejunum (10-13%), stomach (7%), duodenum (4-5%), ileocecal junction (4%) and rectum (4%). Various theories have been postulated regarding the origin of duplication cysts, like; 1) abortive attempts of twinning; 2) phylogenetic reversion; 3) adhesions between endoderm and neuroectoderm; 4) persistence of embryonic diverticula; 5) Recanalisation and fusion of longitudinal folds.

Gastric duplication (GD) is one of the rare causes of gastric outlet obstruction in the neonates. The other causes of gastric outlet obstruction being congenital hypertrophic pyloric stenosis, congenital antral web and in a newborn pyloric arteria which should be included in the differential diagnosis but these causes presents in earlier age than GD cyst.

GD usually presents with an upper abdominal mass and vomiting. A few patients of GD can also present with haematemesis and melena. Older patients may present with pain in abdomen, nausea and vomiting and weight loss. GD is commonly seen in females. The diagnosis should be suspected when an infant usually a female comes with features of gastric outlet obstruction. USG and CT scan of abdomen are highly contributive in the diagnosis of GD cyst. Literature shows that GD is managed surgically by simple excision, by dissecting the common wall between the stomach and the duplication cyst, and usually it can be done easily without entering the stomach. But in cases where one does not get a plane of dissection in the common wall one should excise the common wall and suture the gastric defect as leaving behind the common wall (gastric epithelium) would expose the child to inflammatory complications.

Sonography and CT facilitates the diagnosis. The sonographic appearance is that of a cystic lesion with a thin, highly echogenic rim and a wide anechoic central portion. The echogenic lining is thought to represent the mucosa, and the anechoic rim is thought to represent the muscular wall. This appearance is considered characteristic of gastric duplication cyst. CT appears to be superior to Sonography. The cystic masses are shown clearly on CT scan. The walls of the cyst appear thick, and contrast enhancement within the cyst is present. The lesion is easily localized and readily distinguished from surrounding structures.

Conclusion

Infants who present with epigastric pain, nausea and vomiting. The D/D of gastric duplication cyst should be considered which is an uncommon malformation of GIT, usually presents as gastric outlet obstruction.

References

1. Calder J. Medical essays obser 1733; **1**: 205.
2. Ladd WC. Duplication of the alimentary tract. South Medical Journal 1937; **30**: 363.
3. Richard MK, Ronald BL, Robert JI, Jr. JPS 1970; **5**: 3.
4. Edwards H. Congenital diverticula of the intestine with the report of a case exhibiting heterotopia. Brit J Surg 1929; **17**: 7.
5. Hudson HW, Jr. Giant diverticula or reduplications of the intestinal tract. New Eng J Med 1935; **213**: 1123.
6. McLetchie NGB, Purves JK, Saunders RL. Genesis of gastric and certain intestinal diverticula and enterogenous cysts. Surg Gynae Obstet 1954; **99**: 135.
7. Lewis FT, Thyng FW. The regular occurrence of intestinal diverticula in the embryos of pig, rabbit and man. Amer J Anat 1907; **7**: 505.
8. Bremer JL. Diverticula and duplications of the intestinal tract. Arch Path 1944; **38**: 132.