

FLOW VOID SIGN" ON MRI: DIFFERENTIATION OF UTERINE LEIOMYOMAS FROM OTHER SOLID PELVIC MASSES

Imrana Masroor, Ayesha Walid, Shaista Afzal, Saira Naz Sufian, Saba Sohail

Department of Radiology, Aga Khan University Hospital, Karachi, Pakistan.

PJR October - December 2016; 26(4): 275-280

ABSTRACT

OBJECTIVE: To assess the usefulness of demonstrating flow void sign on conventional MRI sequences in differentiating uterine leiomyomas from other solid pelvic masses which have same signal intensity to myometrium.

METHODS: This descriptive study was conducted in the Department of Radiology, Aga Khan University Hospital, Karachi from April 2014 to May 2015. It comprised female patients of all ages who had magnetic resonance imaging (MRI) pelvis with diagnosis of a solid appearing pelvic mass followed by surgery and histopathology at our institution. Flow void sign was described as demonstration of feeding vessels appearing as flow void between the uterine leiomyomas and uterus. Histopathology was taken as gold standard. **RESULTS:** Flow void sign was observed in 66 out of 73 pelvic masses on MRI. Out of 66 patients 65 were diagnosed histologically as leiomyomas. When the flow void sign was seen on MRI and subsequent histopathology confirmed the diagnosis of leiomyoma. In all such cases the sensitivity, specificity, positive and negative predictive values, and diagnostic accuracy of the flow void sign for diagnosing leiomyomas were calculated as 97% (65/67), 83% (65/66), 98% (65/66), 71% (65/67) and 95% (70/73), respectively. **CONCLUSION:** Flow void sign is an important ancillary sign for the radiological diagnosis of leiomyoma on MRI and useful in differentiating leiomyoma from focal adenomyosis or ovarian tumors (fibromas) which show signal intensity similar to uterine leiomyomas.

Key Words: Leiomyomas, Magnetic Resonance Imaging, Flow void sign, Pelvic mass

Introduction

Uterine leiomyomas (or fibroids) are the most common benign pelvic tumors in Women.¹ Their incidence increases with age and are found in 25-50% of women older than 40 years.^{2,3}

MRI is the modality of choice for evaluating gynecological disease as it provides excellent contrast resolution resulting in accurate tissue characterization and improved anatomic delineation.⁴ Leiomyomas are typically T1-weighted isointense and T2-weighted hypointense benign tumors. They show homogeneous enhancement similar to myometrium on contrast administration and do not show diffusion restriction on diffusion weighted imaging.

These can be of various types depending upon their site of origin from myometrium like intramural, sub mucosal and subserosal. The subserosal type especially if pedunculated may be difficult to differentiate from other solid appearing adnexal masses. Various other solid appearing pelvic masses or those with smooth muscle or fibrous tissue components can have an MRI appearance similar to leiomyoma, like ovarian fibroma, desmoids arising from adjacent pelvic bowel loops.^{4,5} Often it is possible to characterize the pelvic masses on the basis of their site of origin; however, difficulty arises with large solid masses that cross or distort anatomical orientation. The presence or absence of normal visible ovaries is one of the useful clues in assessing the origin of a pelvic

Correspondence : Dr. Imrana Masroor
Department of Radiology,
Aga Khan University Hospital,
Karachi, Pakistan.
Tel: 34930051 - Ext.: 2020
Email: imrana.masroor@aku.edu

Submitted 26 July 2016, Accepted 20 August 2016

mass, but normal ovaries may not be demonstrable in post-menopausal women or more commonly are not visualized with large pelvic masses due to their mass effect. Another useful clue can be to demonstrate feeding vessels of the pelvic mass which appears as signal void on MRI.⁶

Leiomyomas are supplied by the vessels from the uterine arteries coursing through the adjacent myometrium and appear as vessels intervening between a myoma and adjacent uterus.⁶ These vessels project as peripheral flow voids of uterine leiomyomas on MRI.⁷ On the other hand ovarian masses are directly supplied by ovarian arteries or by the ovarian branches of uterine arteries traversing along fallopian tube, and the pelvic masses originating from other pelvic organs have feeding vessels from the respective organ. Keeping in view the above description the peripheral flow voids will therefore not be seen with other pelvic masses that may have a morphological appearance and signal characteristics on MRI examination, similar to leiomyomas.

Purpose

The purpose of this study to assess the usefulness of demonstrating flow void sign on conventional MRI sequences in differentiating uterine leiomyomas from other solid pelvic masses which have same signal intensity to myometrium.

Methodology

The study was conducted at the Department of Radiology, Aga Khan University Hospital Karachi, Pakistan after acquiring exemption of the informed consent from the Hospital's Ethical Review Committee (ERC exemption no 3714-Rad-ERC-15). The sample size has been calculated on WHO software version of sample size determination in health studies. The sensitivity of flow void sign in differentiating subserosal leiomyomas from extra-uterine tumors on MRI is reported to be 95%.⁵ We retrospectively evaluated these patients using a computerized database over a span of one year from April 2014 to May 2015. Inclusion criteria were female patients of all ages

who had undergone MRI pelvis at our department, with clinical query of a solid pelvic mass, on clinical examination or on ultrasound examination where the organ of origin was not characterizable on ultrasound. Following MRI they had surgery and histopathology at our institution. In case of multiple pelvic masses in a single patient each mass was studied as a separate case. Mass lesions less than 3 cm in size were excluded from the study.

Exclusion criteria were all patients whose MRI showed distinct ovarian masses and cystic masses outside the myometrium. Patients who did not undergo surgery and histopathology at our institution were also excluded.

For MR imaging, SIEMENS Magnetom 1.5 T magnet was used with section thickness of 5-8 mm and interslice gap of 1-2 mm. T2-weighted images in axial, sagittal and coronal planes and T1-weighted fat suppressed axial images were acquired. Following IV contrast injection of gadopentetate dimeglumine (Magnevist™) at a dose of 0.1 mmol/kg of body weight T1-weighted images were obtained in axial, sagittal and coronal planes with fat suppression.

Imaging findings were analyzed by two radiologists with more than five years of experience in women imaging in consensus without knowledge of the pathologic diagnosis focusing specifically on the interface vessels between the masses and uterus.

Flow void sign was considered to be present when flow voids could be identified between the mass and the uterus on MRI. Leiomyoma was defined as a well encapsulated uterine mass that appeared hypointense on T2-weighted images and isointense on T1-weighted images, showing post contrast enhancement similar to myometrium. Other solid pelvic lesions included those solid appearing pelvic masses that had signal characteristics similar to leiomyomas that is also appear hypointense on T2-weighted images and isointense on T1-weighted images.⁸

Data initially collected on proforma, was later analyzed using SPSS version 19. Frequencies and percentages of quantitative variables were calculated. Histopathology was the gold standard to assess the diagnostic accuracy of the flow void sign in distinguishing leiomyomas from other solid pelvic masses on MRI.

Results

A total of 73 solid appearing pelvic masses were evaluated for the presence or absence of flow void sign on MRI. These ranged in size from 3.1 - 17.5 cm with an average size of 7 ± 3.34 cm. Female patients included in the study had an average age of 38.5 ± 8.4 years.

Flow void sign was observed in 66 out of 73 pelvic masses on MRI, out of which 65 were diagnosed histologically as leiomyomas. One false positive case was an ovarian fibroma on histopathology. The remaining 7 pelvic masses did not show flow void sign on MRI. Of these 4 one was an adenomyoma, 1 fibroma/thecoma and 2 fibroids on histopathology.

For the purpose of the study, true positive case (TP) i.e leiomyomas was positive both on MRI and histopathology; false positive (FP) was positive on MRI and negative on histopathology; false negative (FN) was negative on MRI and positive on histopathology; and true negative (TN) was negative on both MRI and histopathology (Tab. 1).

When the flow void sign was seen and subsequent histopathology confirmed the diagnosis of leiomyoma on MRI the sensitivity, specificity, positive and negative predictive values, and diagnostic accuracy were calculated as 97% (65/67), 83% (65/66), 98% (65/66), 71% (65/67) and 95% (70/73), respectively.

Groups	Histopathology + ve	Histopathology - ve
MRI +ive for flow void sign	TP (65)	FP (1)
MRI - ive for flow void sign	FN (2)	TN (5)

Table 1: Distribution of patients for calculation of diagnostic accuracy

Discussion

Accurate detection and differentiation of pelvic masses is important for planning a treatment strategy.⁹ Masses can be differentiated on the basis of their site of origin and signal characteristics on MRI. This is easy with small masses, but becomes difficult with increasing size of a pelvic mass. Leiomyomas are the commonest benign uterine tumors. These have a typical MRI appearance of distinct low signal intensity on T2-weighted images, due to excessive hyalinization that allows for their diagnosis.¹⁰

The central location and inseparability from the uterus generally allows to make a confident diagnosis of uterine leiomyoma. However, large leiomyomas especially subserosal/pedunculated or those lying within the leaves of the broad ligament may simulate an adnexal mass.¹⁰

On MRI the signal characteristics of uterine myomas and adnexal masses may be sufficiently distinctive to allow a differential diagnosis. However, a degenerated uterine myoma may have a varied appearance on T2-weighted and contrast enhanced images according to the hyaline or myxoid degeneration, degree of interstitial edema, cystic degeneration, necrosis, fibrosis, calcification, haemorrhage, carneous degeneration, and fat.¹¹ On the other hand various other solid appearing pelvic masses or those with smooth muscle or fibrous tissue components can have an MRI appearance similar to leiomyoma.^{4,5} Adnexal masses such as fibroma, thecoma, Brenner tumors, dysgerminoma and Krukenberg's tumor may also show hypointensity on T2-weighted images.¹⁰ Therefore ancillary signs are needed to strengthen the radiological diagnosis in such doubtful cases.

One of the useful clues in assessing the origin of a pelvic mass is the presence or absence of normal ovaries. However, normal ovaries may not be visible on imaging in post-menopausal status or get displaced and obscured by a large exophytic fibroid. Furthermore, a mass may arise from the periphery of the ovary and therefore the identification of an apparently normal ovary does not exclude its ovarian origin.⁶ Another useful sign is the vascular supply of the pelvic mass and its feeding vessels. These feeding vessels will appear as signal void structures on MRI. We used the term "flow void sign" in this study when these feeding vessels were seen between the uterus and the pelvic mass (Fig. 1).

Leiomyomas are surrounded by compressed normal myometrium and a scaffolding of vascular tissue,^{12,13} giving us "flow void sign" on MRI (Fig. 2). Pathologically, both dilated feeding arteries and draining veins are seen within the surrounding myometrium when flow void sign is present.⁷ A previous report on pelvic angiography showed that dilated feeding arteries are one of the characteristic features in uterine leiomyomas, whereas other pelvic masses including ovarian and uterine cancers are usually hypovascular.¹³ Therefore it is assumed that the sign is pro-

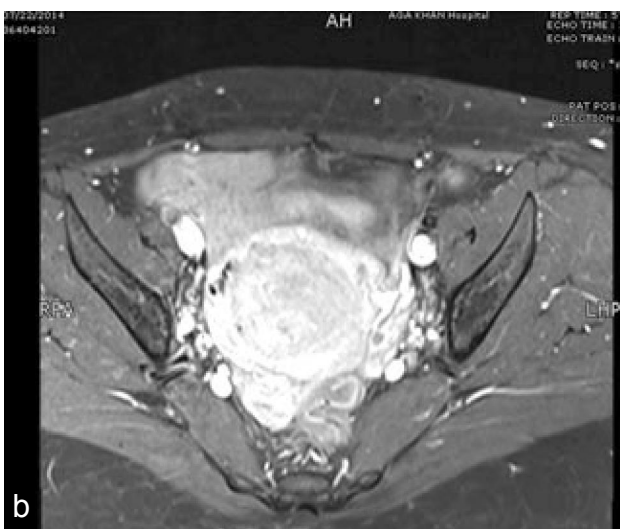
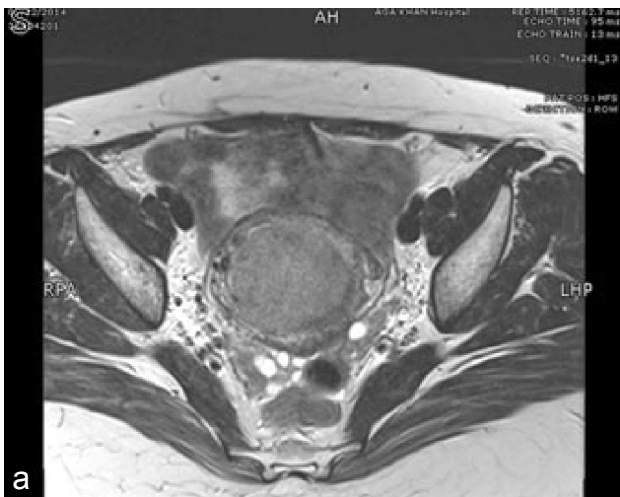


Figure 1: Intramural leiomyoma with flow void sign. T2-weighted (a) and post contrast axial images (b) show a well defined mass within the myometrium with prominent interface vessels between the mass and the uterus giving the flow void sign (arrows).

duced by dilated vessels with fast flow, probably arteries from the myometrium supplying the leiomyoma. The contribution of draining veins which usually have slow flow is small.⁷ This is most likely the reason that enhancement of the flow voids is not seen on post contrast imaging. This observation was made in this study and also reported in a previous study.⁷

Torashima et al. reported that peripheral flow voids seen with leiomyoma on MRI indicate that the uterus is the organ of origin of these masses as they are not seen with any other kinds of pelvic tumors. They concluded that flow voids were seen exclusively in leiomyomas of 3 cm diameter or larger and that large

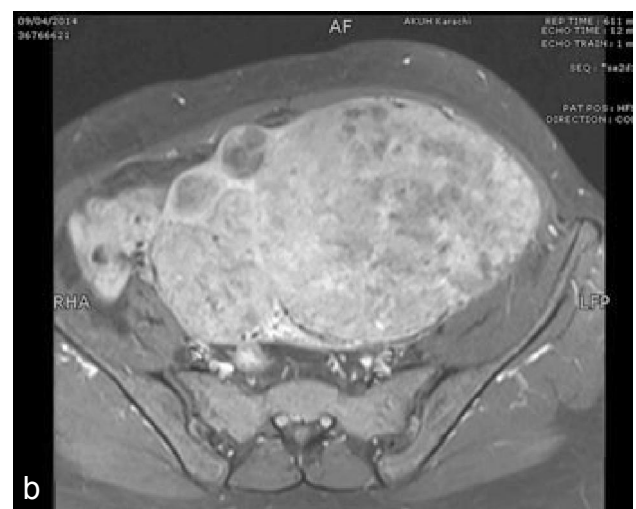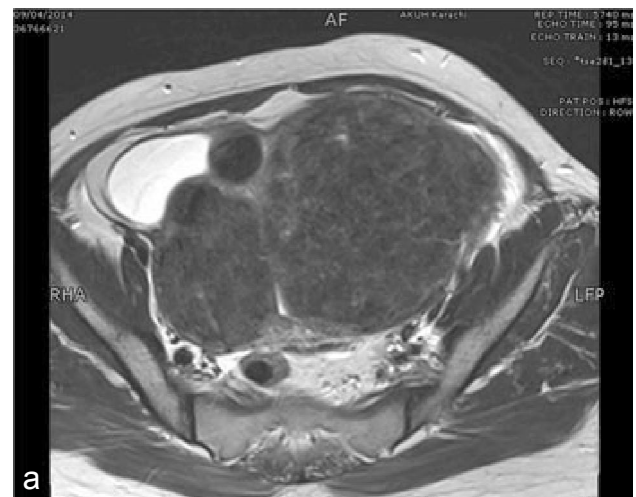


Figure 2: Multiple uterine fibroids. T2-weighted (a) and post contrast axial images (b) show flow void sign in the periphery of the large fibroids, conspicuous on post contrast images (arrow).

myomas and those with irregular signal intensity on T2-weighted images had a higher prevalence of this sign than others.⁷

Kim et al. reported “interface vessels” on color and power Doppler ultrasound and MRI when feeding vessels were seen between the uterus and a pelvic mass. In Kim et al. study they had a sample size of 41 patients with subserosal myomas and 27 patients with solid extra uterine tumors. They concluded that the interface vessels were a useful clue for differentiating subserosal uterine myomas from extrauterine tumors. In all their cases contrast enhanced T1-weighted imaging was the best for the conspicuity of the interface vessels. The sensitivity, specificity, positive predictive value, negative predictive value

and accuracy of interface vessels for a positive final diagnosis was calculated as 95%, 89% , 93%, 92% and 92% respectively.⁶ Results of the present study are comparable to those of Kim et al. Our study showed that flow void sign is both sensitive as well as specific for the diagnosis of leiomyoma on MRI with a sensitivity , specificity, positive predictive value, negative predictive value and diagnostic accuracy of 97%, 83% , 98% , 71% and 95% , respectively.

In an article by Mittl et al. reported a high signal intensity rim on T2 weighted images surrounding a uterine myoma and has reported that the histological correlate of this findings was dilated lymphatic vessels, dilated veins, and/or edema. In this study they mentioned that high signal intensity rim was present in intramural and subserosal myomas, but not in submucosal myomas. They concluded that this sign may be helpful in differentiating exophytic subserosal myomas from adnexal masses.¹⁵ In all our cases of subserosal myomas after even after care full evaluation we did not observe the high signal intensity rim on T2 weighted images in any case.

In a study by Thomassin-Naggara et al. utilizing dynamic contrast enhanced MRI for differentiating ovarian fibromas and subserosal uterine leiomyomas, enhancement was found to be more intense and precocious in uterine leiomyomas than ovarian fibromas and typical thin regular arterial vessels were visualized in 73% of subserous uterine myomas.¹⁶ This corresponds to the flow void sign seen in this study.

Flow void sign is useful for differentiating leiomyomas and focal adenomyosis (adenomyoma) (Fig. 3) or solid ovarian masses (fibroma, thecoma) these masses often show signal intensity similar to uterine leiomyomas, but the flow void sign was not seen in any of ovarian tumors therefore it may not be sensitive but is quite specific for differentiating uterine leiomyomas from other pelvic masses. In this study there was one fibroma which showed flow void sign similar to leiomyomas this was because it was large more than 5 cm and was lying on the fundus of uterus rather than in adenexa. There were two fibroids which did not show the flow void sign this can be attributed to their size as both were 3 cm in one dimension but the other dimension was less than 3 cm as well as due to the fact that they were both intramural in location.

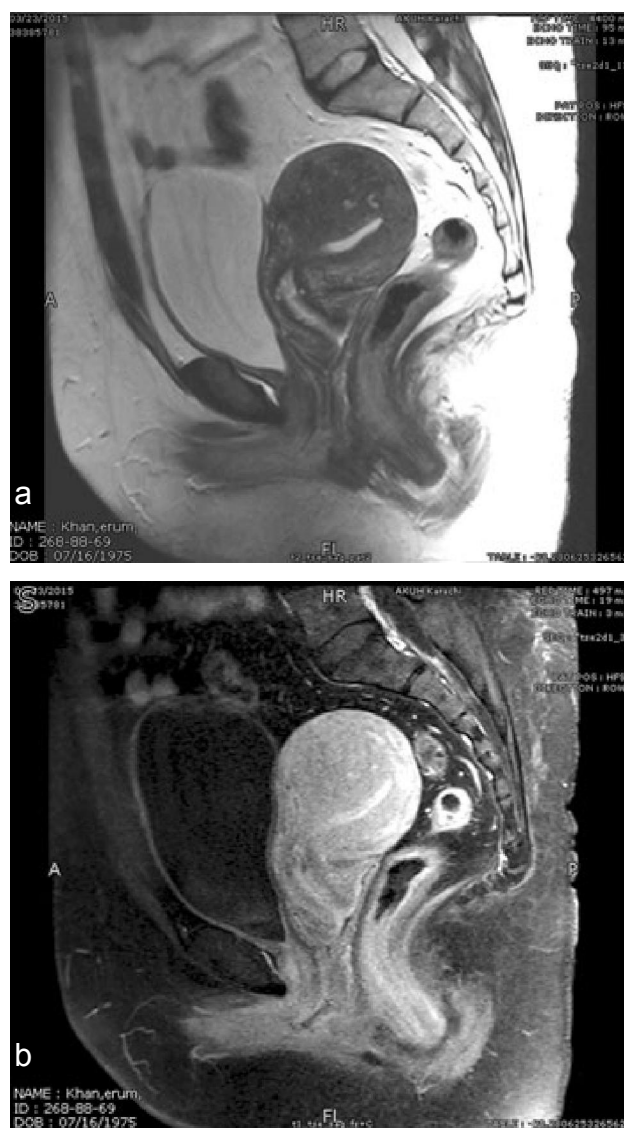


Figure 3: Adenomyosis.. T2-weighted (a) and post contrast sagittal images (b) show an ill defined abnormal signal intensity are within the anterior myometrium (arrow). It is T2-weighted hypointense similar to fibroid but does not demonstrate flow void sign.

There are a few limitation of our study as the sample size was small and the study was done at a single center. There have been only two studies internationally on literature search and no local studies have been conducted so the results cannot be compared with more studies done.

Conclusion

The flow void sign is an important ancillary sign for the radiological diagnosis of leiomyoma on MRI and

useful in differentiating leiomyoma from focal adenomyosis or ovarian tumors which show signal intensity similar to uterine leiomyomas.

References

1. Zimmermann A, Bernuit D, Gerlinger C, Schaefer M, Geppert K. Prevalence, symptoms and management of uterine fibroids: an international internet-based survey of 21,746 women. *BMC Women's Health*. 2012; **26**: 12-6.
2. UrRehman I, UIHaq T, Hamid R.S, Azeemuddin M., Akhtar W, Kanwal D. Uterine Artery Embolization For The Treatment Of Uterine Fibroids: Initial Experience. *PJR*. 2011; **21(1)**: 01-5.
3. Shaheen S, Naheed T, Sadaf F, Rahim R. Menorrhagia Due to Fibroids and its Management. *J SOGP*. 2013; **3(4)**: 231-5.
4. Allen BC, Hosseinzadeh K, Qasem SA, Varner A, Leyendecker JR. Practical approach to MRI of female pelvic masses. *AJR Am J Roentgenol*. 2014; **202(6)**: 1366-75.
5. Park SB. Features of the hypointense solid lesions in the female pelvis on T2-weighted MRI. *J Magn Reson Imaging*. 2014; **39(3)**: 493-503.
6. Kim SH, Sim JS, Seong CK. Interface vessels on color/power Doppler US and MRI: a clue to differentiate subserosal uterine myomas from extrauterine tumors. *J Comput Assist Tomogr*. 2001; **25(1)**: 36-42.
7. Torashima M, Yamashita Y, Matsuno Y, Takahashi M, Nakahara K, Onitsuka Y et al. The value of detection of flow voids between the uterus and the leiomyoma with MRI. *J Magn Reson Imaging*. 1998; **8(2)**: 427-31.
8. Weinreb JC, Barkoff ND, Megibow A, Demopoulos R. The value of MR imaging in distinguishing leiomyomas from other solid pelvic masses when sonography is indeterminate. *AJR Am J Roentgenol*. 1990 Feb; **154(2)**: 295-9.
9. Lee JH, Jeong YK, Park JK, Hwang JC. "Ovarian vascular pedicle" sign revealing organ of origin of a pelvic mass lesion on helical CT. *AJR Am J Roentgenol*. 2003 Jul; **181(1)**: 131-7.
10. Aggarwal BK, Panwar S, Rajan S, Aggarwal A, Ahlawat K. Varied appearances & signal characteristics of leiomyomas on MR imaging. *Ind J Radiol Imaging*. 2005; **15(2)**: 271-6.
11. Murase E, Siegelman ES, Outwater EK, Perez-Jaffe LA, Tureck RW. Uterine leiomyomas: histopathologic features, MR imaging findings, differential diagnosis, and treatment. *Radiographics*. 1999 Sep-Oct; **19(5)**: 1179-97.
12. Farrer-Brown G, Beilby JOW, Rawles PM. Microvasculature of the uterus. An injection method of study. *Obstet Gynecol* 1970; **35(1)**: 21-30.
13. Pelage JP, Cazejust J, Pluot E, Le Dref O, Laurent A, Spies JB et al. Uterine fibroid vascularization and clinical relevance to uterine fibroid embolization. *Radiographics*. 2005 Oct; **25(1)**: S99-117.
14. Lang EK. Bladder and pelvic angiography. In: Abrams IIL. ed. *Abrams angiography: vascular and interventional radiology*, 3rd ed. Boston: Little, Brown and Company, 1983: 1753-88.
15. Mittl RL Jr, Yeh IT, Kressel YH. High-signal-intensity rim surrounding uterine leiomyomas on MR images: pathologic correlation. *Radiology* 1991; **180(1)**: 81-3
16. Thomassin-Naggara I, Darai E, Nassar-Slaba J, Cortez A, Marsault C, Bazot M. Value of dynamic enhanced magnetic resonance imaging for distinguishing between ovarian fibroma and subserosal uterine leiomyomas. *J Comput Assist Tomogr*. 2007 Mar- Apr; **31(2)**: 236-42