

## HEMANGIOMAS OF LIVER; A RADIOLOGIST'S PERSPECTIVE

Basit Salam, Rana Shoaib Hamid, Tanveer-ul Haq, Raza Sayani

Department of Radiology, Aga Khan University Hospital, Karachi, Pakistan.

PJR January - March 2010; 20(1): 27-29

**Background**

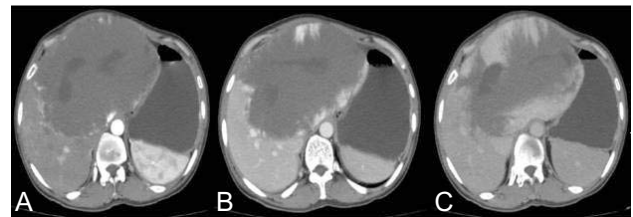Hemangioma is the commonest benign tumor of liver. These mesenchymal tumors are composed of blood vessels that are atypical or irregular in arrangement and size. Usual occurrence is within right lobe of liver in subcapsular or marginal location. Most of them are small in size (less than 4 cm), are often asymptomatic and discovered incidentally on modern diagnostic imaging.<sup>1</sup> If these lesions increase in size and grow large they may give rise to symptoms requiring treatment. Such lesions are called Giant Cavernous hemangiomas.<sup>2</sup> According to Goodman<sup>3</sup> 90% patients having hemangiomas more than 10 cm in size experience symptoms. Radiologists play an important role not only in diagnosing the lesion but also offer treatment like embolization in selected cases.

**Case**

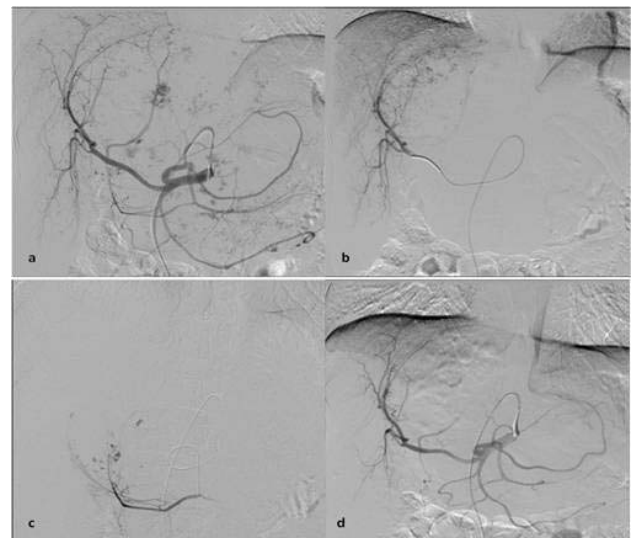
A 48 year old female presented from Afghanistan with history of abdominal pain and feeling of fullness for last 7-8 years with increased intensity of symptoms for last 4-5 months. On examination she had a firm non tender mass with smooth margins in upper abdomen.

A CT scan was carried out which was suggestive of a giant hemangioma with characteristic findings. (Fig. 1). Surgical treatment was planned and in view of large size of mass pre-operative angiography and embolization was carried out to map the anatomy of supplying vessels and to reduce preoperative blood loss (Fig. 2).

**Correspondence :** Dr. Basit Salam  
Department of Radiology,  
Aga Khan University Hospital,  
Stadium Road, P.O Box 3500, Karachi, 74800  
Pakistan. Tel. No. 34930051- Ext 2020  
E-mail: basit.salam@aku.edu



**Figure 1:** Contrast enhanced CT scan. Arterial phase (A), Portovenous phase (B) and delayed phase (C). Note peripheral enhancement of the mass on arterial phase with centripetal progression on venous and delayed phase images.



**Figure 2:** Digital subtraction angiogram of celiac axis: catheter tip is in celiac artery (a) and right hepatic artery (b). Note patches of blush in the mass, arterial supply is from hepatic arteries and from branches of left gastric artery. Microcatheter positioned in branch of left gastric artery (c). Post embolization angiogram (d) no residual blush is evident.

Patient underwent left hepatectomy next day of embolization and the mass was successfully excised. Post operative course was uneventful and patient remained well.

## Discussion

The imaging studies employed in diagnosis of hepatic hemangiomas include Ultrasound, Contrast Enhanced Computed Tomography, Magnetic Resonance Imaging, Technetium (Tc) 99m-labeled RBC scanning and digital subtraction angiography.

The typical appearance on ultrasound is a homogeneous, hyperechoic mass with well-defined margins and posterior acoustic enhancement.<sup>4</sup> Ultrasound combined with doppler are reported to have sensitivity of 69% in detecting hemangiomas.<sup>5</sup> In general practice ultrasound findings of hemangioma are often confirmed with CT scan or MRI. Once the diagnosis is certain the lesion size and progress can be accurately followed by serial ultrasound examinations.

Typical hepatic hemangiomas are often hypodense on precontrast CT scanning. In arterial phase there is peripheral enhancement in the lesion the central portion typically remaining hypodense. In the portal venous and delayed phases the enhancement is usually seen to progress centripetally.<sup>6</sup>

MRI is highly sensitive and specific in the diagnosis of hepatic hemangioma. On MRI these lesions have well defined margins and exhibit low signal on T1 and high signal on T2 weighted images. Contrast uptake and enhancement pattern is in a similar fashion like seen on dynamic CT scanning. With T2-weighted spin-echo and dynamic gadolinium-enhanced T1-weighted gradient-echo sequences, the reported sensitivity and specificity of MR imaging are 98% and the accuracy is 99%.<sup>7</sup>

Radionuclide scintigraphy for identification of hemangiomas is not routinely performed at most centres. It is employed only if diagnosis is not possible by other modalities. On nuclear scanning there is decreased activity on early dynamic images and increased activity on delayed blood pool images obtained over 30-50 minutes.<sup>7</sup> Sensitivity for hemangiomas greater than 2 cm in diameter is as high as 82%, with a specificity of up to 100%.<sup>8</sup>

Role of Radiology is not only limited to diagnosing the hemangiomas rather radiologists now play an important part in management as well. Although treatment of hemangioma has been traditionally thought

to be a surgeon's domain and surgical resection considered as treatment of choice but embarking upon surgery alone may be difficult and risky in some patients due to risk of significant hemorrhage and due to large diffuse nature of lesion and its close proximity to vascular structures. Digital subtraction angiography of such lesions prior to surgery not only helps to identify the blood vessels supplying the mass but also delineate anatomy of adjacent vessels which may not be directly supplying the lesion but are in close relation to it. Furthermore Transarterial embolization results in shrinking of the tumor, thereby minimizing the risk of complications particularly per operative blood loss. Several reports and studies have highlighted the importance of transarterial embolization in treating symptomatic hemangiomas, ruptured hemangiomas and diffuse hemangiomatosis.<sup>1,2,9-11</sup> Embolic material used for this purpose include polyvinyl alcohol, gelfoam, steel coils and isobutyl cyanoacrylate.


Most common complications of embolization are pain, pyrexia, leukocytosis, and nausea, which last for a few days.<sup>1</sup> In our patient we used polyvinyl alcohol particles and there were no complications.

## Conclusion

Radiology plays a vital role in diagnosis and further management of hemangiomas of liver.

## References

1. Vassiou K, Rountas H, Liakou P, Arvanitis D, Fezoulidis I, Tepetes K. Embolization of a Giant Hepatic Hemangioma Prior To Urgent Liver Resection. Case Report and Review of the Literature. *Cardiovasc Intervent Radiol*. 2007 Jul-Aug; **30(4)**: 800-2.
2. Srivastava DN, Gandhi D, Pande GK, Sahni P. Transcatheter arterial embolization in the treatment of symptomatic cavernous hemangiomas of the liver: a prospective study. *Abdom Imaging* 2001 Sep-Oct; **26(5)**: 510-4.

- 
- 
3. Goodman Z. Benign tumors of the liver. In: Okuda K, Ishak KG. Neoplasms of the liver. Tokyo: Springer-Verlag; **1987**:105-25.
  4. Nelson RC, Chezmar JL. Diagnostic approach to hepatic hemangiomas. *Radiology* 1990; **176**: 11-3.
  5. De Franco A, Monteforte MG, Maresca G, et al. [Integrated diagnosis of liver angioma: comparison of Doppler color ultrasonography, computerized tomography, and magnetic resonance]. *Radiol Med.* Jan-Feb 1997; **93(1-2)**: 87-94.
  6. Wolf DC. Hepatic Hemangiomas; Overview. <http://emedicine.medscape.com/article/177106-overview>.
  7. Vilgrain V, Boulos L, Vullierme MP, Denys A, Terris B, Menu Y. Imaging of atypical hemangiomas of the liver with pathologic correlation. *Radiographics* 2000 Mar-Apr; **20(2)**: 379-97.
  8. Kinnard MF, Alavi A, Rubin RA, et al. Nuclear imaging of solid hepatic masses. *Semin Roentgenol.* Oct 1995; **30(4)**: 375-95.
  9. Graham E, Cohen AW, Soulen M, et al. Symptomatic liver hemangioma with intra tumor hemorrhage treated by angiography and embolization during pregnancy. *Obstet Gynaecol* 1993; **81**: 813 6.
  10. Yamamoto T, Kawarada Y, Yano T, et al. Spontaneous rupture of hemangioma of the liver: treatment with transcatheter hepatic arterial embolization. *Am J Gastroenterol* 1991; **86**: 1645 9.
  11. Granov AM, Tarazov PG, Polysalov VW. Arterial embolization in treatment of hepatic cavernous hemangioma. *Khirurgiia (Mosk)* 1999;**4**:13 7