

FRONTONASAL MENINGOENCEPHALOCELE IN 3T MRI; A CASE REPORT

Santanu Mandal,¹ Suadipta Saha,¹ Samiran Samanta,¹ Surajit Das²

¹ Department of Radiodiagnosis, Institute of Post-Graduate Medical Education and Research and Seth Sukhlal Karnani Memorial (IPGME&R and SSKM) Hospital, Kolkata, West Bengal, India

² Department of Radiodiagnosis, Midnapur Medical College and Hospital, Midnapur, India.

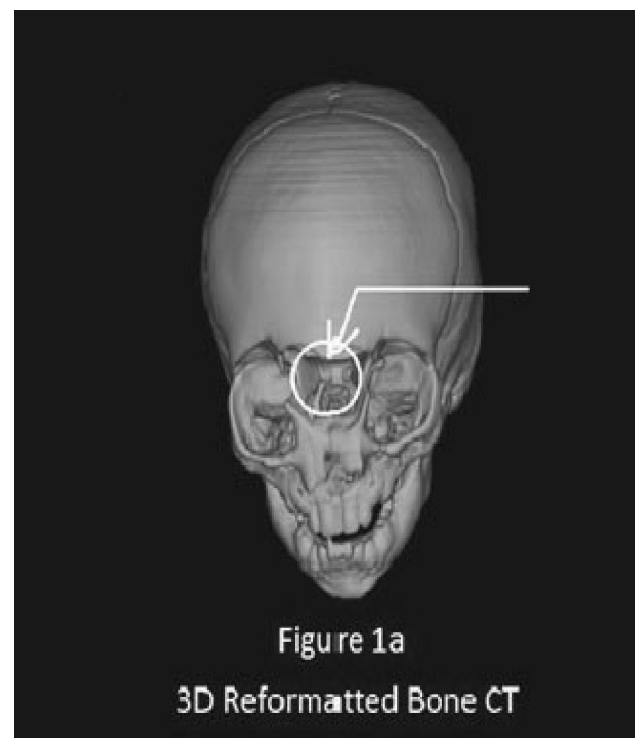
PJR January - March 2016; 26(1): 56-58

ABSTRACT

Cephalocele is a generic term for the protrusion of intracranial contents through acalvarial or skull base defect, when the contents includes brain tissue along with meninges and CSF it is known as Meningoencephalocele. The estimated incidence is 1- 4 per 10,000 live births, with a well recognised geographical variation between sub types. 1, 2 Main two subtypes are Occipital cephalocele and Fronto ethmoidalcephalocele. We report a case in which a Fronto nasal meningoencephalocele in a one year old boy was identified and characterized on CT scan and MR imaging.

Case Report

A 26 years old mother came in the neuro surgical OPD of our institution with her one year old boy who has a large soft swelling over the nose region (Fig. 4) since birth. The swelling is increasing in size with due time. On examination a soft tense cystic mass is noted over the dorsum of his nose and subsequently the child was referred to our department for a detailed imaging evaluation of the lesion. The child had no history of birth asphyxia, trauma, no history of vomiting or any other neurological symptoms or signs is noted. After explaining the process of CT and MRI investigations and obtaining informed written consent from the patient party a CT scan of brain and an MRI of brain was done to delineate the cystic lesion found on previous clinical examination. The 3D bone reformation CT image (Fig. 1A, 1B) & (Fig. 2) shows a bony defect just above the bridge of nose through which brain parenchyma is herniating along with CSF. MRI was performed with a 3.0 Tesla magnet equipped with a head coil. The sedated child was positioned in supine. The following imaging seq-



Correspondence : Dr. Santanu Mandal
Department of Radiology, (IPGME&R and
SSKM) Hospital, Kolkata 700020,
West Bengal, India.
Mobile: +919830294413
Email: santanum@gmail.com

Submitted 23 August 2015, Accepted 21 October 2015

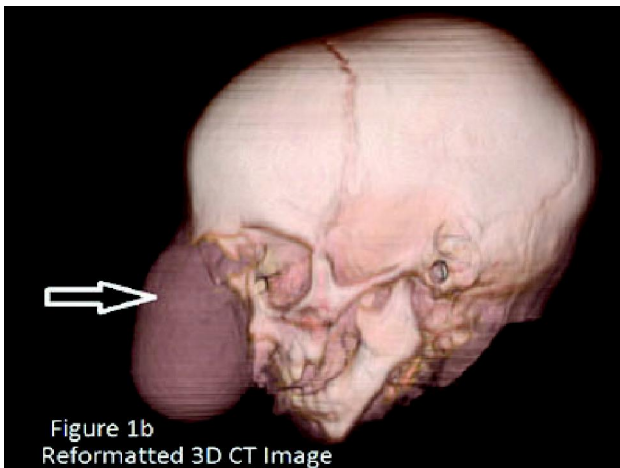


Figure 1b
Reformatted 3D CT Image

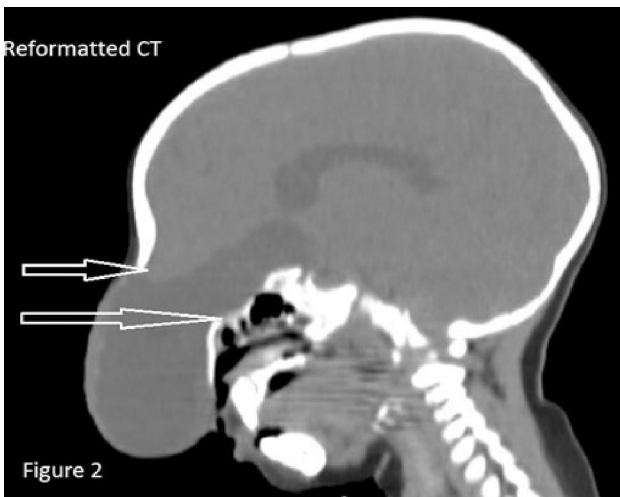


Figure 2

Figure 1 and 2: Shows a bony defect just above the bridge of nose through which brain parenchyma is herniating along with CSF.

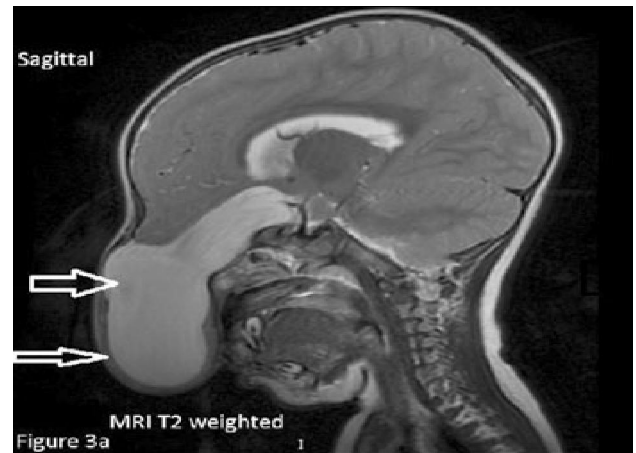

Figure 3a
MRI T2 weighted

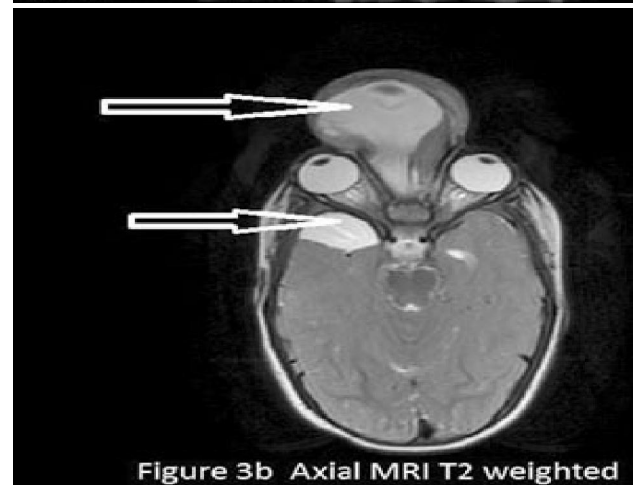

Figure 3b Axial MRI T2 weighted

Figure 3 A-B: MRI showed herniation of frontal brain parenchyma with extra axial CSF and adjoining meninges through a defect in anterior forehead at glabella (unobliterated fonticulus frontalis).

quences were performed: Sagittal T2 weighted (Fig. 3A), TR/TE, 4300/98.8; flip angle 90°; slice thickness, 4mm), Axial T2 weighted (Fig. 3B), TR/TE, 4680/98.7; flip angle, 90°; slice thickness, 5mm), MRI showed (Fig. 3A, 3B) herniation of frontal brain parenchyma with extra axial CSF and adjoining meninges through a defect in anterior forehead at glabella (unobliterated fonticulus frontalis). The lesion measured about 11 cm by 4.4 cm by 6 cm. There is also mass effect in the form of lateral displacement of right orbit. Right temporal region shows a prominent extra axial space (Fig. 3B) without any communications with the ventricles. Tonsillar herniation noted about 1.6 cm. The imaging features suggestive of a frontonasal meningo-encephalocele. (Fig. 4) shows morphological presentation of child with huge congenital abnormality.

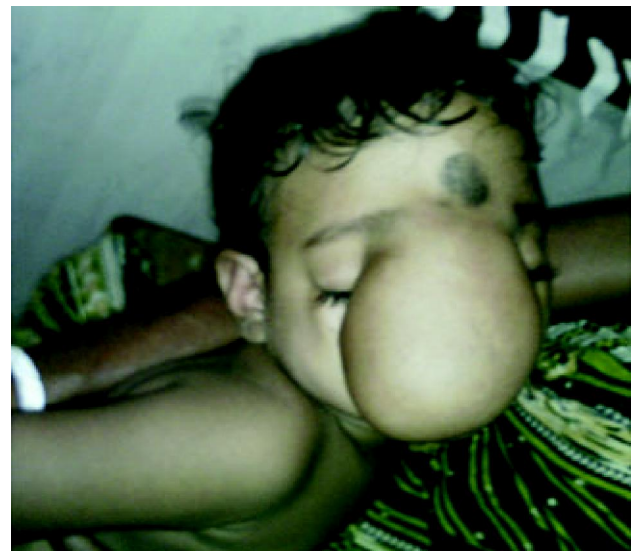


Figure 4: Morphological presentation of child with huge congenital abnormality.

Discussion

Frontonasal meningoencephalocele is the most common (40-60%) of the three subtypes of Fronto ethmoidalcephalocele. Brain parenchyma along with the meninges and CSF protrude through an unobliterated patent fonticulus frontalis into the anterior forehead at the glabella/dorsum of the nose between the frontal bone above and nasal bone below.³ The other two subtypes are nasoethmoidal (30%) and nasoorbital (10%). No gender predilection is noted in fronto ethmoidalencephalocele, however a definite geographical pattern is noted, most commonly to Southeast Asia. Occipital encephaloceles are more common in Europe and North America. Bone CT with 3D reconstruction can show the bone defect at glabella, MR images show a soft tissue mass in direct congruity with intracranial parenchyma with CSF. No contrast enhancement is seen. Major differential diagnosis of frontonasal meningoencephalocele are nasal dermal sinus and nasal cerebral heterotopia (nasal glioma). A multidisciplinary management is recommended in the diagnosis and treatment of meningoencephalocele. Surgical procedures include removal and anterior fossa defect reconstruction by craniotomy.⁴ A multilayer repair is preferred not only to stop the CSF leak, but to reinforce the thin skull base and prevent meningoencephalocele recurrence.⁵

Competing interests:

The authors declare that they have no financial or personal relationships which may have inappropriately influenced them in writing this article.

References

1. Lo BW, Kulkarni AV, Rutka JT et-al. Clinical predictors of developmental outcome in patients with cephaloceles. *J Neurosurg Pediatr.* 2008; **2(4)**: 254-7.
2. Baradaran N, Nejat F, Baradaran N et-al. Cephalocele: report of 55 cases over 8 years. *Pediatr Neurosurg.* 2009; **45(6)**: 461-6.
3. Oucheng N et al: Fronto ethmoidalmeningoencephalocele: appraisal of 200 operated cases. *J Neurosurg Pediatr.*
4. B. McCormack, P. R. Cooper, M. Persky, and S. Rothstein, "Extracranial repair of cerebrospinal fluid fistulas: technique and results in 37 patients," *Neurosurgery* 1990; **27(3)**: 412-7.
5. V. K. Anand, R. K. Murali, and M. J. Glasgold, "Surgical decisions in the management of cerebrospinal fluid rhinorrhoea," *Rhinology* 1995; **33(4)**: 212-8.