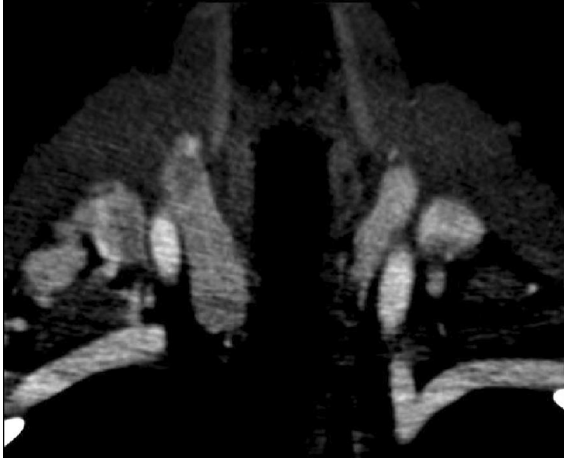


QUIZ 1

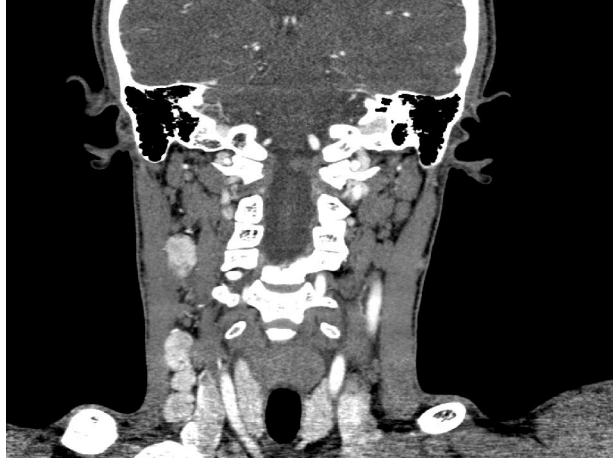
Submitted by: Hina Javed, Shehzad Baber Kureshi

Advanced Radiology Clinic, (Pvt.) Ltd., Karachi, Pakistan

PJR April - June 2010; 20(2): 106-107



A



B

Questions

- Q1. What are the CT findings in image A?
- Q2. What are the CT findings in image B?
- Q3. What is your probable diagnosis?
- Q4. What is the diagnostic criteria of papillary carcinoma of thyroid on CT?
- Q5. What are the types of malignant tumors of thyroid gland?

QUIZ 1

Answers

Answer 1: There are two hypodense nodular lesions in the right lobe of the thyroid gland.

Answer 2: There are multiple enlarged enhancing cervical lymph nodes in right cervical chain.

Answer 3: Papillary carcinoma of thyroid with metastatic lymph nodes.

Answer 4: Lymph node metastases are common in papillary carcinoma, 50% at presentation, and less common in follicular carcinomas. The metastatic nodes in papillary carcinoma may enhance markedly (hypervascular) and may have punctuate calcifications.

Answer 5: Papillary carcinoma is the most common malignant tumor (80%) followed by follicular (20% to 25%); medullary (5%); undifferentiated; anaplastic carcinomas (< 5%); lymphoma (5%); and metastases.

References

Weber AL, Randolph G, Aksoy FG. The thyroid and parathyroid glands. CT and MR imaging and correlation with pathology and clinical findings. *Radiol Clin North Am.* 2000 Sep; **38(5)**:1105-29.