

# EFFICACY OF LUGOL'S IODINE FOR THYROID BLOCKADE IN DIAGNOSTIC $^{131}\text{I}$ MIBG SCAN.

Maseeh uz Zaman,<sup>1,2</sup> Mansoor Naqvi,<sup>1</sup> Nosheen Fatima,<sup>2</sup> Riffat Hussain,<sup>1</sup> Zafar Sajjad,<sup>1</sup> Gufran Khan,<sup>1</sup> Khalil Khan<sup>1</sup>

<sup>1</sup> Nuclear Medicine Section, Department of Radiology, Aga Khan University Hospital, Karachi, Pakistan

<sup>2</sup> Department of Nuclear Medicine, KIRAN, Karachi, Pakistan

PJR April - June 2010; 20(2): 84-86

## ABSTRACT

**BACKGROUND:** Radioiodine labelled Meta IodoBenzyl Guanidine (MIBG) is a noradrenaline analogue used for diagnosis and treatment of neuroendocrine tumor and there is high incidence of primary hypothyroidism after  $^{131}\text{I}$ -MIBG inspite of thyroid blockade. The aim of this study was to observe the efficacy of thyroid blockade in patients having diagnostic  $^{131}\text{I}$  MIBG scan. **MATERIAL AND METHODS:** This is a retrospective study conducted at Section of Nuclear Medicine, Department of Radiology, Aga Khan University Hospital, Karachi from 2004 till 2010. It includes all patients who were referred for a diagnostic  $^{131}\text{I}$  MIBG study. Patients were advised to start Lugol's Iodine a day before test and subsequent 5 days to block the thyroid gland. 1mCi (0.9-1.2 mCi) of  $^{131}\text{I}$  MIBG was administered intravenously over 3-5 minutes followed by whole body image acquisition at 4, 24, 48, 72, 96 and 120 hours after injection. Images were analyzed for abnormal tracer deposition as well as thyroid uptake. Serum TSH level was found by checking hospital record (inside referral) and telephonic inquiry (outside referral). A serum TSH level  $>4$  mU/l was considered suggestive of hypothyroidism. **RESULTS:** 31 consecutive patients (M:F 19:12, Mean age: 28 years) who had diagnostic  $^{131}\text{I}$  MIBG scan from 2004-2010 were included. Ten scans revealed abnormal uptake over site of primary tumor or recurrence while thyroid uptake was not appreciated in any patient (4-120 hrs studies). Serum TSH level was available in 11 patients (performed 3 - 32 months after procedure) and were normal. **CONCLUSION:** We conclude that thyroid blockade using Lugol's iodine in patients undergoing diagnostic  $^{131}\text{I}$  MIBG ensures complete thyroid blockade with no evidence of primary hypothyroidism.

**Key words:** MIBG, Hypothyroidism, Lugol's Iodine, Pheochromocytoma, Neuroblastoma.

## Introduction

MIBG is a noradrenaline analogue used to image tumors of neuroendocrine origin, to study disorders of sympathetic innervations in ischemic and non-ischemic cardiomyopathy as well as in the differentiation between idiopathic Parkinson's syndrome and multisystem atrophy. MIBG can be labelled with either  $^{131}\text{I}$  (gamma emission of 364 Kev and beta emission 0.6 MeV) or  $^{123}\text{I}$  (pure gamma emission of 160 Kev). The diagnostic dose for  $^{131}\text{I}$  MIBG should be 1.2–2.2 mCi (0.9–2.2 mCi for children).<sup>1</sup> Higher doses of  $^{131}\text{I}$  MIBG ( $> 30$  mCi) are used for therapeutic purpose.

MIBG does not normally concentrate in thyroid, but due to instability as well as metabolism by the liver, free  $^{131}\text{I}$  or  $^{123}\text{I}$  is formed and gets accumulated in normal thyroid gland.<sup>2</sup> Effects of radioiodine on the thyroid can vary from hypothyroidism, thyroiditis, thyroid nodules, and single follicular adenomas to malignancies.<sup>3,4</sup> The administration of Radioactive Substance Advisory Council (ARSAC) guideline<sup>5</sup> recommends blocking thyroid whenever dose to thyroid gland is expected to be greater than 50 mGy. As a matter of fact small quantities of radioiodine ( $^{123}\text{I}$  0.4 mCi and  $^{131}\text{I}$  0.003 mCi) can give such radiation exposure to thyroid, therefore, it is recommended that thyroid should be blocked in diagnostic and therapeutic procedures using radioiodine labelled MIBG.<sup>6</sup>

**Correspondence :** Dr. Maseeh uz Zaman  
Department of Radiology,  
Aga Khan University Hospital,  
Stadium Road, P.O Box 3500, Karachi, 74800  
Pakistan. Tel. No. 34930051 - Ext 2020  
E-mail: maseeh.uzzaman@aku.edu

Thyroid blockade is achieved by administering stable iodine preferably 1 day prior or even immediately before the radioiodinated MIBG administration. The protection of the thyroid with stable iodide is based first on dilution and second on a down regulation of the sodium-iodide-symporter, both resulting in a lower uptake of radioiodide.<sup>7,8</sup> However, there are reports of thyroid dysfunction in a variable percentage of children who were treated with <sup>131</sup>I-MIBG with thyroid blockade.<sup>9,10</sup>

The aim of this study was to observe the efficacy of thyroid blockade in patients having diagnostic <sup>131</sup>I MIBG scan.

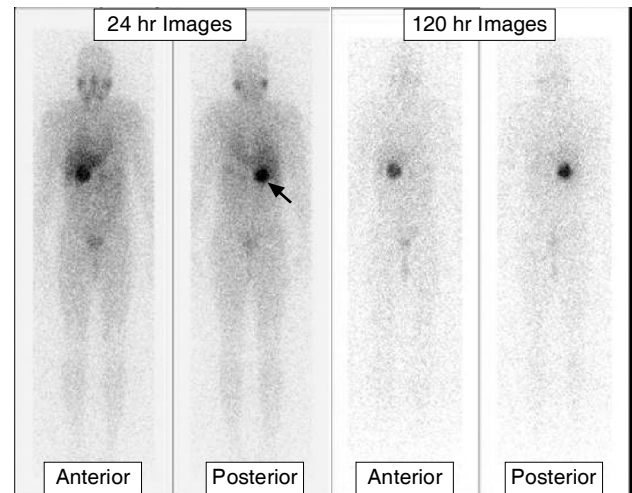
## Materials and Methods

This is a retrospective study conducted at Section of Nuclear Medicine, Department of Radiology, Aga Khan University Hospital, Karachi from 2004 till 2010. It includes all patients who were referred for a diagnostic <sup>131</sup>I MIBG study for a known or suspected neuroendocrine tumor. Medications which might interfere with MIBG uptake were stopped after consulting the referring physicians. Patients were advised to start Lugol's Iodine (supplied by Aga Khan Pharmacy) [16 mg/kg/day for neonate, 32 mg/kg/day for infant, 65 mg/kg/day for adult, upto a maximum dose of 130 mg/kg/day] a day before test and subsequent 5 days to block the thyroid gland. 1mCi (0.9-1.2 mCi) of <sup>131</sup>I MIBG was administered intravenously over 3-5 minutes followed by flushing with normal saline. Whole body images were acquired under double head gamma camera (Ecam, Siemens) with high energy collimators at a speed of 5 cm/minute at 4, 24, 48, 72, 96 and 120 hours after injection. Images were analyzed for abnormal tracer deposition as well as thyroid uptake. Availability of serum TSH level was found by checking hospital record (inside referral) and telephonic inquiry (outside referral) after the diagnostic scan (3 - 32months). A serum TSH level >4 mU/l was considered suggestive of hypothyroidism.

## Results

We included all 31 consecutive patients (M:F 19:12, mean age 28 [age range 3-71] years) who had

diagnostic <sup>131</sup>I MIBG scan from 2004-2010. The procedure was indicated for diagnosis of pheochromocytoma (16 patients), neuroblastoma (3 patients) and for assessment of recurrence or residual pheochromocytoma (05 patients) or neuroblastoma (07 patients). Ten scans revealed abnormal uptake over site of primary tumor or recurrence while thyroid uptake was not appreciated in any patient on 4-120 hrs studies (Fig. 1).



**Figure 1:** 24 and 120 hr whole body diagnostic <sup>131</sup>I MIBG images showing uptake (arrow) over right sided pheochromocytoma but no evidence of thyroid uptake.

Serum TSH level was available in 11 patients (performed 3 - 32 months after procedure) and all were within normal limits. These findings are consistent with complete thyroid blockade with no evidence of <sup>131</sup>I induced hypothyroidism.

## Discussion

Primary hypothyroidism after therapeutic doses of <sup>131</sup>I MIBG is a fairly common side effect especially in children treated with repeated doses.<sup>10</sup> Hanneke et al.<sup>11</sup> reported thyroid uptake in 21% scans and clinical hypothyroidism in 64% of survivor of neuroblastoma patients treated with <sup>131</sup>I MIBG inspite of thyroid blockade. To the best of our knowledge, there is no reported case of primary hypothyroidism after a diagnostic <sup>131</sup>I MIBG scan with thyroid blockade. In our study, we did not find any evidence of thyroid uptake of <sup>131</sup>I MIBG till 120 hr in any patient. Similarly, serum TSH level in 11 patients did not show any evidence of late onset of primary hypothyroidism. In

remaining 20 patients serum TSH was not available and this is a limitation of the study. These evidences unequivocally support the highly effective thyroid blockade using Lugol's iodine at our Institute. High incidence of primary hypothyroidism (inspite of thyroid blockade) in therapeutic group is explained by different biodistribution of MIBG resulting in visualization of thyroid gland and subsequent elevated TSH levels inspite of thyroid blockade.<sup>12</sup> This discrepancy between diagnostic and therapeutic <sup>131</sup>I MIBG demands use of other options (in addition to stable iodine) to effectively block the thyroid to avoid the possibility of primary hypothyroidism in survivors.

We conclude that thyroid blockade using Lugol's iodine in patients undergoing diagnostic <sup>131</sup>I MIBG ensures complete thyroid blockade with no evidence of primary hypothyroidism.

## References

1. Olivier P, Colarinha P, Fettich J, Fischer S, Frokier J, Giammarile F, et al. Guidelines for radioiodinated MIBG scintigraphy in children. *Eur J Nucl Med Mol Imaging* 2003; **30**:B45-50.
2. Wafelman AR, Hoefnagel CA, Maessen HJ, Maes RAA, Beijnen JH. Renal excretion of iodine-131 labelled meta-iodobenzylguanidine and metabolites after therapeutic doses in patients suffering from different neural crest-derived tumors. *Eur J Nucl Med*. 1997; **24**:544-52.
3. Nauman J, Wolff J. Iodide prophylaxis in Poland after the Chernobyl reactor accident: benefits and risks. *Am J Med*. 1993; **94**:524-32.
4. Shalet SM, Rosenstock JD, Beardwell CG, Pearson D, Jones PH. Thyroid dysfunction following external irradiation to the neck for Hodgkin's disease in childhood. *Clin Radiol*. 1977; **28**:511-15.
5. ARSAC Notes for Guidance. *Nucl Med Comm* 2002; 21Supl, p S29-30.
6. Emilio B, Francesco G, Cumali A, Richard PB, Angelika BD, Lorenzo M. et al. <sup>131</sup>I/<sup>123</sup>I Metaiodobenzylguanidine (MIBG) scintigraphy: procedure guidelines for tumour imaging. *Eur J Nucl Med Mol Imaging* DOI 10.1007/s00259-010-1545-7.
7. Dunn JA, De Groot LJ, Henneman G. The thyroid and its diseases, Chapter 2. 2000 [accessed September 9, 2010]. <http://www.thyroidmanger.org>.
8. Verger P, Aurengo A, Geoffroy B, Le Guen B. Iodine kinetics and effectiveness of stable iodine prophylaxis after intake of radioactive iodine: a review. *Thyroid*. 2001;**11**: 353-60.
9. Garaventa A, Guerra P, Arrighini A, Bertolazzi L, Bestagno M, De Bernardi B. et al. Treatment of advanced neuroblastoma with I-131 metaiodobenzylguanidine. *Cancer*. 1991; **67**:922-8.
10. Picco P, Garaventa A, Claudiani F, et al. Primary hypothyroidism as a consequence of <sup>131</sup>I-metaiodobenzylguanidine treatment for children with neuroblastoma. *Cancer* 1995;**76**:1662-4.
11. Hanneke Ms, Jan de K, Berthe L F, Jan JM, Thomas V. High Incidence of Thyroid Dysfunction Despite Prophylaxis with Potassium Iodide During <sup>131</sup>I-metaiodobenzylguanidine. *Cancer* 2002; **94**: 2081-9.
12. Marc PH, Martin C, John MM, Patricia B, Tammy IK, Hongming Z, et al. Biodistribution of post-therapeutic versus diagnostic <sup>131</sup>I-MIBG scans in children with neuroblastoma. *Pediatric Blood & Cancer* 2004; 268-74.