

# THE IMPACT OF MULTI SLICE COMPUTED TOMOGRAPHY IN THE DIAGNOSIS OF ACUTE CHEST PAIN

Iman Abbas Hosny

Department of Radiodiagnosis, Faculty of Medicine, Cairo University, Cairo, Egypt.

PJR April - June 2010; 20(2): 58-66

## ABSTRACT

**OBJECTIVE:** To address the clinical value of recent advances of Multislice Computed Tomography in the diagnosis of the major life –threatening causes of acute chest pain. **SUBJECTS AND METHODS:** Twenty five patients with atypical acute chest pain and low to intermediate cardiovascular risk underwent dedicated coronary CT angiography (CCTA). Other 15 patients with high clinical suspicion of pulmonary embolism or aortic dissection were referred for conventional CT angiography. The CT was carried on using GE light speed VCT 64. **RESULTS:** Of the 25 patients suspected to have coronary artery disease, 2 patients showed non diagnostic quality scans due to extensive coronary artery calcification and 13 patients showed positive CCTA findings with only 3 showing significant > 50% stenosis. On the other hand ,6 patients out of the 15 suspected to have pulmonary embolism or aortic dissection showed positive findings. **CONCLUSION:** CCTA provides the potential to rapidly and reliably diagnose or exclude acute coronary syndrome in patients with acute chest pain but low to intermediate cardiovascular risk. CT is also a well established tool for the diagnosis of acute aortic dissection and pulmonary embolism. Recent technical developments now permit acquisition of well-opacified images of the coronary arteries, thoracic aorta and pulmonary arteries from a single CT scan. While this so called triple-rule out scan protocol can potentially exclude fatal causes of chest pain in all three vascular beds, the attendant higher radiation dose of this method precludes its routine use except in selected cases .

**Key Words :** MSCT acute chest pain ; CCTA ; MSCT coronary disease ; MSCT aortic dissection; MSCT pulmonary embolism .

## Introduction

The most clinically relevant conditions causing chest pain that have to be differentiated in the Emergency Department (ED) are pulmonary embolism, acute aortic syndrome, and coronary artery disease presenting as acute coronary syndrome. The classic initial approach for evaluation of acute chest pain consists of a detailed patient history, physical examination, ECG, and measurement of cardiac biomarkers. Immediate coronary catheterization is mandatory for high risk patients with typical chest pain.<sup>1</sup> In contrast, patients with acute chest pain but

low to intermediate risk, coronary CT angiography provides the potential to rapidly and reliably diagnose or exclude acute coronary syndrome.<sup>2</sup> Recent advances in computed tomography (CT) technology have made high resolution noninvasive coronary angiograms possible. Multiple studies involving over 2,000 patients have established that coronary CT angiography (CCTA) is highly accurate for delineation of the presence and severity of coronary atherosclerosis. The high negative predictive value (97%) found in these studies suggests that CCTA is an attractive option for exclusion of coronary artery disease in properly selected emergency department patients with acute chest pain.<sup>3,4</sup> In addition ,given the widespread use and proven clinical accuracy of

**Correspondence :** Dr. Iman Abbas Hosny  
A. Professor of Radiodiagnosis,  
Faculty of Medicine, Cairo University,  
Cairo, Egypt.  
E-mail: imanabbas95@yahoo.com

CT angiography for diagnosis of acute aortic dissection<sup>5</sup> and pulmonary embolism,<sup>6</sup> a triple rule out CT scan protocol is an attractive option in the ED. Recent technical developments now permit acquisition of well-opacified images of the coronary arteries, thoracic aorta and pulmonary arteries from a single CT scan. However, the higher radiation dose of this method and the clinical evidence of the very low incidence of occult pulmonary embolism and aortic dissection without suggestive symptoms and signs precludes its routine use except in selected cases.<sup>7</sup>

## Subjects and Methods

Twenty five patients (20 male and 5 female with an age range from 48 to 78 year) presented with atypical acute chest pain and low to intermediate cardiovascular risk and were referred from the emergency department and outpatient clinics to the radiological department after traditional management protocol that included a detailed patient history, physical examination, ECG, and measurement of cardiac biomarkers. The widely used Thrombolysis in Myocardial Infarction (TIMI) risk score applies one point to each of the following risk factors: age greater than 65 years, known coronary artery disease (documented previous coronary artery stenosis > 50%), severe angina (more than two episodes of chest pain in the preceding 24 hours), ST-segment changes (persistent depression or transient elevation) on admission ECG, elevated serum markers of myocardial ischemia (troponins), use of aspirin in the 7 days before presentation, and three or more conventional risk factors for coronary artery disease (family history, diabetes mellitus, hypertension, hypercholesterolemia, smoking).<sup>8</sup> According to this stratification scheme, patients at intermediate risk (TIMI score, 3–4) and low risk (TIMI score, 0–2) were referred to the radiological department for dedicated coronary CT angiography. Examination was carried in accordance with the ethical standards and all patients gave informed consent for inclusion in the study. A non enhanced scan was performed prior to contrast examination for coronary artery calcium scoring. This scan was also useful to determine the exact scan of coverage and to familiarize the patients with the

procedure and breath hold commands. Four patients with very high calcium score (>1000 Agatston units) were excluded. Patients were premedicated with beta blocking drugs to reduce the heart rate to 65 beats/minute. Also, sublingual nitroglycerine was administered directly prior to scan to enhance image quality. Other 15 patients (11 male and 4 female with an age range 44 to 76 year) with high clinical suspicion of pulmonary embolism or aortic dissection were also referred for conventional CT angiography that incorporated wider anatomical region from the lung apices to the costophrenic angles or even extending to the abdomen and pelvis in case of aortic dissection. Also, higher pitch value and thick reconstruction images were used. The CT examination was carried on using light speed VCT 64 (GE medical systems). The applied protocol for CCTA is shown in (Tab. 1).

| Parameter                      | Detail                               |
|--------------------------------|--------------------------------------|
| Scan                           |                                      |
| Range                          | Tracheal carina to dome of diaphragm |
| Direction                      | Craniocaudal                         |
| Time                           | 10-14 s, depending on heart rate     |
| Tube settings                  |                                      |
| Voltage                        | 120 kVp                              |
| Current                        | 400 -700 mAs                         |
| Acquisition                    |                                      |
| Slice collimation              | 0.6 mm                               |
| Acquisition                    | 64 x 0.6 mm                          |
| Rotation time                  | 0.35 s                               |
| Pitch                          | 0.2-0.3, depending on heart rate     |
| Bolus timing                   |                                      |
| Region of interest positioning | Ascending aorta                      |
| Contrast administration        |                                      |
| Iodine concentration           | 370 mg I/mL                          |
| Volume                         | 80 mL                                |
| Flow rate                      | 5 mL/s                               |
| Saline                         | 30 mL                                |

Table 1: CCTA Protocol

## Results

Of the 25 patients suspected to have coronary artery disease, 4 patients were excluded due to very high calcium score (> 1000 Agatston units) and were referred for invasive coronary angiography. Six patients

showed normal CCTA findings, 2 patients showed non diagnostic quality scans due to extensive coronary artery calcification ( 560 and 820 Agatston units ) and 13 patients showed positive CCTA findings with only three showing significant > 50% stenosis. Of the remaining 10 patients with positive CCTA findings ,8 showed minimal <25% stenosis and the last 2 cases showed mild to moderate 25 to 50 % stenosis. All 13 cases and the 2 cases with extensive coronary artery calcification underwent invasive angiography with good correlation with the CCTA findings in the former 13 cases, except in 1 case which showed moderate stenosis that appeared minimal on CCTA .On the other hand, 6 patients out of the 15 suspected to have pulmonary embolism or aortic dissection showed positive findings on CT angiography.

## Discussion

In our study ,we performed 2 different CT protocols for patients with acute chest pain depending on the clinical suspicion .Those with suspected coronary artery disease underwent dedicated CCTA examination. Whereas patients with clinical suspicion of aortic dissection or pulmonary artery embolism underwent conventional CT angiography .Although the so called triple rule-out scan protocol for simultaneous exclusion of all three potentially fatal causes of acute chest pain is an attractive option. Yet , 2 points were taken into consideration and preclude its use in our limited study. First, the clinical evidence of the very low incidence of occult pulmonary embolism and aortic dissection without suggestive symptoms and signs. Second, the considerable higher radiation dose of this method. It is true that technical advances of the 64-scanners have allowed wider anatomic coverage and faster movement of the patient through the scan plane ,thus reducing the scan duration to under 20 sec in most cases.<sup>9</sup> Also, the advances of the radiographic injectors allowed combined simultaneous evaluation of the pulmonary, coronary, and thoracic aorta by using tri-phasic injection protocol that delivered the standard 100 mL of iodinated contrast at 5 mL/sec typical for CCTA examinations, followed by an additional 30 mL at 3 mL/sec to maintain pulmonary artery opacification, followed by a standard saline flush injection. Mean

coronary artery, pulmonary artery and aortic enhancement values were consistently higher than 250 Hounsfield Units, and right atrial enhancement did not interfere with interpretation of the coronary arteries.<sup>10</sup> In spite of these technical advances, important radiation safety concerns remain that should limit indiscriminate application of a “triple rule-out” scan protocol. The effective radiation dose of a scan is calculated as the dose-length product (measured and displayed by the scanner on each patient) multiplied by the European Commission thoracic conversion factor (0.017) to yield the effective dose in milliSieverts (mSv). Thus, the radiation dose is directly proportional to the scan length in centimeters. Compared to the usual radiation dose of a standard CCTA (generally ranging from 8-22 mSv, depending on body habitus, gender and scan protocol), the effective radiation dose of a “triple rule-out” scan is often increased by 50%, simply because of the increased field of view.<sup>11</sup>

CCTA is emerging as a powerful tool for the diagnosis and characterization of coronary artery disease. Previous 64-slice CCTA studies revealed a sensitivity and specificity of 98% and 93 % respectively for detection of significant coronary artery disease with a high negative predictive value of 97%. These data support the hypothesis that a normal CCTA may obviate the need for invasive angiography in properly selected clinical circumstances.<sup>12,13</sup>

In our study, 6 patients with acute chest pain, low to intermediate cardiovascular risk showed normal CCTA. The 4 excluded cases with very high calcium score (>1000 Agatston units ), the 13 cases with variable degrees of coronary artery stenosis and the 2 cases with inadequate scans due to extensive coronary artery calcification were referred for correlation with invasive coronary angiography (Fig. 3,4,5). In spite of the limited number of cases, obviating statistical analysis, yet there was good correlation with the CCTA findings except in 1 case which showed moderate stenosis that appeared minimal on CCTA .

CCTA provides anatomical data regarding the coronary lumen and the presence of stenosis. However, as with invasive coronary angiography, such anatomical data alone do not necessarily provide insight regarding the physiological impact of a given lesion on coronary blood flow. However, CCTA does provide data not available from invasive angiography alone. Analogous

to intravascular ultrasound, CCTA provides striking images of the vessel wall. The 3-dimensional data provided by CCTA also facilitate delineation of the course of anomalous coronary vessels and other congenital anomalies. A CCTA also can evaluate other cardiac anatomy, including atria, ventricles, valves, pericardium, great vessels, feeding tributary veins, the coronary venous system.<sup>14</sup> In our limited study, no anomalous coronary vessels nor congenital anomalies were detected.

It is important to emphasize the present limitations of CCTA. A CCTA may not provide technically adequate images of all segments in all arteries in every patient. This may be related to obesity, fast or irregular heart rates, or respiratory motion. As emphasized, a major limitation is that CCTA presently provides data regarding anatomical lesions only, not their physiological impact on coronary blood flow. Future advances may facilitate combined anatomic and perfusion imaging by CCTA.<sup>15</sup> Extensive coronary calcium obscures the lumen and may substantially limit analysis of segments or even entire arteries by CCTA. Thus, this technique may be of limited application in patients with a high likelihood of significant coronary calcification, such as the elderly or in patients with prior calcium scores >1,000 Agatston units.<sup>16</sup> Similarly, CCTA also has technical limitations for assessment of in-stent stenoses.<sup>17</sup>

In our study, 4 patients were excluded due to very high calcium score (> 1000 Agatston units) and 2 patients showed inadequate CCTA scans due to extensive coronary calcification (560 and 820 Agatston units). These patients were evaluated by invasive coronary angiography.

On the technical side, all available means should be used to lower radiation dose. One of these steps is simply lowering the tube voltage for imaging of slim persons, which can reduce radiation exposure as much as 88%. A more advanced technique is ECG-dependent tube current modulation, by which radiation dose is automatically lowered during cardiac phases that are undesirable for morphologic image reconstruction (typically systole). Use of this technique can reduce radiation dose as much as 44%. With these approaches, radiation for a dual-source CT coronary angiogram, for instance, may result in an estimated mean effective dose of 7.8–8.8 mSv.<sup>18</sup>

The most significant radiation dose savings have been reported with the recently re-introduced prospective ECG-triggering approach. Use of this acquisition technique ordinarily results in diagnostic image quality for almost all coronary segments, maintenance of accuracy for detection of coronary artery stenosis, and drastically reduced radiation dose (1.2–4.4 mSv).<sup>19</sup> This technique, however, has been recognized to be highly sensitive to high and irregular heart rates. Thus its use should be restricted to patients with stable and slow (< 65–70 beats/min) heart rates. Technical developments such as broadening the portion of the RR-interval during which radiation is applied (ECG padding) and adaptive online monitoring of the ECG for the occurrence of extra systoles are expected to increase the number of patients who can successfully undergo imaging with this technique. The potential of using prospectively ECG-triggered CT acquisition techniques in the assessment of chest pain in ED patients is being explored.<sup>20</sup> In our study, a retrospective ECG-gating was used and the total radiation dose for the patients ranged from 13 to 22 mSv.

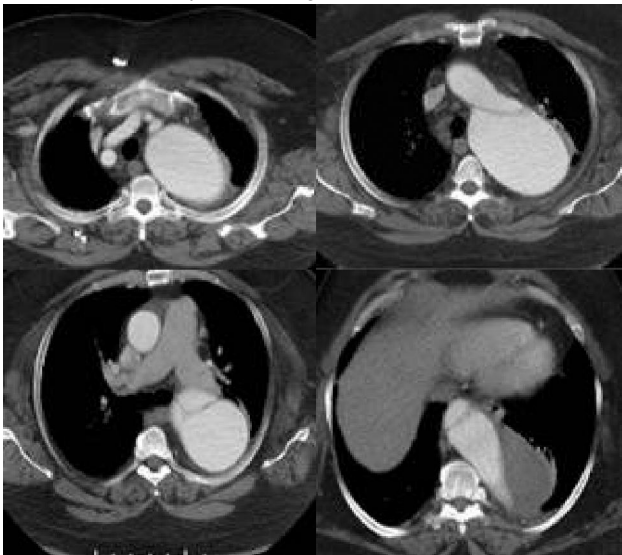
Classic Aortic Dissection is the most common entity causing an acute aortic syndrome (70%). The term Acute Aortic Syndrome (AAS) is used to describe three closely related emergency entities of the thoracic aorta: classic Aortic Dissection (AD), Intramural Hematoma (IMH) and Penetrating Atherosclerotic Ulcer (PAU).

Clinically these conditions are indistinguishable. CT is the most accurate imaging modality for the initial diagnosis, differentiation and staging of AAS. The main goal for the radiologist is not only to detect which entity is causing the clinical problem, but more importantly to differentiate between type A and B according to Stanford classification.

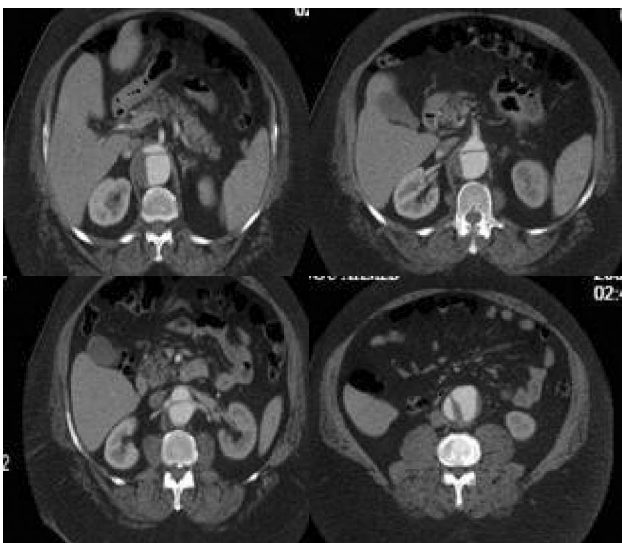
Stanford Type A lesions involve the ascending aorta and aortic arch and may or may not involve the descending aorta. Stanford Type B lesions involve the thoracic aorta distal to the left subclavian artery. The Stanford classification has replaced the De Bakey classification (type I= ascending, arch and descending aorta, type II= only ascending aorta, type III= only descending aorta).<sup>21</sup> Another example of MSCT power is the ability to detect pulmonary emboli. Shorter breath hold times, thinner reconstructions and greater contrast

opacification of the pulmonary arteries now produce higher quality scans to detect pulmonary emboli.<sup>22</sup> In our study, 15 patients with acute chest pain and suspected to have acute aortic dissection or pulmonary embolism were evaluated by CT angiography. Only 6 cases showed positive findings, 3 cases of pulmonary embolism involving the main pulmonary arteries and 3 cases of aortic dissection, 1 of type A and 2 of type B (Fig. 1,2).

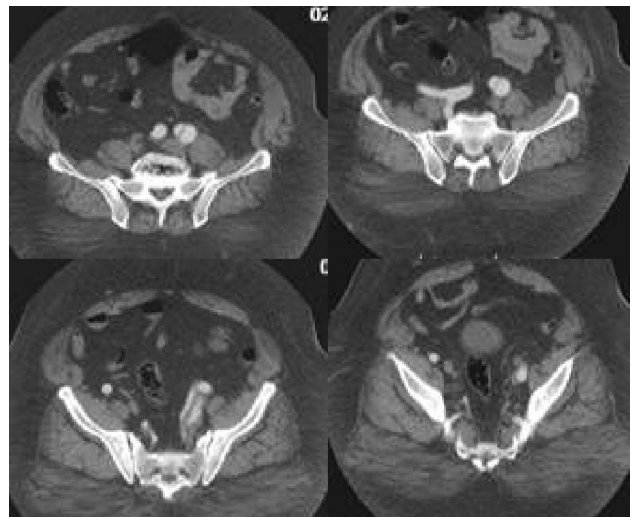
**Figure 1 (A-B-C-D):** CTA of type B or 3 aortic dissection in 75 years old hypertensive man presenting in the ED with acute chest pain radiating to the back.



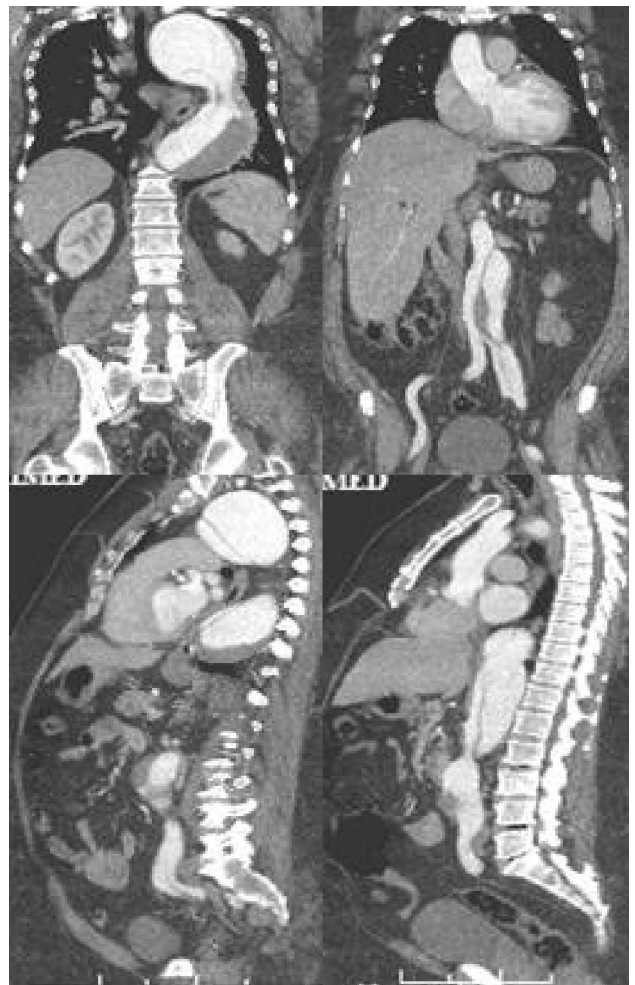
**Figure 1A:** Axial CTA showing the intimal flap in the proximal descending aorta extending distally with aneurysmal dilatation of the partially thrombosed false lumen that swipes around the small true lumen.



**Figure 1B:** Axial CTA showing the spiral extension of the intimal flap with the celiac trunc, superior mesenteric artery and right renal artery originating from the true lumen and left renal artery from the false one.

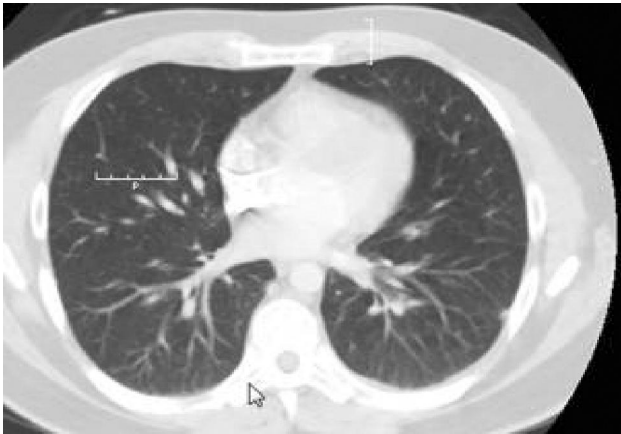

**Figure 1C:** Axial CTA showing the extension of aortic dissection down to the left common and internal iliac arteries.



**Figure 1D:** Coronal and Sagittal reconstruction CTA showing precisely the entire extension of the partially thrombosed aortic dissection from the proximal descending aorta down the left internal iliac artery.

**Figure 2 (A-B):** CTA of left main pulmonary artery aneurysm in a 68 year old man with history of total hip replacement 2 weeks before presenting in the ED with acute chest pain and shortness of the breath.

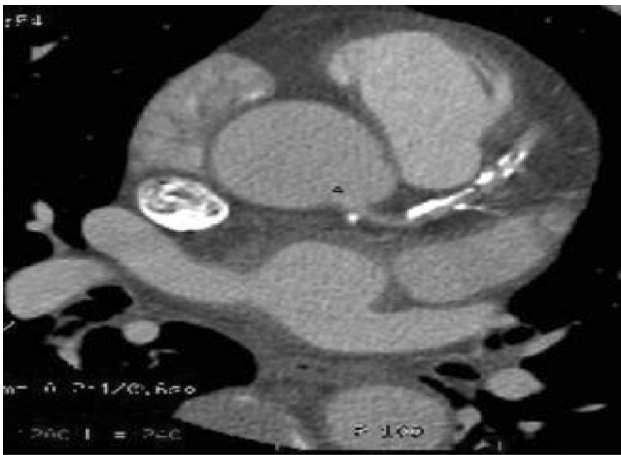


**Figure 2A:** Axial CTA showing filling defect of the opacified distal left main pulmonary artery.

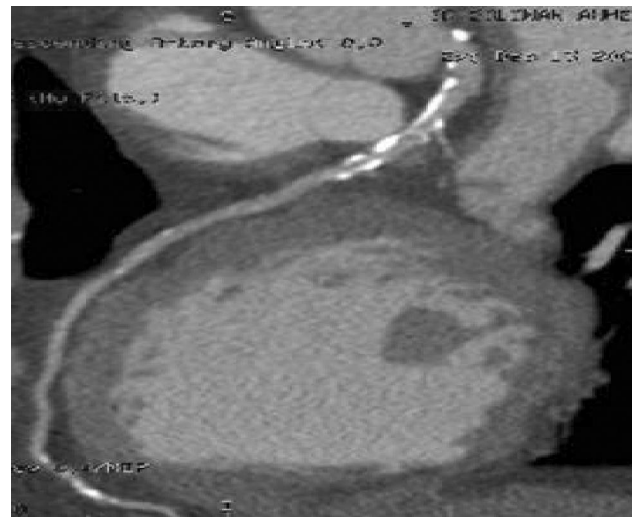


**Figure 2B:** Coronal reconstruction CTA showing nicely the left main pulmonary artery non opacified embolus .

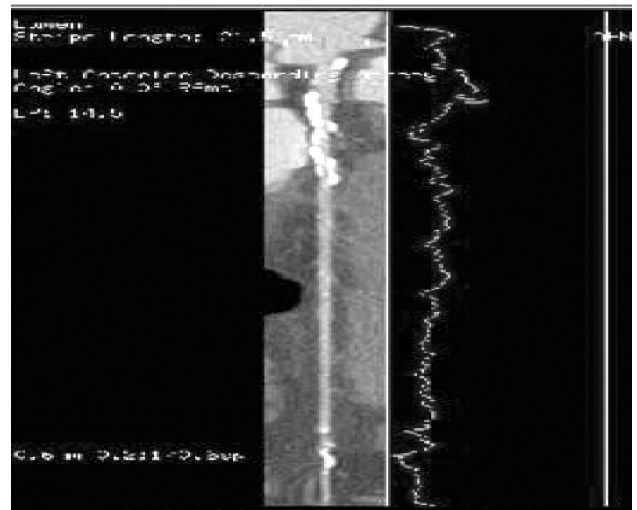
**Figure 3(A-B-C-D):** CCTA of 73 year old diabetic male with no prior history of coronary disease and presenting with acute chest pain.



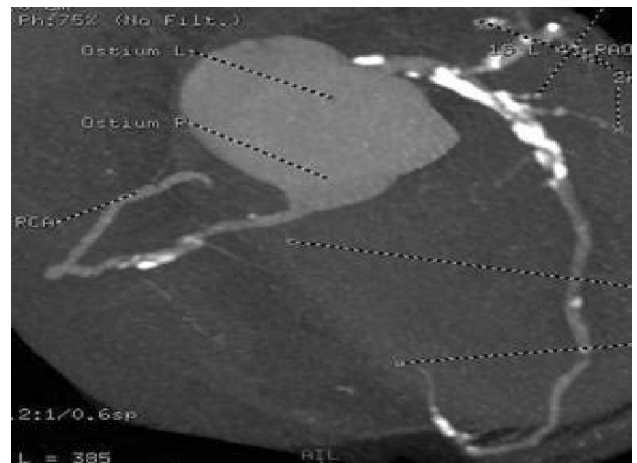
**Figure 3A:** Axial CCTA showing severe calcification of the left coronary (LC) and proximal left anterior descending (LAD) arteries with blooming artifacts .



**Figure 3B:** MPR curved CCTA showing mural calcification of the left coronary and proximal left anterior descending arteries with partial encroachment on their lumen.

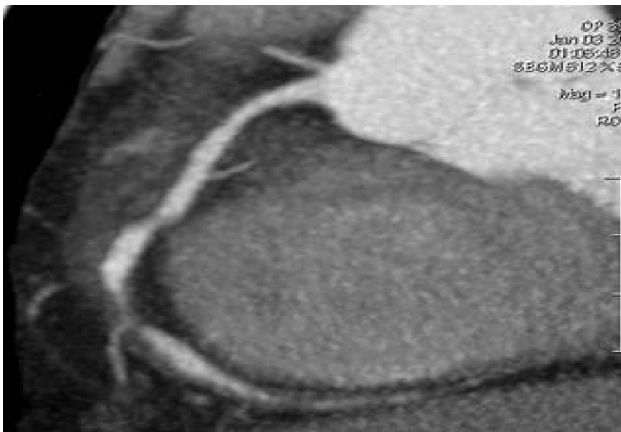


**Figure 3C:** Reformatted image created with vessel-tracking software demonstrating calcified proximal left anterior descending artery (LAD) with estimated 40% stenosis.

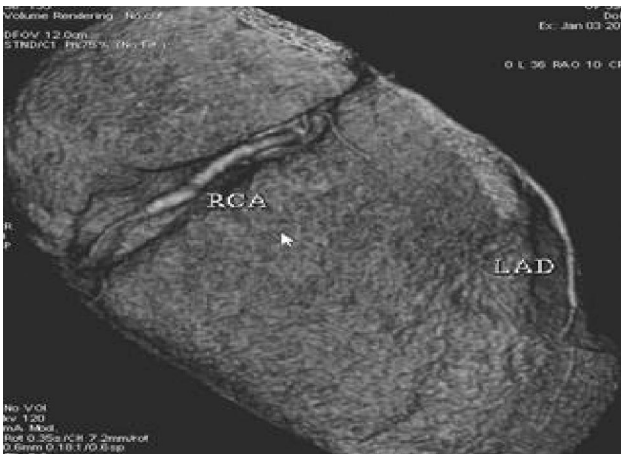


**Figure 3D:** MIP image showing triple vessel calcification, most marked in the LAD .

**Figure 4(A-B):** CCTA of a 56 year old man with history of chest pain and negative investigations 1 year ago ,presenting with acute chest pain.

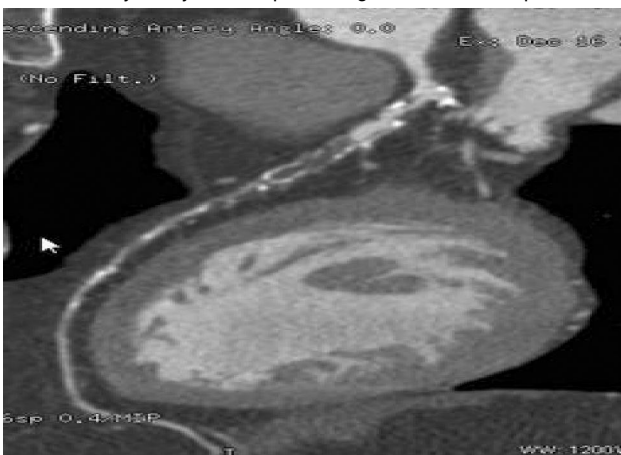


**Figure 4A:** MPR curved CCTA of the right coronary artery showing mid and distal significant >50% stenosis.

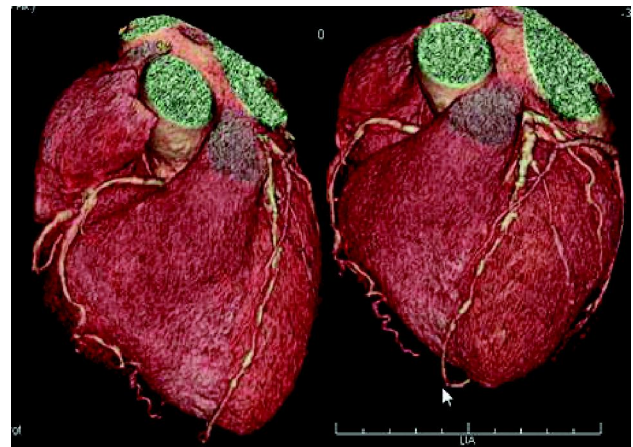


**Figure 4B:** 3D volume rendered image showing short mid and long distal segment RCA stenosis

**Figure 5(A-B):** CCTA of 67 year old male with no prior history of coronary artery disease presenting with acute chest pain .



**Figure 5A:** MPR curved CCTA of the left anterior descending artery showing scattered mural calcific foci and non calcified plaque totally occluding the proximal LAD with attenuated opacified mid and distal segments.



**Figure 5B:** Volume-rendered 3D images although visually appealing, but they usually play little role in primary interpretation. These images show multiple segments of high grade stenosis of the LAD with mid and distal filling via collaterals.

Beyond the 3 major life-threatening causes of acute chest pain, we should not forget other less serious causes as pericardial disease, pneumonia ,pleural effusion, esophageal pathology and chest wall abnormalities .According to the previous studies ,these less serious causes constitute over 50% of acute chest pain cases.<sup>23</sup> In our study a total of 40 patients underwent CT scans with 19 cases showing coronary artery disease of varying severity ,6 cases showing pulmonary embolism or aortic dissection and the remaining 15 cases (37.5%) were negative for these life-threatening conditions .Of these 15 cases, 2 cases of pericardial disease, 4 cases of pneumonia and 4 cases of pleural effusion were identified on the performed CT scans.

## Conclusion


Immediate coronary catheterization is mandatory for high risk patients with typical chest pain .In contrast, patients with acute chest pain but low to intermediate cardiovascular risk, CCTA provides the potential to rapidly and reliably diagnose or exclude acute coronary syndrome with high negative predictive value .CT is also a well established and accurate tool for the diagnosis of acute aortic dissection and pulmonary embolism. Recent technical developments now permit acquisition of well-opacified images of the coronary arteries, thoracic aorta and pulmonary arteries from a single CT scan. While this so called “triple-rule out”

scan protocol can potentially exclude fatal causes of chest pain in all three vascular beds, the attendant higher radiation dose of this method precludes its routine use except in selected cases. Further technical advances especially of the recently introduced prospective ECG-triggering approach appeared to drastically reduce the radiation dose. Large scale clinical trials are needed for further evaluation of this technique in the assessment of patients with acute chest pain.

## References

1. Tatum JL, Jesse RL, Kontos MC et al. Comprehensive strategy for the evaluation and triage of the chest pain patient. *Ann Emerg Med* 1997;**29**:116-25.
2. Goldstein JA, Gallagher MJ, O'Neill WW et al. A randomized controlled trial of multi-slice coronary computed tomography for evaluation of acute chest pain patients. *J Am Coll Cardiol* 2007;**49**:863-71.
3. Hamon M, Biondi-Zoccai GGL, Malagutti P et al. Diagnostic performance of multislice spiral computed tomography of coronary arteries as compared with conventional invasive coronary angiography. A meta analysis. *J Am Coll Cardiol* 2006;**48**:1896-1910.
4. Hollander JE, Chang AM, Shofer FS et al. Coronary computed tomographic angiography for rapid discharge of low-risk patients with potential acute coronary syndromes. *Ann Emerg Med*. 2009 Mar; **53**(3):295-304.
5. Willoteaux S, Lions C, Gaxotte V et al. Imaging of aortic dissection by helical computed tomography (CT). *Eur Radiol* 2004;**14**:1999-2008.
6. Anderson DR, Kovacs MJ, Dennie C et al. Use of spiral computed tomography contrast angiography and ultrasonography to exclude the diagnosis of pulmonary embolism in the emergency department. *J Emerg Med* 2005;**29**:399-404.
7. Lee HY, Yoo SM and White CS. Coronary CT angiography in emergency department patients with acute chest pain: "Triple rule-out" protocol versus dedicated coronary CT angiography. *The International Journal of Cardiovascular Imaging (formerly Cardiac Imaging)* March 2009; **25**(3): 319-26.
8. Morrow DA, Antman EM, Charlesworth A et al. TIMI Risk Score for ST-Elevation Myocardial Infarction: A Convenient, Bedside, Clinical Score for Risk Assessment at Presentation. *Circulation* 2000;**102**: 2031.
9. Gallagher MJ and Raff GL. Use of multislice CT for the evaluation of emergency room patients with chest pain: The so-called "Triple rule-out." Catheterization and cardiovascular interventions 2008; **71**(1): 92-9.
10. Vrachliotis TG, Bis KG, Hairdary A et al. Atypical chest pain: Coronary, aortic, pulmonary vasculature enhancement at bi-phasic single-injection 64-section CT angiography. *Radiology* 2007;**243**: 368-76.
11. Hausleiter J, Meyer T, Hermann F et al. Estimated radiation dose associated with cardiac CT angiography. *JAMA* 2009;**301**(5): 500-7.
12. Bastarrika G, Thilo C, Headden GF et al. Cardiac CT in the Assessment of Acute Chest Pain in the Emergency Department. *AJR* 2009;**193**: 397-409.
13. Leber AW, Knez A, Von Ziegler F et al. Quantification of obstructive and non obstructive coronary lesions by 64-slice computed tomography. *J Am Coll Cardiol* 2005;**46**: 147-54.
14. Sato Y, Matsumoto N, Ichikawa M, et al. Efficacy of multislice computed tomography for the detection of acute coronary syndrome in the emergency department. *Circulation* 2005;**69**: 1047-51.
15. Raff GL and Goldstein JA. Coronary angiography by Computed Tomography. *Journal of American College of Cardiology* 2007;**49**:1830-3.
16. Gilard M, Cornily J, Pennec P, et al. Accuracy of multislice computed tomography in the preoperative assessment of coronary disease in patients with aortic valve stenosis *J Am Coll Cardiol* 2006;**47**: 2020-4.



- 
- 
17. Achenbach S. Computed tomography coronary angiography J Am Coll Cardiol 2006;**48**: 1919-28.
  18. Rybicki FJ. Lower radiation dose coronary CT angiography with new imaging technologies. Int J Cardiovasc Imaging 2009;**25**: 149–51.
  19. Earls JP and Schrack EC. Prospectively gated low-dose CCTA: 24 months experience in more than 2,000 clinical cases. The International Journal of Cardiovascular Imaging (formerly Cardiac Imaging) August 2009;**25(2)**: 177-87.
  20. Knowles NG ,Patel S and Kazerooni EA .Cardiac CT for acute chest pain in the emergency department: advantages of prospective triggering. The International Journal of Cardiovascular Imaging (formerly Cardiac Imaging) August 2009;**25(2)**: 255-65.
  21. Tsai TT , Nienaber CA and Eagle KA .Acute Aortic Syndromes. Circulation 2005;**112**: 3802-13.
  22. Lu HN ,Ozmen CA ,Akay HO et al .64-MDCT Pulmonary Angiography and CT Venography in the Diagnosis of Thromboembolic Disease. AJR 2009; **192**: 654-61
  23. Gallagher MJ ,Ross MA ,Raff GL et al .The diagnostic accuracy of 64-slice computed tomography coronary angiography compared with stress nuclear imaging in emergency department low risk chest pain patients Ann Emerg Med 2007;**49**: 125-36.