

# TO DETERMINE THE FREQUENCY OF ACHILLES TENDON INVOLVEMENT IN PSORIASIS BY ULTRASOUND

Fareeha Khalid, Nisar Ahmed, Mazhar Shafiq, Rahat, Atif

Department of Radiology, PNS Shifa Hospital, Karachi, Pakistan.

PJR January - March 2017; 27(1): 09-13

## ABSTRACT

**OBJECTIVE:** To determine the frequency of Achilles enthesiopathy by ultrasound in psoriatic patients who are clinically asymptomatic for enthesiopathy. **STUDY DESIGN:** This was a descriptive cross-sectional study. **PLACE AND DURATION OF STUDY:** The study was conducted in the Department of Radiology, PNS Shifa Hospital, Karachi, Pakistan from 02-04-15 to 30-06-16 for a period of 14 months. **PATIENTS & METHODS:** Number of patients were eighty one (81). Dermatologically proven cases of psoriasis were included, between ages 18-60 years, having no history of arthritis or foot trauma. Patients underwent ultrasound of bilateral Achilles tendon. **RESULTS:** In the study calculated mean age was  $44.28 \pm 10.019$  years and the male to female ratio was 5.75:1. Achilles enthesiopathy was detected by ultrasound in 4 (4.9%) patients who were clinically asymptomatic for enthesiopathy. Statistically significant difference was found between disease duration groups and outcome variable with  $p\text{-value}=0.003$  and in significant differences were found between outcome variable and age groups and gender that are  $p\text{-value} = 0.127$  and  $p\text{-value} = 0.520$  respectively. **CONCLUSION:** Our study results concluded that ultrasound is a cost effective and useful investigation tool for detecting Achilles enthesiopathy in clinically asymptomatic psoriatic patients for enthesiopathy.

**Key words:** Achilles tendon, Psoriasis, enthesopathic, Psoriatic Arthritis (PsA).

## Introduction

Psoriasis is an immune-mediated, chronic inflammatory and proliferative skin disease characterized by chronic, dull red, sharply demarcated scaly plaques of skin involving extensor prominences and scalp particularly and associated with seronegative forms of spondyloarthropathy known as psoriatic arthritis (PsA).<sup>1,2</sup>

In most patients skin manifestations of psoriasis precedes the onset of PsA, although no definite relationship is found between skin disease and PsA. Prevalence of PsA in patients with psoriasis varies from 7.6 to 36% in different populations studied.<sup>3-9</sup> It is clinically characterized by involvement of entheses, tendons and joints. Patients complain of severe foot pain and difficulty in walking. Clinical examination

shows tenderness and swelling along the course of Achilles tendon and at its calcaneal insertion.<sup>10</sup>

Molls and Wright's diagnostic criterion is used in the diagnosis of psoriatic arthritis; however this criterion does not include isolated peripheral enthesitis.<sup>11</sup> Although entheses are the initial sites of joint inflammation in spondyloarthropathy and enthesitis commonly involves lower limbs. Achilles tendonitis is fairly common, reported in 10-30% of psoriatic patients and could be considered as the earlier signs of psoriatic arthritis.<sup>12,13</sup>

Disability (may be permanent) is not uncommon.<sup>14</sup> Although radiographic evaluation of joint involvement is still the gold standard for definitive diagnosis of PsA, but ultrasonography is now playing an important

**Correspondence :** Dr. Fareeha Khalid  
Department of Radiology,  
PNS Shifa Hospital,  
Karachi, Pakistan.  
Email: fareeharadio@gmail.com

Submitted 17 July 2016, Accepted 11 October 2016

role because of its widespread bedside availability, safety, non-invasiveness and low costs. Ultrasonography is a useful tool for evaluation of soft tissues as it allows visualization of soft tissues, joints, bursae and muscles and their lesions such as oedema, abscess, tears and effusions.<sup>15,16</sup> Clinically suspected enthesitis is afterwards better confirmed by power Doppler ultrasonography and/or magnetic resonance<sup>17</sup> and validation ultimately comes down to histological confirmation.

## Material and Methods

This descriptive cross sectional study was conducted in department of Radiology, P.N.S Shifa Hospital, Karachi, Pakistan from 02-04-15 to 30-06-16 for a period of 14 months. The sample size was calculated on WHO software version of sample size determination<sup>18</sup> in health studies, the sample size thus calculated was 81 patients.

Non-Probability consecutive sampling technique was used. A brief history and informed consent was taken from the patients referred for ultrasound examinations. The patients included in this study were both males and females between 18-60 years of age, who were diagnosed by dermatologists of PNS SHIFA Hospital, Karachi as cases of psoriasis for at least 06 months and were able to give informed consent.

Patients with no clinical and histological evidence of psoriasis or not being diagnosed by dermatologist as a case of psoriasis or having history of osteoarthritis, rheumatoid arthritis or foot trauma or unable to give informed consent were excluded.

U/S was done by radiology registrar, with a high frequency linear array transducer of 6-11 MHz, and U/S images were analyzed by experienced radiologist. The Achilles tendons were evaluated for early signs of tendinitis and enthesitis, which could be manifested as fluid collections around Achilles tendon or retrocalcaneal bursa, architectural distortion or tear of tendon fibers and increased tendon thickness. The thickness of the tendon was measured at the level of the lateral malleolus for standardization of the measurements. Normal Achilles tendon thickness is  $5.1 \pm 0.63$  mm.<sup>19</sup> Presence of any one or more of the above mentioned findings was considered as Achilles tendon involvement.

Data was entered and analyzed by using SPSS v.21. Mean and standard deviation was calculated for age and duration of disease, frequency and percentage was calculated for gender and outcome variable that is Achilles tendon involvement in psoriatic patients who are clinically missed and detected on ultrasound. Effect modifiers like age, gender, duration of disease was controlled through stratification. Post stratification Chi-square test was applied by taking P-value <0.05 as significant.

## Results

In this study a total of 81 cases were enrolled. The mean age of the patients was  $44.28 \pm 10.019$  years with an age range of 24 to 60 years. (Chart: 1) Total male patients were 69 (85.2%) and female patients were 12 (14.8%) with male to female ratio of 5.75:1.

Among 81 patients 32 were  $\leq 40$  years and 49 were  $>40$  years of age however the 'outcome variable' (Achilles enthesiopathic changes on ultrasound in psoriatic patients who are clinically asymptomatic for enthesiopathy) was found in 4 (4.94%) patients who were all male and  $>40$  years of age.

Total 61 patients had  $<15$  years disease duration among which outcome variable was not found in a single patient. However 4 out of 20 patients with  $\geq 15$  years disease duration had positive outcome variable with p-value 0.003 (significant). (Chart 2)

	N	Mean	Std. Deviation
Age	81	44.28	10.019
Duration - years	81	11.44	9.298

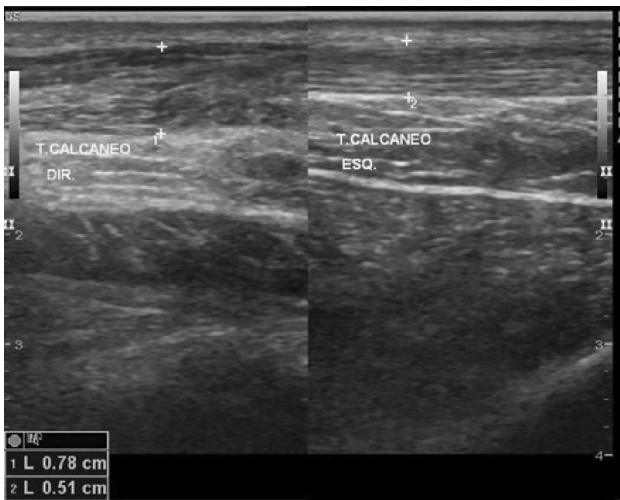
Chart 1: Mean and Standard Deviation of Age and Disease duration (years)

		durtion.group		Total
		<15 years	$\geq 15$ years	
Outcome. variable	Yes	0	4	4
	No	61	16	77
Total		61	20	81

Chi-square P-value 0.003 (significant)

Chart 2: Crosstab of outcome variable with disease duration group

Statistically no significant relationship was found between outcome variable and age groups (p-value = 0.127) and gender (p-value = 0.520).



**Figure 1:** Normal Achilles tendon thickness and texture (right). Increased Achilles tendon thickness with altered texture (left).

## Discussion

This study was conducted at department of Radiology P.N.S Shifa Hospital Karachi to determine the frequency of Achilles enthesiopathy in psoriatic patients who are clinically missed, utilizing ultrasound as an investigation tool.

Imaging techniques such as ultrasonography and magnetic resonance imaging have shown that enthesitis can be asymptomatic and that some cases of Achilles tendinitis can go undiagnosed on clinical evaluation. However, with advances in technology and wide availability there is a larger trend among physicians in various specialties to integrate U/S into their routine clinical assessment.<sup>20</sup>

Our study has shown that 4 (4.94%) clinically asymptomatic patients had positive ultrasound findings for Achilles enthesiopathy, while 4 (4.94%) patients with clinical signs and symptoms of Achilles enthesitis had negative ultrasound findings, Pistone et al<sup>21</sup> reported in their study conducted on 59 patients with chronic plaque psoriasis that ultrasonography of the Achilles tendon can detect enthesitis before clinical signs or symptoms and suggested the use of this technique in the early diagnosis of psoriatic arthropathy. In our study we give mean and frequency distribution of psoriasis according to age and gender in our population and found statistically significant difference between disease duration groups and outcome variable with p-value = 0.003.

The mean age of the patients presenting to us was

44.28 ± 10.02 years. In our study statistically significant relationship was found between outcome variable and disease duration (p-value = 0.003). In a study done by Abbas M. et al,<sup>15</sup> 70 patients of psoriasis were included and divided in two groups, with the mean age of patients in group I (n=35) was 31.9 + 11.5 years (range 13-60 years) while in group II, the mean age was 40.5 + 11.6 years (range 21-67 years). They also concluded in their study that the Achilles tendon involvement occurs in significant number of patients with long standing psoriasis as compared to newly diagnosed cases. USG imaging may have the advantage of early diagnosis warranting the initiation of treatment before the significant structural damage occurs.

A study by Grechenig W et al demonstrated that by using high-resolution small ultrasound probes, the depiction of "problem areas" (e.g., musculotendinous junction, insertion of the tendon on the calcaneus) has become easier and more accurate. They showed that the ultrasonography is the method of choice for the diagnosis of acute and chronic Achilles tendon disorders.

Clara De simone et al presented in their study that the U/S proved valuable in detecting joint and/or tendon abnormalities in the fingers and toes of patients with suspicious changes. The dermatologist should consider U/S to obtain an accurate assessment of suspicious findings.


## Conclusion

Our study results concluded that ultrasound is a cost effective and useful investigation tool for detecting Achilles tendon involvement in clinically missed psoriatic patients.

## References

1. Prinz JC. The role of T cells in psoriasis. *J Eur Acad Dermatol Venereol.* 2003; **17(3)**: 257-70.
2. De Simone C, Guerriero C, Giampetruzzi AR, Costantini M, Di Gregorio F, Amerio P. Achilles tendinitis in psoriasis: clinical and sonographic findings. *J Am Acad Dermatol.* 2003; **49(2)**: 217-22.

3. Alamanos Y, Papadopoulos NG, Voulgari PV, Siozos C, Psychos DN, Tympanidou M, et al. Epidemiology of psoriatic arthritis in northwest Greece, 1982-2001. *J Rheumatol.* 2003; **30(12)**: 2641-4.
4. Barisic-Drusko V, Dobric I, Pasic A, Paljan D, Jukic Z, Basta-Juzbasic A, et al. Frequency of psoriatic arthritis in general population and among the psoriatics in Department of Dermatology. *Acta Derm Venereol Suppl (Stockh).* 1994; **186**: 107-8.
5. BiondiOriente C, Scarpa R, Pucino A, Oriente P. Psoriasis and psoriatic arthritis. Dermatological and rheumatological co-operative clinical report. *Acta Derm Venereol Suppl (Stockh).* 1989; **146**: 69-71.
6. Gisondi P, Girolomoni G, Sampogna F, Tabolli S, Abeni D. Prevalence of psoriatic arthritis and joint complaints in a large population of Italian patients hospitalised for psoriasis. *Eur J Dermatol.* 2005; **15(4)**: 279-83.
7. Salvarani C, Lo Scocco G, Macchioni P, Cremonesi T, Rossi F, Mantovani W, et al. Prevalence of psoriatic arthritis in Italian psoriatic patients. *J Rheumatol.* 1995; **22(8)**: 1499-503.
8. Scarpa R, Oriente P, Pucino A, Torella M, Vignone L, Riccio A, et al. Psoriatic arthritis in psoriatic patients. *Br J Rheumatol.* 1984; **23(4)**: 246-50.
9. Shbeeb M, Uramoto KM, Gibson LE, O'Fallon WM, Gabriel SE. The epidemiology of psoriatic arthritis in Olmsted County, Minnesota, USA, 1982-1991. *J Rheumatol.* 2000; **27(5)**: 1247-50.
10. Dougados M, Linden SVD, Juhlin R, Huitfeldt B, Amor B, Calin A, et al. The European Spondylarthropathy Study Group preliminary criteria for the classification of spondylarthropathy. *Arthritis & Rheumatism* 1991; **34(10)**: 1218-27.
11. Moll J, Wright V, editors. *Psoriatic arthritis. Seminars in arthritis and rheumatism*; 1973: Elsevier
12. Mc Gonagle D, Gibbon W, Emery P. Classification of inflammatory arthritis by enthesitis. *The Lancet* 1998; **352(9134)**: 1137-40.
13. Mc Gonagle D, Green GPOCM. Characteristic Magnetic Resonance imaging enthesial changes of knee synovitis in spondyloarthropathy. 1998.
14. Amor B, Dougados M, Mijiyawa M. Critères diagnostiques des spondylarthropathies. *Rev Rhum Mal Osteoartic* 1990; **57**: 85-9.
15. Abbas M, Suhail M, Ejaz A, Shaikh ZI, Hosain A. Comparison of clinical and sonographical findings of Achilles tendon involvement in newly diagnosed and established cases of psoriasis. *Journal of Pakistan Association of Dermatologists* 2011; **21**: 16-21.
16. Fournié B, Margarit-Coll N, de Ribes TLC, Zabraniecki L, Jouan A, Vincent V, et al. Extrasynovial ultrasound abnormalities in the psoriatic finger. Prospective comparative power-doppler study versus rheumatoid arthritis. *Joint Bone Spine* 2006; **73(5)**: 527-31.
17. Eshed I, Bollow M, McGonagle DG, Tan AL, Althoff CE, Asbach P, et al. MRI of enthesitis of the appendicular skeleton in spondyloarthritis. *Ann Rheum Dis.* 2007; **66(12)**: 1553-9.
18. Ely JW, Stone MS. The generalized rash: part II. Diagnostic approach. *Am Fam Physician.* 2010; **81(6)**: 735-9.
19. Pang BS, Ying M. Sonographic measurement of Achilles tendons in asymptomatic subjects variation with age, body height, and dominance of ankle. *Journal of ultrasound in medicine* 2006; **25(10)**: 1291-6.
20. Patil P, Dasgupta B. Role of diagnostic ultrasound in the assessment of musculoskeletal diseases. *Ther Adv Musculoskelet Dis.* 2012; **4(5)**: 341-55.
21. Pistone G, La Vecchia M, Pistone A, Bongiorno MR. Achilles tendon ultrasonography may detect early features of psoriatic arthropathy in patients with cutaneous psoriasis. *Br J Dermatol.* 2014; **171(5)**: 1220-2.

- 
- 
22. Grechenig W, Clement H, Bratschitsch G, Fankhauser F, Peicha G. [Ultrasound diagnosis of the Achilles tendon]. *Orthopade*. 2002; **31(3)**: 319-25.
  23. De Simone C, Caldarola G, D'Agostino M, Carbone A, Guerriero C, Bonomo L, et al. Usefulness of ultrasound imaging in detecting psoriatic arthritis of fingers and toes in patients with psoriasis. *ClinDevImmunol*. 2011; **2011**: 390726.