

# MICTURATING CYSTOURETHROGRAPHY- A PICTORIAL ESSAY

Palle Lalitha,<sup>1</sup> M. Ch. Balaji Reddy,<sup>1</sup> K. Jagannath Reddy,<sup>1</sup> Vijaya Kumari<sup>2</sup>

<sup>1</sup> Department of Radiology, Focus Diagnostic Center, Punjagutta, Hyderabad, India

<sup>2</sup> Osmania General Hospital, India

PJR July - September 2010; 20(3): 136-142

## ABSTRACT

Micturating cystourethrography (MCUG) is a commonly performed examination in the radiology department, especially pediatric radiology. It gives information which may not be obtained by any other imaging modality. It must be performed with utmost care and under strict aseptic precautions in order to minimize infections and patient distress. In this pictorial essay we aim to discuss most of the common abnormalities that can be picked up on the MCUG test.

**Keywords:** Micturating cystourethrography; Posterior urethral valves; Vesico-ureteric reflux.

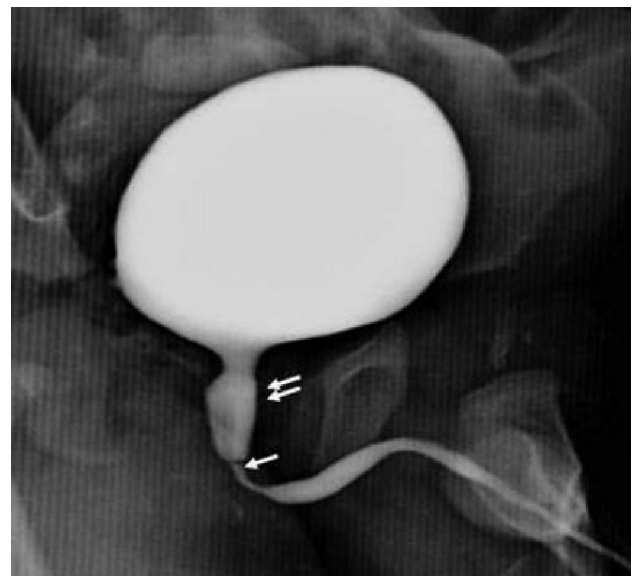## Introduction

MCUG is the most commonly used imaging modality in the evaluation of the male posterior urethra and female urethra.<sup>1</sup> It involves instilling water soluble contrast into the urinary bladder followed by voiding. Urethra can be canulated either by a Foley's catheter or infant feeding tube. Ideally the examination must be performed under antibiotic cover. The procedure must be clearly explained to the attendants and patient where applicable. The procedure should be performed under fluoroscopic guidance. Full bladder and voiding films must be obtained. Lateral or oblique films may be taken if necessary depending on the pathology. The common indications are as follows: Posterior urethral valves, Vesicoureteric reflux in children, in recurrent UTI, stress incontinence, urethral stricture, bladder / urethral pathology, diverticulae and trauma. Contraindications include acute urinary tract infection, contrast media allergies and pregnancy.

### Posterior Urethral valves (PUV)

Posterior urethral valves were first classified by H. H. Young in 1919.<sup>2</sup> Posterior urethral valves are the

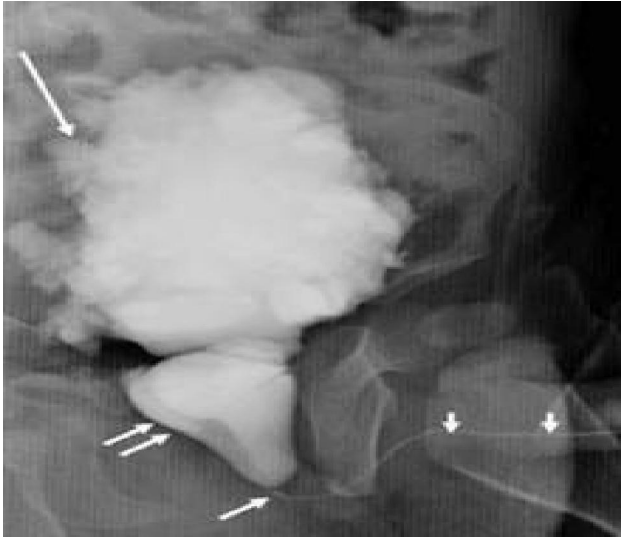most common cause of lower urinary tract obstruction in male infants.<sup>3</sup> PUV refers to an obstructing membrane in the posterior urethra.<sup>4</sup> There are three types of valves with type 1 being the most common and type 3 being the least common varieties. Valves appear as filling defects in the posterior urethra. In mild cases presence of valves may be the only abnormality with no secondary changes in the urinary bladder or reflux (Fig. 1).



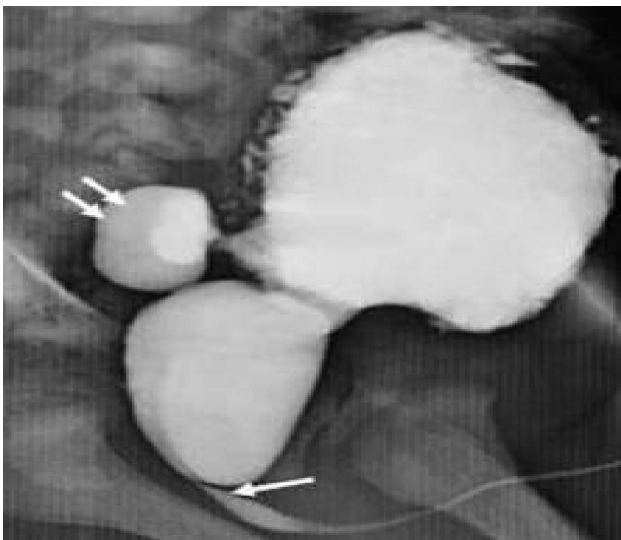
**Figure 1:** Posterior urethral valve. Valve appears as a lucency (single arrow) with mildly dilated posterior urethra (double arrows).

**Correspondence :** Dr. Palle Lalitha  
Department of Radiology,  
Focus Diagnostic Center, Punjagutta,  
Hyderabad, India.  
E-mail: lalithamanohar@rediffmail.com

In cases with moderate to severe obstruction, there will be associated bladder wall thickening, trabeculation and diverticulae with a dilated cone shaped posterior urethra (Fig. 2, 3).

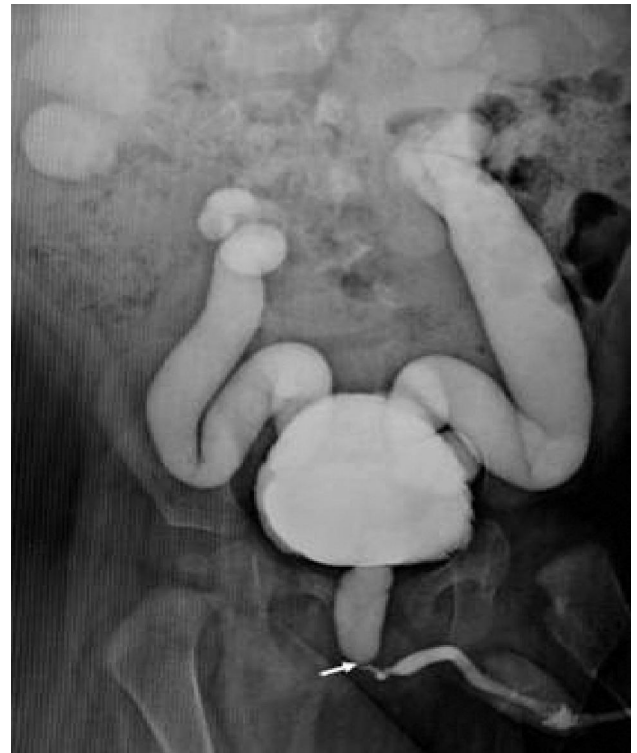

**Figure 2:** Severe posterior urethral valve. Valve is seen as a lucency (single arrow) with dilated posterior urethra ( double arrows). Under filled anterior urethra seen (short arrows) with secondary pressure changes in the urinary bladder(Long arrow).

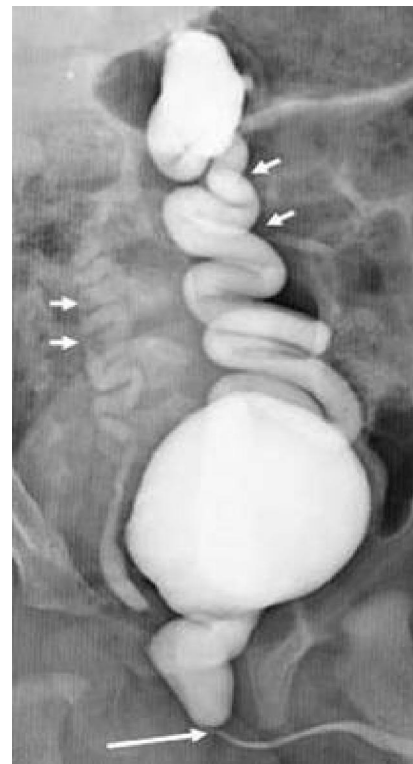

**Figure 3:** Posterior urethral valve with bladder trabeculations and diverticulum. Valve appears as a lucency (single arrow) with mildly dilated posterior urethra. Bladder wall trabeculations are seen with narrow necked posterior diverticulum.

The anterior urethra will be typically under filled.<sup>4</sup> Vesicoureteral reflux may be present in 50% of male patients with posterior urethral valves.<sup>4</sup> It can be physiological, secondary to high bladder pressures overcoming the normal competency of the uretero-vesical junction (Fig. 4, 5).



**Figure 4:** Posterior urethral valve with bilateral reflux. Valve appears as a lucency (arrow) with mildly dilated posterior urethra and bilateral grade 5 reflux.



**Figure 5:** Posterior urethral valve with bilateral reflux. Valve appears as a lucency (single long arrow) with dilated posterior urethra. Bilateral grade 5 reflux seen with dilated and tortuous ureters (short arrows).

Reflux can also be anatomic, when there is abnormal ureteral orifice position due to abnormal ureteral bud development during embryogenesis.

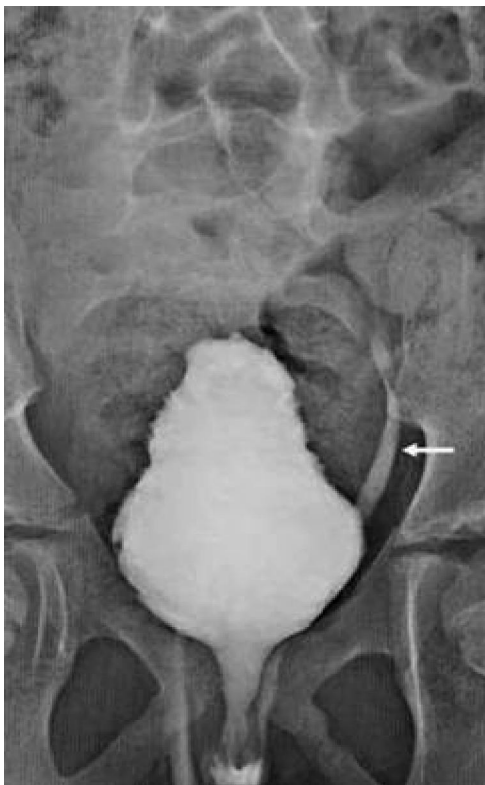**Vescico-ureteric reflux (VUR)**

VUR refers to the retrograde flow of urine from the bladder to the kidneys.<sup>5</sup> Normally the ureter travels for a short length in the urinary bladder wall taking an oblique course, which thereby creates a valve like mechanism which prevent urine backflow during bladder contraction. There are primary and secondary causes of reflux which are listed below.<sup>5</sup>

Primary causes: Short or absent intravesical component of ureter, absence of adequate detrusor backing, abnormal displacement of the ureteral orifice, altered configuration of the ureteral orifice (eg, horseshoe, golf hole shaped).

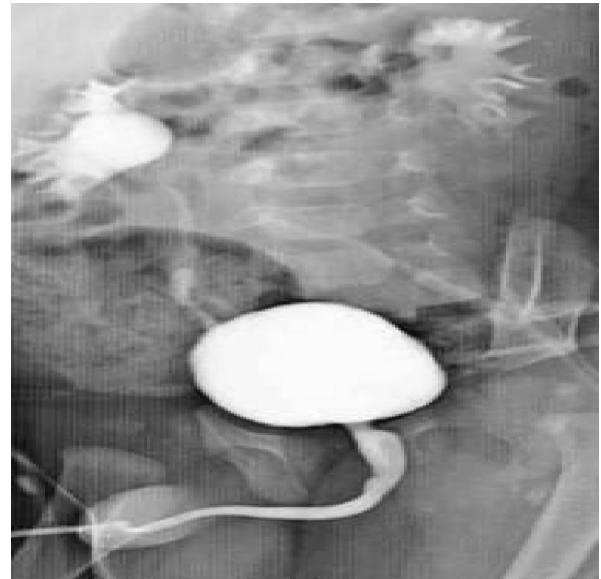
Secondary causes: Include infections of the urinary system, bladder outlet obstruction, detrusor instability, duplex collecting system, paraureteral (Hutch) diverticulum.

According to The International Reflux Grading system, there are 5 grades of reflux.<sup>6</sup> Grade 1-Contrast reflux into lower one third of ureter (Fig.6).



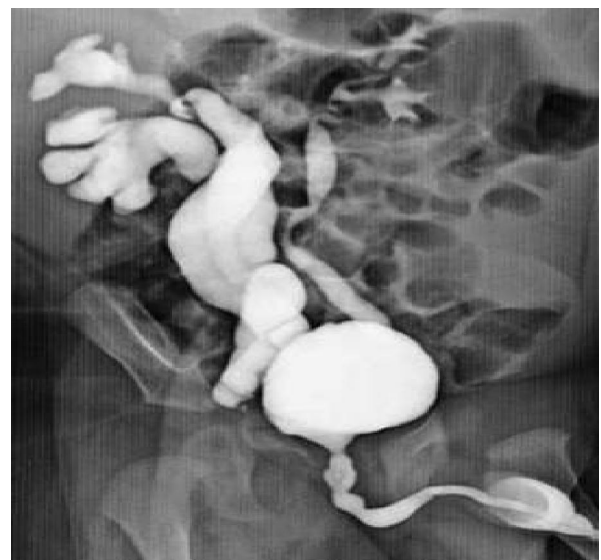**Figure 6:** Left grade 1 reflux. Female patient with contrast in left lower ureter (arrow).

Grade 2- Contrast reflux into pelvicalyceal system with no dilatation (Fig. 7).



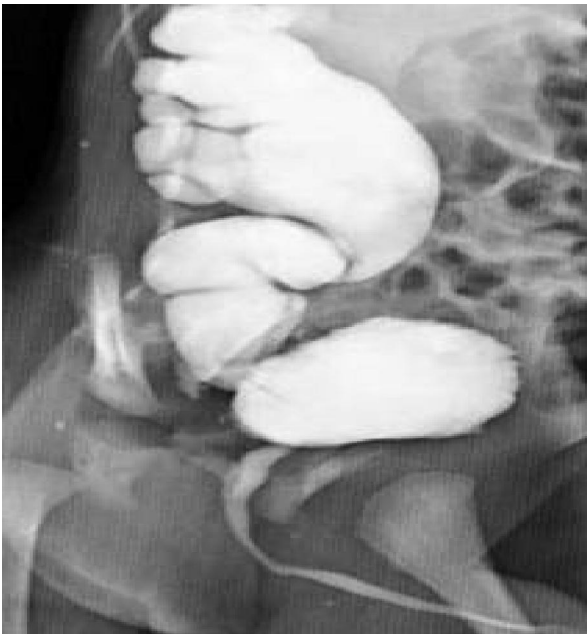**Figure 7:** Bilateral grade 2-3 reflux- Contrast opacification of bilateral renal pelvicalyceal systems with fullness of forniceal angles. Urethra is normal with no evidence of valves.

Grade 3- Contrast reflux into pelvicalyceal system with mild dilatation. Grade 4- Contrast reflux into pelvicalyceal system with moderate dilatation. Moderate dilatation of ureter with early tortuosity is seen. Grade 5- Contrast reflux into pelvicalyceal system with significant dilatation. Dilated tortuous ureter is seen (Fig. 8, 9, 10).

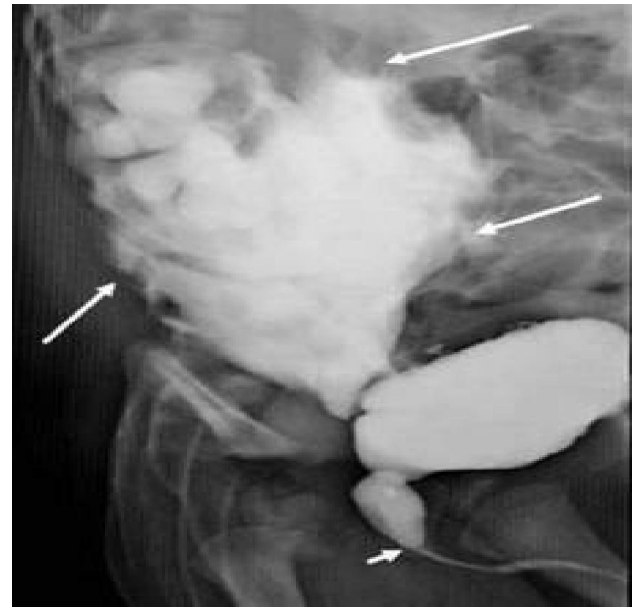


**Figure 8:** Right duplex moiety with bilateral reflux. Contrast opacification of double ureters on right side with dilated tortuous ureters and both pelvicalyceal systems (Right Grade 5 reflux). Contrast opacified left single ureter and pelvicalyceal system with no significant hydronephrosis. (Left Grade 2 reflux).





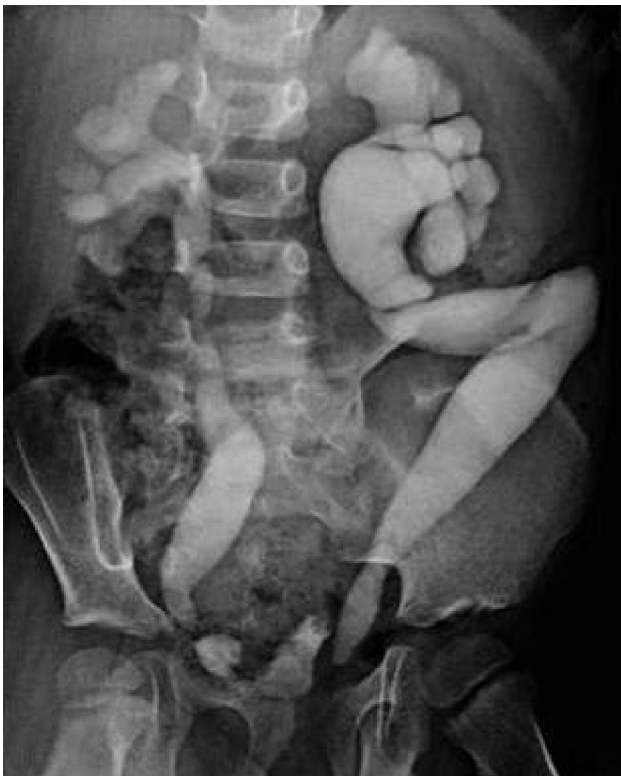**Figure 9:** Right primary grade 5 reflux. Gross dilatation of right renal collecting system and ureter with ureteric tortuosity. Normal urethra with no valves.



**Figure 11:** Right grade 5 reflux with contrast leak from the lower calyces. Contrast is seen the abdominal cavity (long arrows). Posterior urethral valve is seen (short arrow).

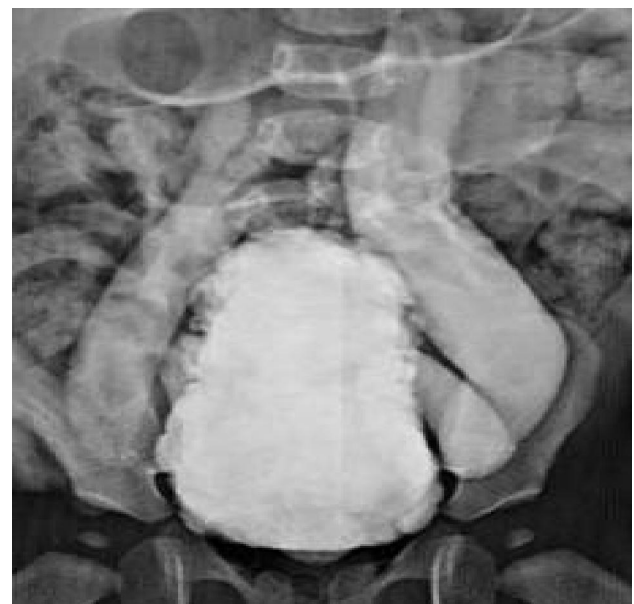### **Bladder abnormalities**

Neurogenic bladder is not an uncommon entity in children. MCUG can depict bladder shape, contour, compliance and determine the presence of associated reflux (Fig. 12).



**Figure 10:** Bilateral grade 5 reflux- Post void film showing bilateral grade 5 reflux with retained contrast in the collecting systems.

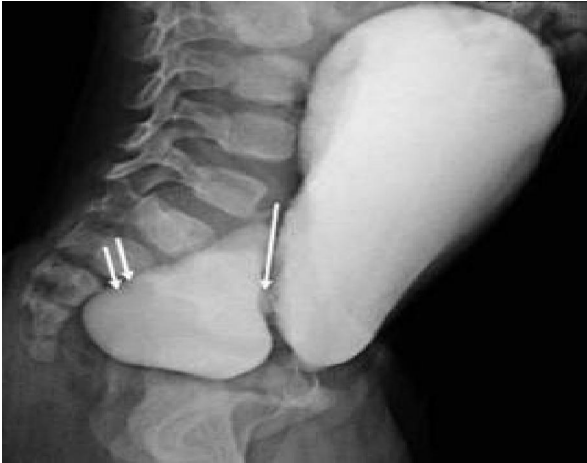Very rarely contrast leak can be seen from the dilated pelvicalyceal system (Fig.11).



**Figure 12:** Neurogenic bladder with bilateral reflux. Female child with trabeculated bladder wall and bilateral reflux.

Presence of phasic contractions can also be assessed on the fluoroscopy, which is a sign of detrusor instability. Extent of bladder contractility and post void residue can also be assessed.

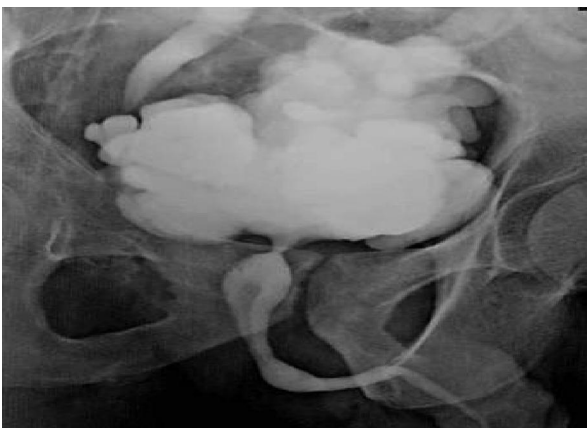
Bladder diverticulae are well seen on the MCUG with excellent demonstration of the neck of diverticulum (Fig. 13).



**Figure 13:** Bladder diverticulum. Lateral film showing narrow necked (single arrow) diverticulum (double arrows) arising from posterior wall of bladder.

Additional lateral and oblique views may be necessary for demonstration of neck of diverticulae. The detection rate of cystography is more than that of cystoscopy in the detection of bladder diverticulae.<sup>7</sup> Bladder diverticulae can be either congenital or can form secondary to bladder outlet obstruction. They can also be seen in association with syndromes like, Ehlers-Danlos syndrome, Diamond Blackfan syndrome, Menkes syndrome (kinky-hair Syndrome), Prune-belly syndrome and Williams syndrome and (idiopathic hypercalcemia).

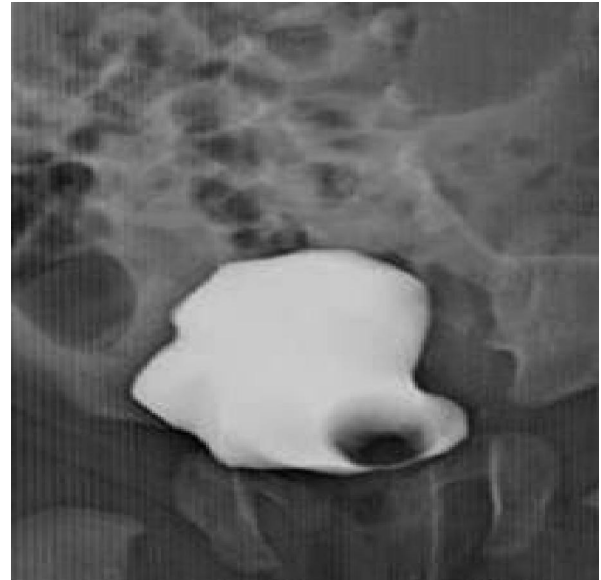Chronic cystitis- Genitourinary tuberculosis is a common cause of bladder scarring. In cases of chronic cystitis low bladder capacity with scarring, can be well demonstrated on MCUG (Fig. 14).



**Figure 14:** Tuberculosis of bladder. Adult male with history of genitourinary tuberculosis, showing a scarred low capacity bladder with multiple diverticulae and bilateral reflux

Bladder capacity as well as associated reflux can be assessed on the MCUG.

Ureterocele are cystic dilations of the sub-mucosal part of terminal ureter.<sup>8</sup> They appear as well defined filling defects in the bladder on the MCUG (Fig. 15).

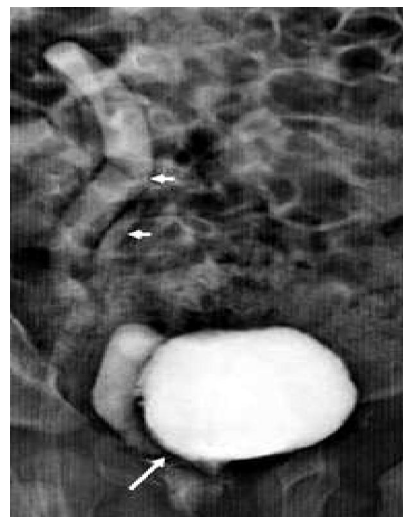

**Figure 15:** Left ureterocele. Well defined round filling defect in urinary bladder on left side consistent with left ureterocele.

They are better visualized in the filling or emptying phase of bladder as complete bladder distension with dense contrast may sometimes obscure the ureterocele.

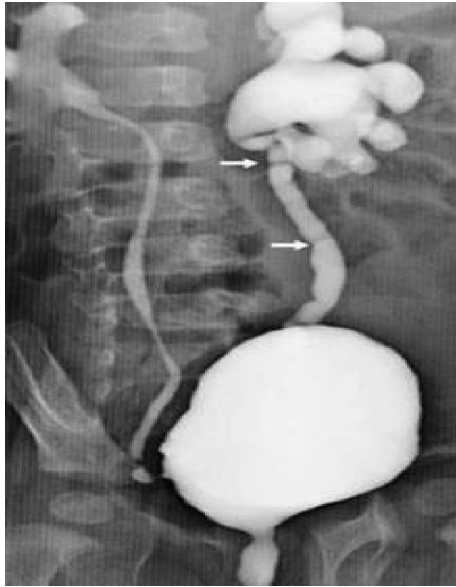
#### ***Ureteral abnormalities***

In the presence of reflux, ureteral abnormalities like abnormal insertion and duplication are also demonstrated on the MCUG (Fig. 16).



**Figure 16:** Right duplex moiety with ectopic ureteric insertion and reflux. Right double ureters (short arrows) seen with abnormal insertion of lower moiety ureter. Reflux noted in both moieties.

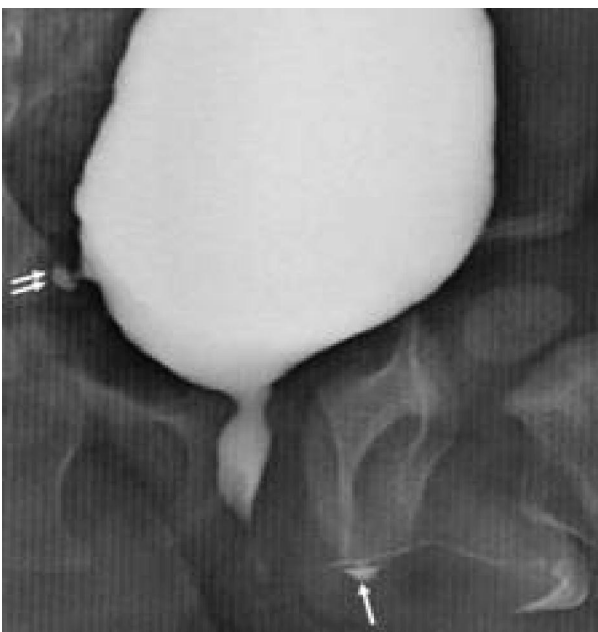
Ureteral valves are rare and are usually unilateral. They are usually associated with other abnormalities like ectopic ureters, renal duplication, renal anomalies and vesico-ureteric reflux.<sup>9</sup> They must not be confused with ureteral mucosal folds which are commonly seen in dilated ureters (Fig. 17).



**Figure 17:** Ureteral mucosal folds. Bilateral grade 4-5 reflux with mucosal folds in both ureters (arrows).

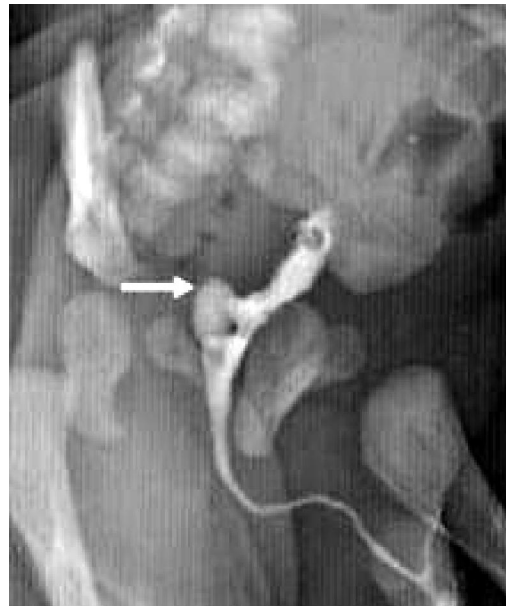**Urethral abnormalities other than valves**

Urethral diverticulae can be well visualized on the voiding films (Fig. 18).



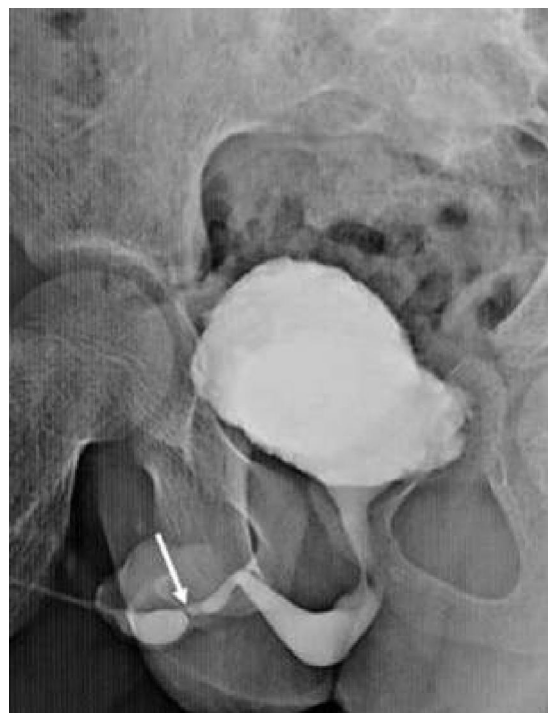**Figure 18:** Anterior urethral diverticulum. Small contrast filled outpouching along inferior aspect of penile urethra suggestive of a diverticulum.

Sometimes the prostatic utricle can fill up with contrast and must not be mistaken for a posterior urethral diverticulum. (Fig. 19)



**Figure 19:** Opacification of prostatic utricle (arrow). Urethra is normal.

MCUG is not the investigation of choice for evaluation of strictures in male anterior urethra, however they can be visualized in the voiding films (Fig. 20).



**Figure 20:** Anterior urethral stricture (arrow). Rest of urethra is normal.

## Conclusion

Since MCUG is a commonly performed investigation for evaluation of lower urinary tract, familiarity with normal anatomy and pathology is essential. It has to be performed with utmost care after explaining the procedure clearly to the patient (in older children and adults) attendants in order to get their co-operation.

## References

1. Akira Kawashima, Carl M. Sandler, Neil F. Wasserman, Andrew J. LeRoy, Bernard F. King Jr, Stanford M. Goldman. Imaging of Urethral Disease; A Pictorial Review. *Radiographics*. 2004; **24**: 195-216.
2. Reisque Imaji and Paddy A. Dewan. Congenital posterior urethral obstruction: re-do fulguration. *Pediatr Surg Int*.2002;**18**:444-6.
3. Hodges SJ, Patel B, McLorie G, Atala A. Posterior urethral valves. 2009;**9**:1119-26.
4. John S Wiener, Ana Maria Gaca, Jeffrey Sekula. Posterior Urethral Valve Imaging. *e-Medicine >Radiology > pediatrics*. Oct 5.2010.
5. Marc Cendron. Vesicoureteral Reflux. *e-Medicine Specialties > Urology > Hydronephrosis and Ureter Disorders*. Dec 3, 2010.
6. R. L. Lebowitz, H. Olbing, K. V. Parkkulainen, J. M. Smellie and T. E. Tamminen-Möbius. International system of radiographic grading of vesicoureteric reflux. 1985;**15**:105-9.
7. S Shakeri, AR Rasekhi, M Yazdani, E Kheradpezhoh. The incidence of diverticula of urinary bladder in patients with benign prostatic hypertrophy and the comparison between cystoscopy and cystography in detecting bladder diverticula. *IRCMJ* 2007; **9(1)**:36-41
8. Ganesh Raj, John S Wiener, Richard A Leder. *e-Medicine Specialties> Radiology>Genitourinary. Ureterocele Imaging*. Mar 16. 2010.
9. Enrica Rossi, Joan Rodò Salas, Freud Cacères Aucatoma, Marta Olivares Muñoz, Luis Morales Fochs. Congenital ureteral valves: Two new cases and a review of the literature. *Journal of Pediatric Urology*.2007;**3**: 344-9.