

KIRNER'S DEFORMITY OF THE LITTLE FINGER: A CASE REPORT WITH LITERATURE REVIEW

Saifullah Khalid, Mohd Khalid, Ekram Ullah, Ahmad Ibne

Department of Radiodiagnosis, JN Medical College, AMU, Aligarh, India

PJR October - December 2010; 20(4): 174-176

ABSTRACT

Kirner's deformity or dystelephalangy is a rare entity which presents with painless, progressive, bilateral radio-volar curving of terminal phalanx of little fingers. It is a clinico-radiological diagnosis. Here-in, we present a similar case with brief review of literature. Given the rarity of the deformity, we believe it useful to present our case report as a further contribution to the literature.

Keywords: Kirner's deformity, fifth/little finger, radio-volar angulation

Case Report

A 13 year old boy referred to us from orthopaedic outpatient department who presented with deformity of bilateral little finger which he noticed three years back. It was gradually progressive in nature. Deformity was not associated with pain, swelling or redness. There was no history of previous trauma or infection to his finger. Child was otherwise healthy. Also no history of a similar deformity in any one of his siblings neither in any family member was revealed.

Physical examination showed bilateral palmar and radial curving of distal phalanges of bilateral little finger which was more on right side. There was no associated tenderness or swelling. Nails of the affected fingers were also curved in volar direction. At the DIP joint range of extension was evidently restricted. His routine blood examination was normal. Rheumatoid Factor & CRP were also negative. Treatment modalities were discussed with the parents. Since the deformity was painless, observation with periodic follow up was chosen as modality of treatment.

Discussion

Kirner's deformity or dystelephalangy was first described by Kirner in 1927.¹ It is a rare but usually bilaterally occurring bony deformity. Literature concerning this deformity is sparse as only a few cases have been reported in the medical journals. Till 1972 about 60 cases have found mention in the literature.²

Incidence of the deformity has been reported to be 1/410 by David & Burwood with a higher incidence noted among Japanese. The deformity is usually sporadic but may be inherited as an autosomal dominant trait with incomplete penetrance with 2:1 female to male ratio. Deformity is bilateral in most cases with right side dominance in unilateral cases.^{3,4} Aetiopathogenesis of Kirner's deformity is still not well understood, with hypotheses being: juvenile osteomalacia; aseptic necrosis on the basis of biopsy findings;⁵ osteochondrosis of possible vascular origin.⁶ It has been proposed that the pull of flexor digitorum profundus aggravates the deformity. However, systemic cause seems unlikely.

Clinically, Kirner's deformity is characterised by shortening of the terminal phalanx of the little finger, which is stubby and deflected in a palmar-radial direction, typically described as "eagle-claw-like" by Sugiura, with a small, dysmorphic "watch glass" nail.

Correspondence : Dr. Saifullah Khalid
Department of Radiodiagnosis,
JN Medical College, AMU,
Aligarh-202002, UP, India
E-mail: khalid_alig@hotmail.com

In majority of cases, it becomes obvious between eight & fourteen years of age.^{1,3,6} However, in some cases deformity may present since birth. Interestingly, in such cases, as opposed to juvenile onset, deformity is also seen in other members of the family. The deformity progresses over month to years and ceases with closure of the physis. It is rarely associated with pain, redness or swelling over base of the nail. Functional limitations, if any, are usually minimal and confined to playing musical instruments or typing.^{8,9} Deformity needs to be differentiated from similar deformities such as clinodactyly (usually radial deviation at the DIP joint) and camptodactyly (flexion deformity at the PIP joint).

Associations have been reported with musculoskeletal abnormalities: genu valgus, pes cavus, myositis ossificans, osteomyelitis, absence of flexor digitorum superficialis tendon in the little finger and cardiovascular abnormalities:³ ventricular septal defect, patent ductus arteriosus, atrial septal defect, valvular pulmonic stenosis.^{1,9,10,11} Literature review reveals association of this deformity with syndromes like Turner`s syndrome, Cornelia de Lange syndrome, Silver syndrome.^{3,12,13}

Radiological findings are consistent, diagnostic and usually straightforward as in our case which shows ventro-radial angulations of terminal phalanx relative to middle phalanx with an apparent overgrowth of epiphysis on the palmar surface and a tiny bony spur, which projects distally and fits into a groove in the basal part of the shaft. Physeal plate appears widened with sharply narrowed and sclerosed diaphysis (Fig.1).

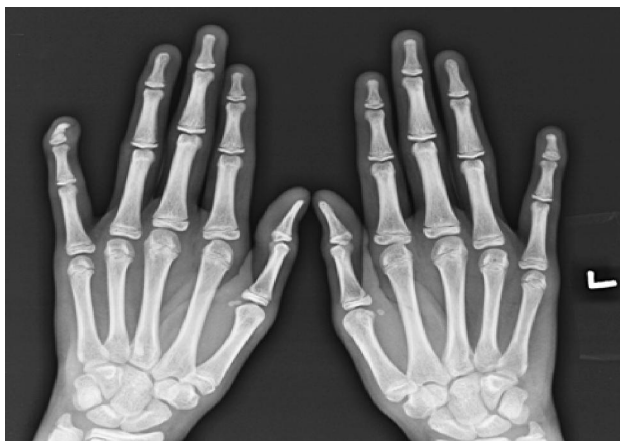

Figure 1: AP view showing ventro-radial angulations of terminal phalanx relative to middle phalanx with an apparent overgrowth of epiphysis on the palmar surface and a tiny bony spur, which projects distally and fits into a groove in the basal part of the shaft. Physeal plate appears widened with sharply narrowed and sclerosed diaphysis

A radiolucent nidus of 1-2 mm may be seen in terminal tuft. The articulation of the epiphysis with the middle phalanx is preserved. As the patient's age progresses, closure of the physeal plate with the diaphysis regains its width and trabecular structure. But the deformity, usually 10-50 degrees, persists. No spontaneous resolution of the deformity has been reported. Lateral view shows palmar bending of the shaft, which is thinner than the epiphysis, a mortise-like pattern of the joint (Fig-2).

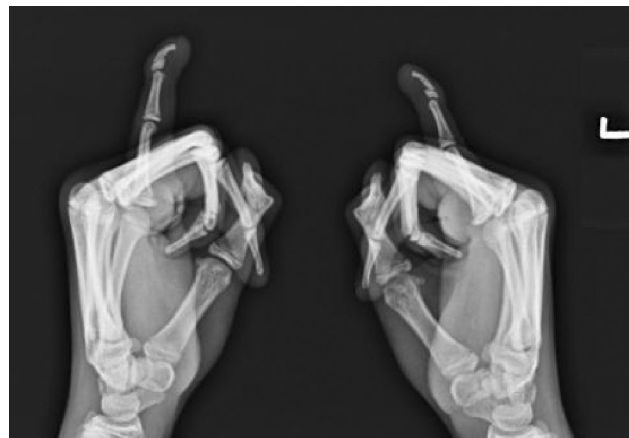


Figure 2: Lateral view shows palmar bending of the shaft, which is thinner than the epiphysis, a mortise-like pattern of the joint

Treatment modalities recommended are observation, splinting and osteotomy.

Since deformity usually ceases after physis closure, reassurance is sufficient. Temporary splinting may be of help in painful cases. Carstam and Eiken advised one or more volar osteotomies leaving an intact dorsal periosteal hinge with K-wire fixation for correction of deformity. Surgery is delayed until physeal closure in order to prevent recurrence of the deformity.^{9,11,13}

References

1. Kirner, J. Doppelseitige Verkrümmungen des Kleinfingerendgliedes als selbständiges Krankheitsbild. *Fortschr.Geb Rontgenstr.* 1927; **36**: 804.
2. C.E. Scott and W. Engber. Kirner`s deformity: a case report and review. *Iowa Orthop J.* 1996; **16**: 167-9.

-
- 
3. David, T.J.; Burwood, R.L.: the nature and inheritance of Kirner's deformity. *J. Med. Genet.* 1972; **9**: 430-3
 4. Sugiura Y, Ueda T, Umezawa K et al. Dystelephalangy of the fifth finger--Dystrophy of the fifth finger. *J Jap Orthop Assoc* 1961; **34**: 29-30
 5. Freiberg, A.; Forrest, B.: Kirner's deformity: a review of literature and case presentation. *J. Hand Surg.* 1986; **11A**:28-32
 6. Taybi, H. Bilateral incurving of the terminal phalanges of the fifth fingers (osteochondrosis?). *J.Pediatr* 1963; **62**: 431-2
 7. Sugiura Y: Polytopic dystelephalangy of the fingers. *Pediatr Radiol* 1989; **19**: 493-5
 8. Staheli, L.T.; Clawson, D.K.; Capps, B.H.: Bilateral curving of the terminal phalanges of the little fingers. *J. Bone joint surg.* 1966; **48**: 1171-6
 9. Carstam Nils, Eiken O, Sweden M: Kirner's deformity of little finger. Case Report and Proposed Treatment. *J Bone Joint Surg* 1970;**52-A**:1963-5
 10. Wilson, J. N.: dystrophy of the fifth finger: Report of four cases. *J. Bone joint surg.* 1952; **34**:236-9.
 11. Dykes RG: Kirner's deformity of little finger. *J Bone Joint Surg* 1978; **60-B**: 58-60
 12. Lee FA. Generalized over constriction of long bones and unilateral Kirner's deformity in a de Lange dwarf. *Am J Dis Child* 1968; **116**:599-603
 13. Kaufmann, H.J.; Taillard, W.F: Bilateral incurving of the terminal phalanges of the fifth fingers. An isolated lesion of the epiphyseal plate. *AJR* 1961; **86**: 490-5.