

SCAR ENDOMETRIOSIS: A RARE COMPLICATION OF CESAREAN SECTION

Sana Noman,¹ Mukhtiar A. Memon,² Jawaid Iqbal,¹ Sara Siddiqui¹

¹ Department of Radiology, Darul Sehat Hospital, Karachi, Pakistan.

² Dow Institute of Radiology, Dow University of Health Sciences, Karachi, Pakistan.

PJR January - March 2016; 26(1): 40-42

ABSTRACT

Scar endometriosis is a rare entity with difficulty in diagnosis. It occurs due to presence of endometrial tissue in anterior abdominal wall following obstetric and gynecological procedures. Most females present with cyclical pain in scar during menstruation, following Cesarean section and are usually clinically diagnosed as having incisional hernia, granuloma or abscess. We present a case of a 27 year old female who presented with tenderness and pain in Caesarian section scar. She was initially diagnosed as a case of incisional hernia and was sent for CT scan Abdomen for its confirmation.

Introduction

Endometriosis is defined as presence of functional endometrial tissue outside uterine cavity. Scar endometriosis is a rare entity with difficulty in diagnosis. It occurs due to presence of endometrial tissue in anterior abdominal wall following obstetric and gynecological procedures. Most females present with cyclical pain in scar during menstruation, following Cesarean section and are usually clinically diagnosed as having incisional hernia, granuloma or abscess. We present a case of a 27 year old female who presented with tenderness and pain in Caesarian section scar. She was initially diagnosed as a case of incisional hernia and was sent for CT scan Abdomen for its confirmation.

Case Report

A 27 year old female presented with painful and tender Caesarian Section scar in Out Patient Department. She has had two deliveries through Caesarian Section and her last born was 6 months old. She denied any post operative pain or any other compli-

cation and complains that pain started almost two months after her last surgery. Pain was initially intermittent and cyclic, corresponding to her menstrual cycle. From past one month she complains of continuous pain in her scar.

On examination, her skin was dark in the region of scar. Swellings were seen on both edges of scar, more prominent on right side. These swellings were tender and hard on palpation. Rest of the physical examination was unremarkable. Her menstrual history was unremarkable apart from cyclic abdominal pain during menstruation. Her laboratory tests were unremarkable.

CT scan abdomen showed two well defined lesions within recti muscles in lower anterior abdominal wall at edges of surgical scar with perilesional fat stranding (Fig. 1). On post contrast study these were showing slight enhancement (Fig. 2). The scar on right side was larger than that on left. No evidence of anterior abdominal wall defect to suggest hernia was seen. On the basis of her CT scan finding she was diagnosed as having bilateral intra muscular endometriosis at the edges of Caesarian Section scar. Surgical

Correspondence : Dr. Sana Noman

Department of Radiology,

Darul Sehat Hospital,

Karachi, Pakistan.

Email: drsananoman@gmail.com

Submitted 17 September 2015, Accepted 21 October 2015

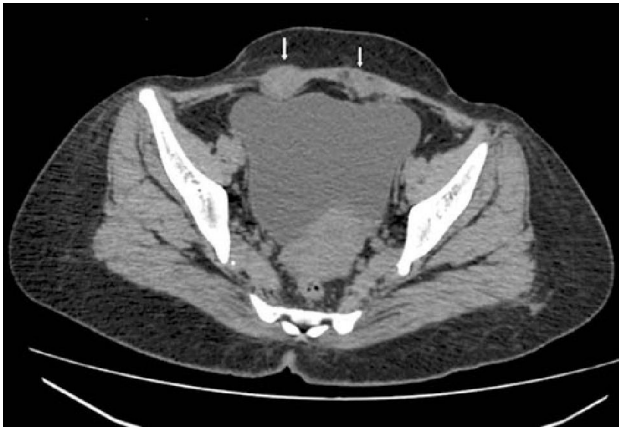

Figure 1: Isodense lesions on edges of Cesarean section scar

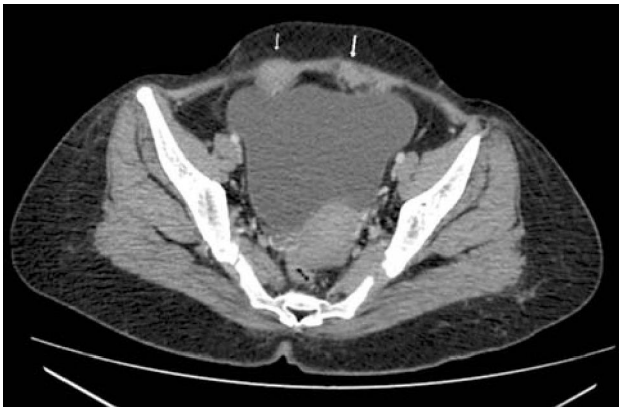

Figure 2: Lesions showing some post contrast enhancement.

excision of the lesions was done and it was sent for histopathological analysis which further confirmed the diagnosis.

Discussion

Scar endometriosis is a rare entity occurring after obstetric and gynecological procedures. It has reported incidence rate of 0.03 to 0.6% following Caesarian section.^{1,2} Many theories have been postulated for its etiology, so far the most accepted theory is iatrogenic implantation of endometrial tissue in the tract of surgical scar during uterine surge-ries.^{3,4,5} The endometrial tissue may get deposited anywhere along the tract of the surgical scar, including subcutaneous tissue, intra muscular or intra peritoneal plains or within the myometrium.^{6,7} Imaging modalities include ultrasound, CT scan and MRI, where findings are usually nonspecific and their role is limited to exclude other pathologies and to see the extent of

disease.⁸ Definite diagnosis is only made after histopathological assessment.⁹

Ultrasound findings include irregular lesion with variable echogenicity and its role is limited to rule out incisional hernia.⁸ CT scan findings include well defined isodense lesion showing slight post contrast enhancement with perilesional fat stranding.⁶


Management options for scar endometriosis include both conservative and surgical options, depending upon patients condition. Pharmacological management comprises of hormonal therapy like prostaglandins and is reported to have low success rate. Wide surgical excision is considered to be treatment of choice.⁸

Conclusion

Scar endometriosis is a rare but well recognized complication of Obstetric and Gynecological surgeries presenting with painful tender scar. It is often misdiagnosed clinically and also has challenging radiological diagnosis leading to unwanted delay in its treatment. It should be included in differential diagnosis of painful surgical scar in females following pelvic surgeries.

References

1. Nominato NS, Prates LF, Lauer I, Morais J, Geber S. Caesarean section greatly increases risk of scar endometriosis. *Eur J ObstetGynecol* 2010; **152**: 83-5.
2. Picod G, Boulanger L, Bounoua F, Leduc F, Duval G. Abdominal wall endometriosis after cesarean section: Report of fifteen cases. *Gynecol Obstet Fertil* 2006; **34**: 8-13.
3. Francica G, Giardiello C, Angelone G, Cristiano S, Finelli R, Tramontano G. Abdominal wall endometriosis near cesarean delivery scars. *J Ultrasound Med.* 2003; **22**: 1041-7.
4. Kaloo P, Reid G, Wong F. Caesarean section scar endometriosis: Two cases of recurrent disease and a literature review. *Aust NZ J ObstetGynaecol.* 2002; **42**: 218-20.

-
- 
5. Douglas C, Rotimi O. Extragenital endometriosis: A clinicopathological review of Glasgow hospital with case illustrations. *J ObstetGynaecol.* 2004; **24**: 804-8.
 6. Coley BD, Casola G. Incisional endometrioma involving the rectus abdominis muscle and subcutaneous tissues: CT appearance. *AJR Am J Roentgenol* 1993; **160(3)**: 549-50.
 7. Dragoumis K, Mikos T, Zafrakas M, Assimakopoulos E, Stamatopoulos P, Bontis J. Endometrioticutaneous fistula after cesarean section: a case report. *GynecolObstet Invest* 2004; **57(2)**: 90-2.
 8. HensenJH, Van bredavriesman AC, Puylaert JB. Abdominal wall endometriosis: clinical presentation and imaging features with emphasis on sonography. *AJR Am J Roentgenol.* 2006; **186(3)**: 616-20.
 9. Aydin O. Scar endometriosis: a gynaecologic pathology often presented to the general surgeon rather than the gynaecologist - report of two cases. *Langenbecks Arch Surg* 2007; **392(1)**: 105-9.