

AMAZIA - A CASE REPORT OF RARE ANOMALY

Sushil Kachewar

Radio-diagnosis Department, Rural Medical College, Loni Maharashtra, India.

PJR October - December 2010; 20(4): 156-157

ABSTRACT

Female breasts have number of functions and are important for a variety of reasons. Various anomalies of nipple and breast parenchyma are known. But the absence of breast parenchyma in the presence of nipple is very rare. One such case report with unilateral abnormality is therefore being reported here.

Keywords: Breasts, Mammary glands, Amazia, Sonomammography, Milk line.

Case Report

A 13 years girl was referred for sonomammography as she noticed underdeveloped left breast. She had not yet achieved menarche. There was no history of trauma, surgery or radiotherapy to left hemi thorax. On clinical examination (Fig.1), her right mammary gland was developed properly with normal nipple; areola and breast tissue. Her left hemithorax

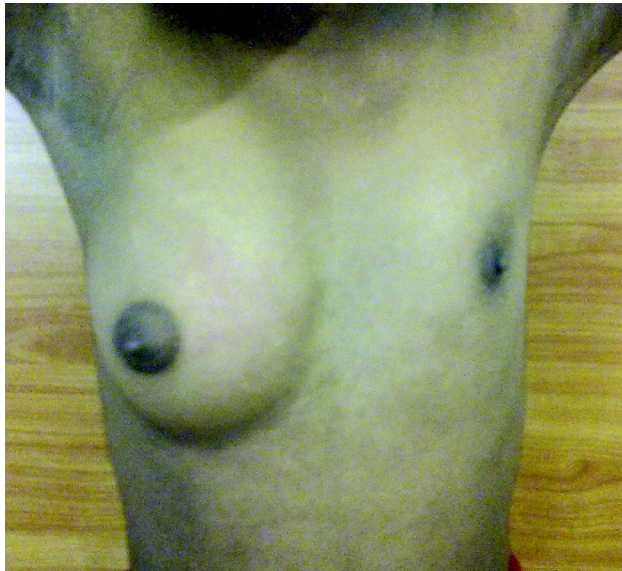


Figure 1: Photograph of patient showing underdeveloped left breast

demonstrated a well developed nipple and areola but underlying breast tissue was neither visible nor palpable. Her sonomammography (Fig.2) done using 7.5 MHz multi frequency linear array probe demonstrated normal right breast having a popper normal nipple, areolar tissue and underlying breast fibro-glandular echo anatomy well along the axillary tail as well; in the right hemithorax. However, the left hemi thorax revealed a normal nipple-areola complex, directly over the pectoral muscles. But normal breast echo anatomy was not demonstrable. Underlying breast fibro-glandular tissue was absent.

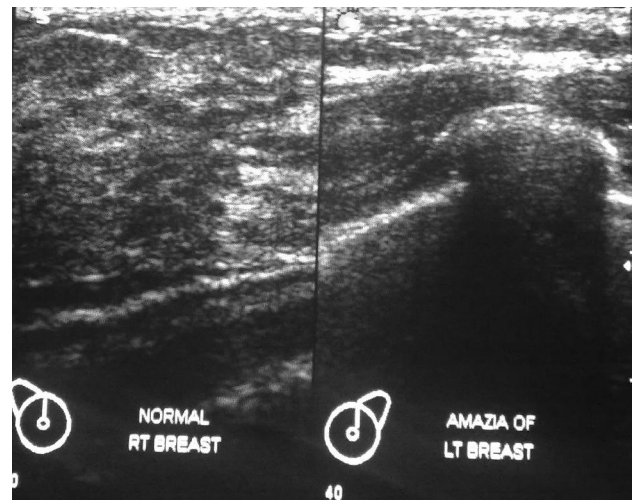


Figure 2: Sonomammography shows normal breast parenchyma in right hemithorax and absent breast parenchyma in left hemithorax such that left pectoral muscles are directly seen below subcutaneous tissues.

Correspondence : Dr. Sushil Kachewar
Associate Professor in Radio-diagnosis Dept.
Rural Medical College, Loni
Maharashtra, India 413 736
E-mail: sushilkachewar@hotmail.com

A sonographic search for breast tissue along the left milk line also revealed no fibro-glandular breast parenchyma. Ultrasonography examination of her thyroid, uterus, both the ovaries and both kidneys were within normal limits or age.

Hence based on the clinical suspicion, followed by physical examination and an affirmative sonographic confirmation; the diagnosis of unilateral Amazia was made.

Discussion

Amazia is a rare congenital, developmental or sometimes iatrogenically acquired anomaly of breast in which although the nipple is present but breast parenchyma is absent so that adequate breast development is not present. It could be unilateral or bilateral.¹

Most commonly Amazia is caused iatrogenically. Inadvertent biopsy of breast bud during childhood or trauma to the chest wall or chest wall radiation or surgery during childhood can cause acquired breast Amazia.^{1,2} Because of rarity of this condition and psycho-social issues involved, the exact incidence of this condition remains unknown. Patients of Amazia are usually uncomfortable without one or both breasts and hence they opt for breast implant to fill out the tissue. When Amazia is bilateral, milk won't be secreted. Hence, such females need proper guidance and counselling. In cases with Amazia, who opt for pregnancy, the children may be breastfed from an intact breast if only one was removed, or they will have to be bottle-fed. Alternately breast milk can be made available through a milk bank or by lactating ladies.² Amazia done in trans gendered persons to bring their bodies into alignment with their gender identity does not need any treatment, unless for cosmetic reasons.² The coexistence of congenital bilateral and bilateral complete has also been reported, which indicates that these rare disorders may be related etiologically.³ Association of amazia with face, limb, and vertebrae anomalies has also been demonstrated.⁴ Poland sequence is characterized with chest muscle deficiency or deformity on one side of the body, which is usually accompanied by the absence of breast and nipple on the affected side. It affects the right side of the body nearly twice as often as the left.^{5,6} When dealing with

Amazia, knowledge about some closely related entities like Amastia, Micromastia, Hypoplasia or Athelia is essential. Amastia, although used interchangeably with the word 'Amazia' is a different entity altogether. Amastia is the complete absence of breast tissue, including the nipple as well as the areola.^{1,2} Micromastia, or breast, is a medical term used specifically to describe the post pubertal underdevelopment of the breast tissue.⁵ Athelia⁶ is a condition in which one or both nipples are absent. This is a congenital condition. The loss of one or both nipples because of accident, disease or surgery is not considered athelia.⁶ To conclude, the knowledge about congenital as well as acquired anomalies of breast is essential so that timely proper diagnosis can be done and the afflicted individual may be assisted to live a satisfactory life.

References

1. Ozsoy Z, Gozu A, Ozyigit MT, Genc B. "Amazia with midface anomaly: case report". *Aesthetic Plast Surg.* 2007; **31(4)**: 392-4.
2. Smith SE. What is Amazia. <http://www.wisegeek.com/what-is-amazia.htm> 2003-2011 Conjecture Corporation.
3. Anastasios Papadimitriou, Olga Karapanou, Anna Papadopoulou, Polyxeni Nicolaidou, Andreas Fretzayas. Congenital bilateral amazia associated with bilateral choanal atresia. *American journal of medical genetics. Part A.* 2009 Jul; **149A (7)**: 1529-31.
4. Ozsoy, Zafer; Gozu, Aydin; Ozyigit, Murat; Genc, Bulent. Amazia with Midface Anomaly: *Aesthetic Plastic Surgery.* 2000; **31:4**, 392-4(3).
5. Poland, Alfred (1841). "Deficiency of the pectoral muscles". *Guy's Hospital Reports VI*: 191-3.
6. Fox CB. What is Athelia. .2003-2011 Conjecture Corporation.