

JUXTAFACET CYST OF CERVICAL SPINE: A RARE NEURAL FORAMINAL LESION

Rana Shoaib Hamid, Imaad ur Rehman, Zahid Anwar Khan

Department of Radiology, Aga Khan University Hospital, Karachi, Pakistan.

PJR October - December 2010; 20(4): 153-155

Introduction

Juxtafacet cysts (JFC) are well recognized entities occurring in the spine in relation to facet joints.¹ These lesions include synovial cysts and ganglion cysts. Lumbar spine is more common location amongst other regions of the spine.^{2,3} Rarely these cysts can be seen in cervical spine.^{4,5} Only 29 cases of cervical synovial cysts has been reported so far to the best of our knowledge.² The cervicothoracic junction is the preferential site of involvement. Usual location is in the dorsolateral spinal canal. Foraminal juxtafacet cyst, as seen in our case, are extremely rare.^{5,7}

Case Report

A 44 year old woman presented with history of fever since last one and a half month associated with cough, neck pain and malaise. Initially fever was also associated with nausea and diarrhea which resolved in one to two days however fever did not resolve and kept increasing to 102°F, occasionally coming to base line with paracetamol. She also complained of generalized body aches and decreased sleep and appetite. Her past medical history revealed that she had depression for last six to seven years, hypertension for 2 to 3 years and rheumatoid arthritis for 2 years. There was no history of hospitalization or surgery.

On examination her pulse was 90 beats/ minute, blood pressure was 125/90 mm Hg, temperature of 99°F. Her chest, abdomen and neurological examination was normal however she had a tender soft swelling

on the right side of the neck with associated palpable lymph nodes in the right cervical chain. Her laboratory investigations showed increased ESR.

An ultrasound of neck swelling was requested which revealed multiple enlarged lymph nodes in the neck along the cervical chain on the right side. Largest confluent one measured 1.6 x 1.5 cm. An ill-defined hypoechoic area measuring 2.0 x 1.5 x 1.1cm was seen in the right side of the neck showing moving echoes within it. The volume was approximately 2 ml. On the basis of ultrasound findings a diagnosis of cervical lymphadenopathy with small abscess/collection probably due to rupture of infective nodes was suggested. Ultrasound guided aspiration of this abscess was performed and sent for laboratory evaluation which showed presence of acid fast bacilli confirming diagnosis of tuberculosis.

Subsequently an MRI of neck was performed to rule out tuberculous osteomyelitis in the cervical spine. In MRI neck there was no evidence of discitis or osteomyelitis in the cervical spine, however, incidental note was made of a small cystic structure in the left neural foramen at C6-C7 level communicating with and closely related to the facet joint. It appeared homogeneously isointense to the CSF on T1 and T2 weighted images and there was no enhancement (Fig 1 & 2). Minimal degenerative changes were seen in the facet joint. Since the cyst was asymptomatic and an incidental finding, no surgical intervention was done for this cyst.

Patient was planned to be started on anti tuberculous therapy on her follow up visit which had not occurred till the writing of this report.

Correspondence : Dr. Zahid Anwar Khan
Department of Radiology,
Aga Khan University Hospital,
Stadium Road, P.O. Box 3500, Karachi 74800
Pakistan. Tel. No: 34930051 - Ext. 2020
E mail: zahid.anwar@aku.edu

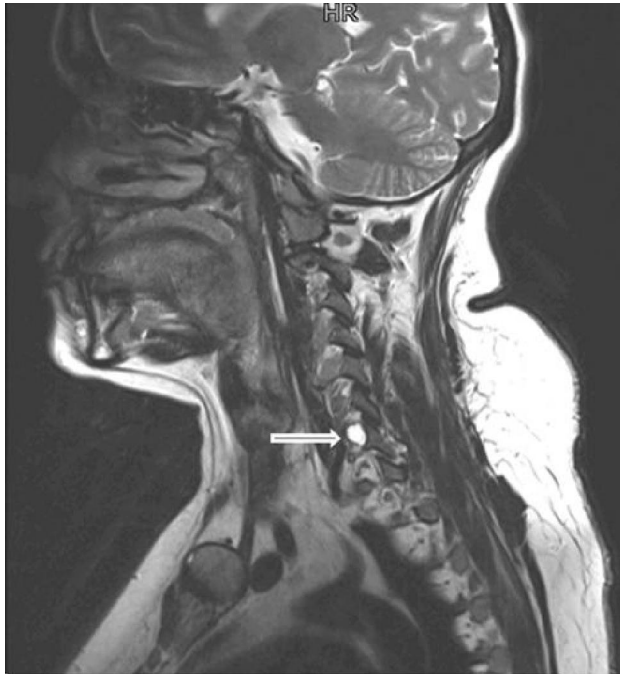

Figure 1: T2 weighted sagittal images demonstrate a well defined fluid signal intensity lesion in left C6-C7 neural foramen (arrow) closely related to facet joint

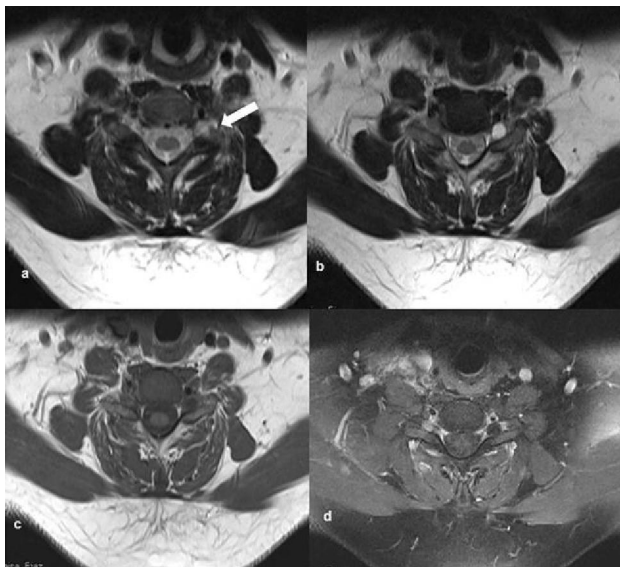


Figure 2: Axial images at C6-C7 level showing extradural cyst in left neural foramen appearing hyperintense on T2 (a,b) and hypointense on T1 (c). Note communication of the cyst with facet joint (arrow). On T1 weighted Fat suppressed image (d) there is no post contrast enhancement.

Discussion

The term juxtafacet cyst encompasses intraspinal extradural cystic lesions that have an anatomic relationship to the facet synovial joint.⁸ The cysts are

typically unilateral, often asymptomatic and incidentally seen on imaging, but occasionally they may cause radicular compression giving rise to pain and radiculopathy. Symptoms may be precipitated by trauma or an acute episode of hemorrhage in the cyst. The mechanism of cyst formation is not well understood. Synovial cysts are usually believed to develop as a result of degenerative disease of joints and represent herniations of the joint synovium, however a communication with the joint may not be demonstrated on imaging. On the other hand ganglion cysts are believed to form from mucinous degeneration within periarticular dense fibrous connective tissue.

MR imaging due its multiplanar capabilities and excellent contrast resolution offers definite soft tissue characterization and demonstrates cystic nature of these lesions. It may also demonstrate accompanying degenerative changes in facet joints. The classic appearance is of a cystic lesion having signal intensity similar to CSF.⁹ Occasionally there may be hemorrhage or calcifications in the cysts giving a inhomogeneous signal.¹ Synovial cysts and ganglion cysts have a similar appearance on imaging but can be differentiated on basis of histopathology.¹⁰

Asymptomatic patients are best managed conservatively. Rarely some of the symptomatic patients may also report improvement of symptoms without any treatment. Laminectomy and surgical excision of the cyst is considered in symptomatic patients but before undertaking invasive surgical procedures it is important both for the surgeons and radiologists to be familiar with the radiological appearance of these cysts and to exclude other differential diagnosis like Tarlov's perineural cysts, extradural arachnoid cyst and neuromas with cystic changes. Diagnostic features which can help differentiate foraminal or extraforaminal cystic neuromas from juxtafacet cysts include typical dumbbell shaped configuration of the mass and avid post contrast enhancement of solid component in the neuromas.

Conclusion

Juxtafacet cysts are rare lesions of the cervical spine. Our report emphasizes on radiological findings of this uncommon but important entity to avoid diagnostic confusion and management dilemma.

References

1. Kivrak AS, Koc O, Emlik D, Kiresi D, Odev K, Kalkan E. Differential diagnosis of dumbbell lesions associated with spinal neural foraminal widening: imaging features. *Eur J Radiol.* 2009; **71(1)**:29-41.
2. Costa F, Menghetti C, Cardia A, Fornari M, Ortolina A. Cervical synovial cyst: case report and review of literature. *Eur Spine J.* 2009 Jul 15.
3. Kahilođullari G, Tuna H, Attar A. Management of spinal synovial cysts. *Turk Neurosurg.* 2008; **18(2)**:211-4
4. Jost SC, Hsien Tu P, Wright NM. Symptomatic intraosseous synovial cyst in the cervical spine: a case report. *Spine (Phila Pa 1976).* 2003; **28(17)**: E344-6
5. Song JK, Musleh W, Christie SD, Fessler RG. Cervical juxtafacet cysts: case report and literature review. 2006; **6(3)**: 279-81.
6. Akhaddar A, Qamouss O, Belhachmi A, Elasri A, Okacha N, Elmostarchid B, Boucetta M. Cervico-thoracic juxtafacet cyst causing spinal foraminal widening. *Joint Bone Spine* 2008; **75(6)**:747-9.
7. Maupin WB, Naul LG, Kanter SL, Chang CS. Synovial cyst presenting as a neural foraminal lesion: MR and CT appearance. *AJR Am J Roentgenol.* 1989 ;**153(6)**:1231-2.
8. Vastagh I, Palásti A, Nagy H, Veres R, Bálint K, Karlinger K, Várallyay G. Cervical juxtafacet cyst combined with spinal dysraphism. *Clin Imaging* 2008; **32(5)**: 387-9.
9. Shima Y, Rothman SL, Yasura K, Takahashi S. Degenerative intraspinal cyst of the cervical spine: case report and literature review. *Spine* 2002; **27(1)**: E18-22.
10. Khosla A, Wippold II FJ. CT myelography and MR imaging of extramedullary cysts of the spinal canal in adult and pediatric patients. *AJR Am J Roentgenol* 2002; **178**: 201–7.