

# DIAGNOSTIC VALUE OF SONOGRAPHY IN DIFFERENTIATING OF MALIGNANT AND BENIGN BREAST MASSES

Farshchian Nazanin,<sup>1</sup> Farshchian Negin,<sup>2</sup> Iranfar Shirin,<sup>1</sup> Rezaie Mansour,<sup>3</sup> Mirbahari Seyyed Ghasem<sup>4</sup>

<sup>1</sup> Department of Radiology, Kermanshah University of Medical Sciences, Iran

<sup>2</sup> Department of Radiotherapy, Isfahan University of Medical Sciences, Iran

<sup>3</sup> Department of Biostatistics, Kermanshah University of Medical Sciences, Iran

<sup>4</sup> Department of Pathology, Kermanshah University of Medical Sciences, Iran

PJR July - September 2009; 19(3): 74-76

## ABSTRACT

**OBJECTIVE:** Breast cancer is one of the most common cancers among women throughout the world. The present study was performed to determine the diagnostic value of sonography for identifying the benign or malignant breast tumors in Kermanshah University of Medical Sciences (Breast Clinic of Mo'tazedi Hospital) during the year 2008.

**MATERIAL AND METHODS:** This descriptive study was carried out on 73 female patients having presumed clinical mass. They were examined by gynecologists, and then the benignity or malignancy of masses was determined using Sonography. For pathological tests, the biopsy was performed and the samples were sent to the Pathological Lab. The studied variables included age, marital status, the number of children, breast-feeding, mass location, and the reports of pathology and sonography.

**RESULTS:** The mean age of the patients and the number of their children were 41 and 3, respectively. In addition, 79.5% of patients were married, and 75.3% of them had a history of breast-feeding. Sonography diagnosed 68.5% of the masses, as being benign, while pathological tests rate was 63%.

**CONCLUSION:** Based on the results, because of sensitivity and characteristic of sonography, the first step to diagnose malignant masses should be sonography and, only then, if necessary, the application of other methods is recommended. To confirm the accuracy of the findings of this research, carrying out further studies with more samples is suggested.

**Keywords:** Diagnostic value, sonography, malignant breast masses

## Introduction

For many years, breast cancer has been among the most prevalent cancers and the most causative agent of mortality among women. In many countries, breast cancer is the most reason of women's death at the ages of 35-45.<sup>1,2</sup> In the US, approximately 180 000 new cases of invasive breast cancer and 25 000 carcinoma in situ are diagnosed annually. About 30 000 to 40 000 of women in the US die from breast cancer each year.<sup>3</sup> The annual incidence rate of breast cancer in Iran is 22.4 per 100 000 people, which

is one fifth of mentioned density of the US.<sup>4</sup> The risk factors in breast cancer are including gender, age, the occurrence of menstruation at low ages, lack of previous pregnancy or delivery, having a family or self-history of breast cancer and atypical epithelial proliferation, exposure to radiation, and finally diet habits.<sup>1</sup> Imaging techniques including sonography, mammography, Doppler sonography, MRI and elastography are used to study breast-related diseases. However, the gold standard methods for studying breast masses are biopsy and pathological diagnosis;<sup>5</sup> nowadays the biopsy is used less frequently as the first step of diagnosis. Mammography is the most proper method for early diagnosis of breast cancer. However, mammography has high sensitivity; its specificity is nearly low. As a result, a high percent of lesions

**Correspondence** : Nazanin Farshchian, MD.  
Department of Radiology,  
Imam Reza Hospital,  
P.O.Box: 67571, Kermanshah, Iran.  
Tel: 98-831-4276473, Fax: 98-831-4276471  
E-mail: farshchian.n@gmail.com

determined as malignant by mammography, is considered as benign via biopsy. In addition, the interpretation of mammography results is time-consuming.<sup>6</sup> Sonography is an easy and inexpensive method which has high reproducibility and is agreeable for patients. The significance of mammography is the diagnosis of cystic and tumor lesions in breast. Different studies have shown that sonography has nearly high sensitivity in determining of benign and malignant masses of breast;<sup>7-10</sup> however some reports have refused such a sensitivity rate.<sup>3</sup> Due to patient's inclination to sonography, and the mammography problems in diagnosing of benign and malignant masses, needing much time to interpret, lack of sufficient studies and existence of inconsistent views on its capability compared to mammography in our country, this study was carried out. The aim of this study was to determine the diagnosis value of sonography for differentiating the benign from malignant breast masses of patients in Mo'tazedi Hospital of Kermanshah University of Medical Sciences in 2008.

## Material and Methods

The sample size was determined using the formula of qualitative methods on 73 patients having clinical masses. The studied patients were chosen from women with presumed breast masses, referred to Breast Clinic of Mo'tazedi Hospital. The breast masses of the patients were first examined by gynecologists. When masses were diagnosed using a Honda 2000 sonography set, the malignancy or benignity of masses were investigated. If the masses had 3 out of the 7 criteria of malignant masses such as depth, variability, irregularity in echogenic halo, hypogenicity with low-level marked and non-uniformity, the masses were recognized as malignant masses. Tissue samples or biopsies were obtained, and transferred to the Lab for pathological studies. The pathological reports were managed as gold-standard. The examined variables were age, marital status, number of children, breast-feeding, mass location, pathology and sonography reports (regarding benignity or malignancy of masses). Finally, the yielded data were analyzed utilizing frequency, percentage, one and two-dimensional tables; the criteria of diagnostic value included sensitivity,

characteristic, the positive and negative indicative values, and accuracy rate of distinguishing the malignant masses.

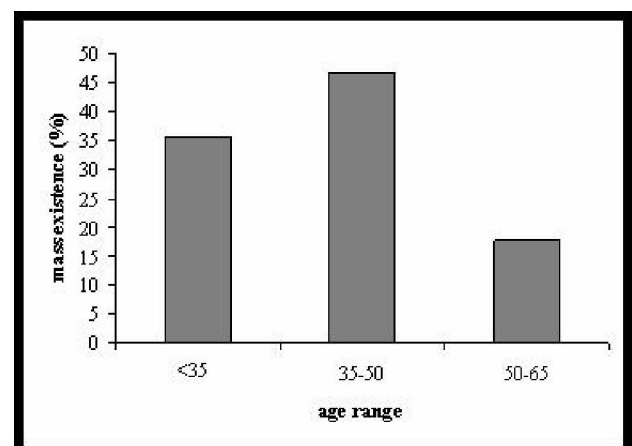
## Results

(Tab. 1) shows the distribution of breast masses types by sonography based on breast-feeding of the studied patients. Whereas sonography confirmed the 68.5% of masses as benign, pathology reports indicated 63% of the cases as benign masses. Furthermore, sonography had 81.5% of sensitivity, 97.8% specificity, 95.6% positive predictive value, 90% negative predictive value, and 91.8% accuracy in differentiating between benign and malignant breast masses.

A history of breast feeding	Yes Number (Percent)	No Number (Percent)	Total of samples Number (Percent)
<b>Mass type</b>			
<b>Benign</b>	34 (68)	16 (32)	50 (100)
<b>Malignant</b>	21 (91.3)	2 (8.7)	23 (100)
<b>Total</b>	55 (75.3)	18 (24.7)	73 (100)

**Table 1.** Distribution of breast masses types by sonography based on history of breast-feeding of the studied patients in Breast Clinic of the Center Training and Treatment of Mo'tazedi Hospital Kermanshah University of Medical Sciences during the year 2008.

The mean age of the patients was 41 years (range: 16–65 years), the majority of them were between 35 to 50 years old (Fig. 1). In addition, 79.5% of patients were married and 75.3% of them had a history of breast-feeding. The mean number of their children was 3.



**Figure 1.** The age range of 73 patients having presumed breast masses of breast clinic of Mo'tazedi Hospital of Kermanshah University of Medical Sciences in 2008.

## Discussion

The results of this study showed that sonography has 81.5% sensitivity and 97.8% characteristic in differentiating between benign and malignant breast masses. The findings of other scientists also confirm our results (Guila in;),<sup>7</sup> while Nyström and colleagues believed that mammography is still more suitable than sonography in this regard.<sup>6,11</sup> Sonography can have a proper position in imaging techniques of breast masses, because of having some advantages such as; simplicity, admission on part of the patients, cost-effective, and its potential in differentiating benign from malignant masses, and because of not using ionization rays. However biopsy is the gold standard for the assessment of breast masses, it is an invasive method and not acceptable for patients. Furthermore, performing biopsy and its resultant scars leads to confusion in the follow-up procedures. The results of the studies like this in other countries are not consistent with the carried out studies in Iran. This disagreement may be due to the type of methods of study, experience of sonographer and the applied instruments. According to previous experiments, sonography is used as a complementary method for mammography, and, if necessary, using of sonography after mammography is suggested.<sup>11</sup> But the present study showed that sonography has also a proper precision in differentiating benign from malignant masses and can be used as the initial method for breast cancer diagnosis.

In general, the findings of this study illustrate that sonography has high sensitivity and characteristic in differentiating between benign and malignant breast masses. Thus, it seems that sonography can be utilized as the first step in testing breast masses. In order to obtain sufficient data, if needed, more studies with further samples should be carrying out in this regard.

## Acknowledgment

We are thankful to all of the colleagues and patients who made this study possible. We are also very grateful to Pars Lab personnel for their much contribution.

## References

1. Courtney MT, Beauchamp RD, Evers BM, Kenneth LM. Sabiston text Book of surgery. 17th ed. USA: Elsevier; 2004: p. 867-947.
2. Godazandeh GhA, Khani H, Khalilian AR, Atarod Z, Firoz Jaei MA, Partovi A, et al. Knowledge and practice of above 15 years old females towards breast cancer prevention in Sari Town ship, J Mazandaran U Med Sci. 2006; **16 (52)**: 64-74.
3. Zhi H, Ou B, Luo BM, Feng X, Wen YL, Yang HY. Comparison of ultrasound elastography, mammography, and sonography in the diagnosis of solid breast lesions. J Ultrasound Med. 2007; **26**: 807-15.
4. Yavari P, Mousavizadeh MA, Sadr Alhefazi B, Khodabakhsh R, Madani H, Mehrabi Y. Reproductive specificity and the risk of breast cancer: a case-control study. Iran J Epidemiol. 2006; **1(2)**: 11-9.
5. Vargas HI, Agbunag RV, Khalkhali I. State of the art of minimally invasive breast biopsy: Principles and practice. J Breast Cancer. 2000; **7(4)**: 370-9.
6. Nyström L, Andersson I, Bjurstam N, et al. Long-term effects of mammography screening: updated overview of the Swedish randomized trials. Lancet. 2002; **359**: 909-19.
7. Rahbar G, Sie AC, Hansen GC, and et al. Benign versus Malignant Solid Breast Masses: US Differ Radiol. 1999; **213**: 889-94.
8. Moazzam M, B. Ultrasound differentiation of benign versus malignant solid breast masses. 2004; **14 (3)**: 166-9.
9. Benson SRC, Blue J, Judd K, Harman JE. Ultrasound is now better than mammography for the detection of invasive breast cancer. A J Surg. 2004; **188**: 381-5.
10. Gordon S. Sonography Superior for some breast cancer more accurate than mammography for women under 45 with symptom health on the set foundation. 2004; Available from: [www.home.ch/news](http://www.home.ch/news)].
11. Mansourian HR, Nikoukar L. Comparison of findings of the mammography and sonography with tissue pathology in over-30-year old women with breast masses. J Shahid Sadoughi U Med Sci & Health Ser. 2000; **7(4)**: 8-15.