

RETRIEVAL OF BROKEN INTRAVASCULAR CATHETER PERCUTANEOUSLY

Amin Rajani, Basit Salam, Mohammad Arshad, Saqib Qazi

Department of Radiology, Aga Khan University Hospital, Karachi Pakistan.

PJR January - March 2009; 19(1): 27-29

Introduction

Percutaneous retrieval of intravascular foreign bodies has been described by many as a frequently applied technique. It is being done frequently in many centers today since its first description more than three decades ago.¹

The rapid development and wide application of minimally invasive and interventional techniques are associated with an increased rate of specific method-related complications caused by intravascular foreign bodies or resulting from dislocation of vascular endoprostheses as well as intravascular catheters that are placed for various reasons. We present a case of a young child with broken intravascular catheter.

Case History

A 6 months old child (girl) with known case of factor x deficiency was admitted for FFP's transfusion and removal of double lumen tunneled catheter (Hickman line), which was placed in her superior vena cava via the right subclavian approach. While removing the catheter under L/A, the catheter was fractured during breaking of adhesions, distal end was explored through the same site, but could not be removed. On x-ray the distal end of catheter was found in IVC. Baby was vitally stable and Radiology VIR team was called for percutaneous removal of broken catheter fragment from right atrium. The catheter was removed percutaneously via the right femoral vein approach using snare technique and 5 Fr. vascular sheath.

Correspondence : Mr. Amin A. Rajani
Department of Radiology,
Aga Khan University Hospital,
Stadium Road, P.O. Box 3500, Karachi 74800
Pakistan. Tel. No: 34930051 - Ext. 2020
Email: rajani.amin@aku.edu

Discussion

As intravascular endoprosthesis as well as intravascular catheters are placed more frequently for various reasons and intravascular foreign bodies are being reported more frequently. Percutaneous treatment of intravascular foreign body's retrieval continues to be safely and effectively applied in numerous patients. "Dotter et al.⁴ in the first review of the percutaneous retrieval of intravascular foreign bodies refer exclusively to catheters and wire fragments, but now the spectrum of intravascular devices and objects has broadened significantly to include items such as vena cava filters, embolization coils, and endovascular stents".

"The rate of broken venous catheters has been estimated at 0.1%"¹ and there has been no available data for other types of objects, such as broken guide wires or lost embolization coils. "The rate of serious complications associated with foreign body embolism has been reported as high as 71%,² with a mortality rate in the range of 24-60%".^{2,4} In particular, cardiopulmonary localization of these foreign bodies causes greater risk of complications ranging from cardiac arrhythmias to perforation.³

Results from the percutaneous treatment of intravascular foreign bodies continue to prove the procedure's capabilities as a highly efficient, a traumatic method with success rates of 90% or above which is being observed in multiple studies and case reports. Numerous available rescue devices can be adapted to the situation at hand and permit a safe retrieval of the intravascular foreign body, even in difficult cases.

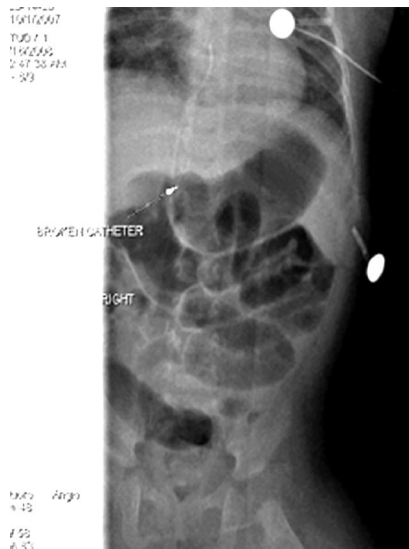

Figure 1: Broken Hickman

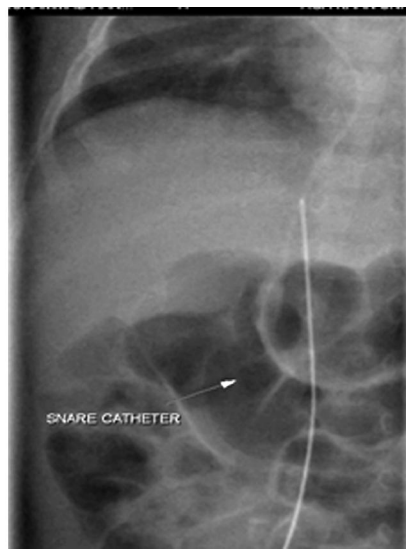

Figure 2: Snare Catheter

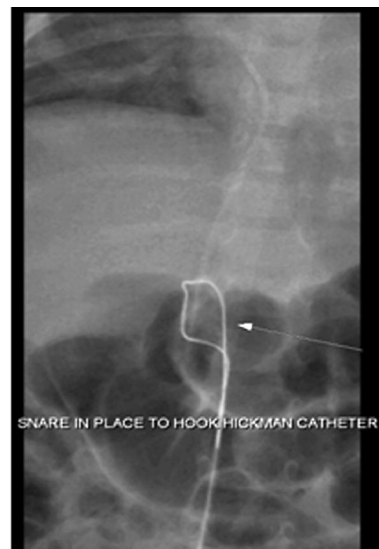


Figure 3: Snare in place to hook Hickman Catheter

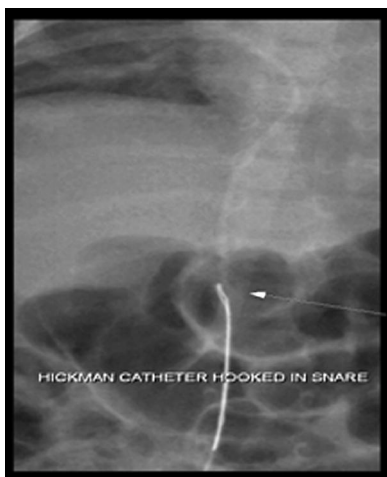


Figure 4: Hickman Catheter hooked in Snare

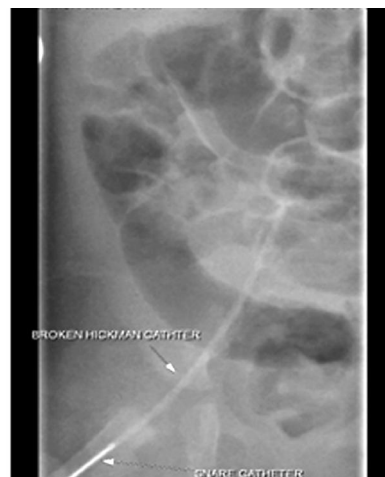

Figure 5: Retrieved Broken Hickman Catheter now in sheath, hooked with Snare

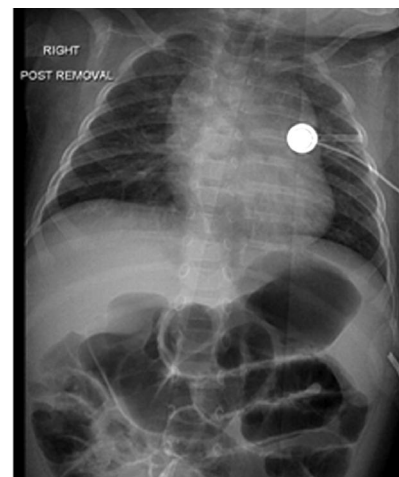
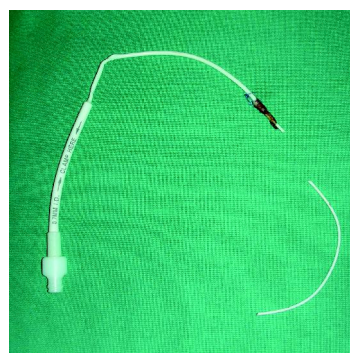
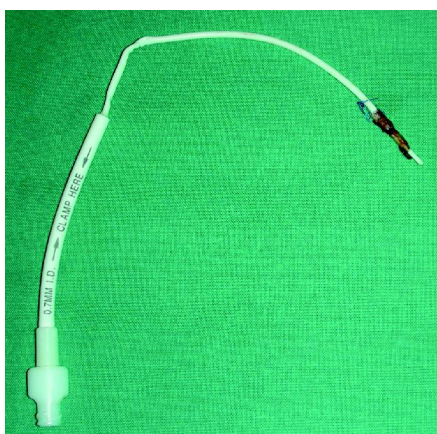



Figure 6: Post removal of Broken Hickman Catheter



Broken Hickman Catheter



References

1. Thomas J, Sinclair-Smith B, Bloomfield D, Davachi A. Non-surgical retrieval of a broken segment of steel spring guide from right atrium and inferior vena cava. *Circulation* 1964;**30**:106-8
2. Uflacker R, Lima S, Melichar AC. Intravascular foreign bodies: percutaneous retrieval. *Radiology* 1986;**160**:731-735
Eggin TK, Dickey KW, Rosenblatt M, Pollak JS. Retrieval of intravascular foreign bodies: experience in 32 cases. *AJR* 1995;**164**:1259-64
3. Eggin TK, Dickey KW, Rosenblatt M, Pollak JS. Retrieval of intravascular foreign bodies: experience in 32 cases. *AJR* 1995;**164**:1259-64
4. Dotter CT, Rosch J, Bilbao MK. Transluminal extraction of catheter and guide fragments from the heart and great vessels: 29 collected cases. *AJR* 1971;**111**:467-72