

M.R.I APPEARANCES OF OVARIAN TORSION

Saira Naz, Rubina Hussain, Saba Jamal, Zafar Sajjad

Department of Radiology, Ziauddin University Hospital, Karachi, Pakistan.

PJR January - March 2009; 19(1): 20-22

ABSTRACT

A case of ovarian torsion is presented here. The patient presented with the history of recurrent attacks of abdominal pain. M.R.I revealed an enlarged twisted ovary. On laparotomy, there was a twisted left ovary treated oophorectomy with conservation of left fallopian tube.

Introduction

Torsion of the normal adnexa usually occurs in first decade of life and is less common than torsion of an ovary containing a mass. It is thought to be related to the particular mobility of the pediatric adnexa, which allows twisting at mesosalpinx as a result of change in intraabdominal pressure or in body position.¹ 50% of patients have a history of pain with spontaneous recovery.^{2,3} Although torsion may occur with normal ovaries, most reported cases have involved children with ovarian masses, or in women younger than 30 years of age. There is a rotation of the ovary or adnexa about the ovarian pedicle, causing lymphatic obstruction followed by venous then arterial obstruction.

Case History

A 13 years old unmarried girl presented with the history of severe and sharp non radiating pain in the left lumbar region associated with vomiting. She had a similar episode 3 years ago, but that was subsided spontaneously.

On abdominal examination there was tenderness in left lower abdomen on deep palpation but no mass was palpable. Her ultrasound showed a large heterogeneous mass in cul-de-sac, measuring

8.6×6.0×7.0 cm. The ultrasound appearances were nonspecific and the possibility of an inflammatory mass was raised. Magnetic Resonance Imaging (M.R.I.) was performed to characterize the lesion further. MRI findings were; a massive enlargement of left ovary measuring 10×6.0×7.0cm, ovary exhibit homogeneously low signals on T1 (Fig. 1) and mixed high signals on T2 images with multiple tiny follicles, aligned peripherally (Fig. 2).

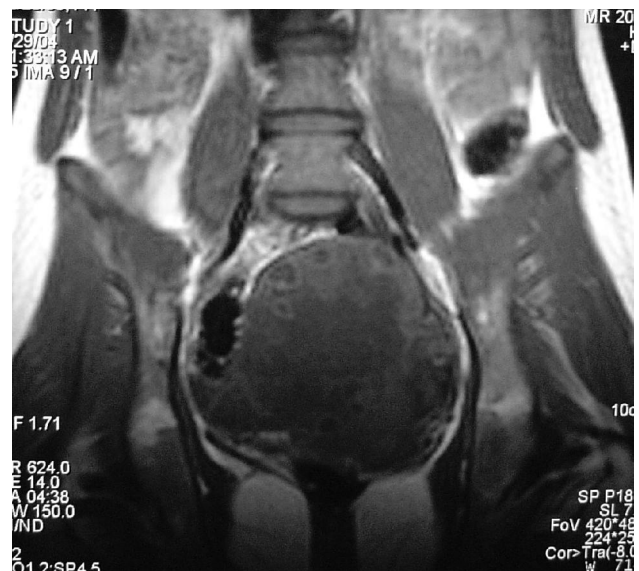


Figure 1: MRI T1 IMAGE; Ovary exhibit homogeneously low signals.

Correspondence : Dr. Saira Naz
Department of Radiology,
Ziauddin University Hospital,
Karachi, Pakistan.
Tel No: 36649800
E-mail: sheikh.sufian@gmail.com

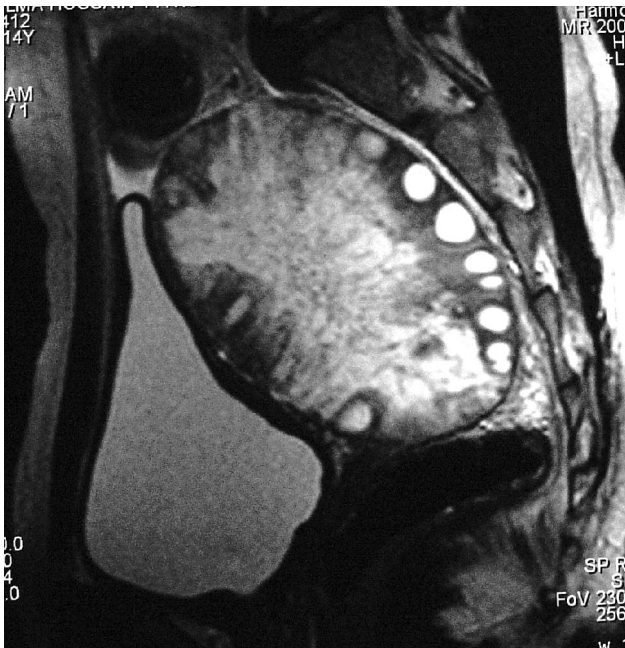

Figure 2: MRI T2 IMAGE; Ovary shows mixed high signals with multiple tiny follicles, aligned peripherally.

The size of the follicles was not exceeding then 1.0 cm. Ovary was smooth in outline with prominent beaked left pedicle. Uterus was pulled towards the side of lesion (Fig. 3); uterus itself was within normal limits.

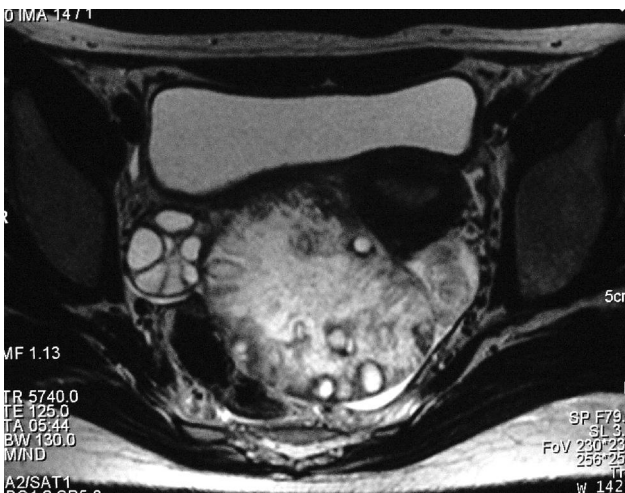


Figure 3: MRI T2 IMAGE; Uterus is pulled towards the side of lesion; uterus itself is within normal limits.

Minimal ascitic fluid also noted. A provisional diagnosis of ovarian torsion was made. Laboratory tests, including HB=6.7, PCV=23, WBC=10.2, CA.125=11.1, platelets=208, serum amylase= 91. Laparotomy was performed. Left ovary was enlarged measuring 10×12 cm, full of blood clots; twisted 1 and 1/2 turns on its pedicle. Left fallopian

tube was edematous' hemorrhagic and blackish .Minimal free fluid was found. Left ovary was totally removed with conservation of left fallopian tube. Grossly, the ovary was dark grey in color with smooth outer surface; size was 10×10×6.0cm. on cut section, lumen was filled with blood (Fig. 4).

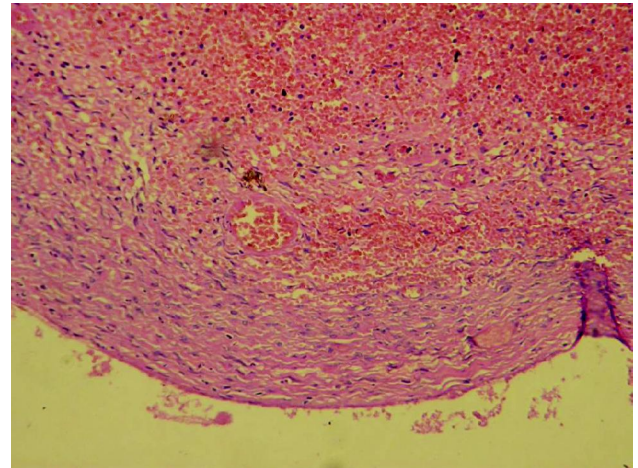


Figure 4: HIGH POWER OVARIAN TISSUES; Showing hemorrhage.

Microscopically, there was no malignant cell. The histopathological diagnosis was hemorrhagic infarction of ovarian tissues; ovarian torsion.

Discussion

Torsion of ovarian pedicle produces circulatory stasis that is initially venous, but it becomes arterial as torsion and resultant edema progresses. Ultrasound findings including solid, cystic complex mass with or without fluid in the cul-de-sac, are non specific findings because of variable appearance of the associated ovarian pathologic conditions^{4,5,6,7} and the role of color Doppler sonography to diagnose ovarian torsion is still not fully established.^{8,9,10,11} The specific sign of torsion is demonstration of multiple follicles of uniform size (8-12mm in diameter) in the cortical portion of a unilaterally enlarged ovary in the prepubertal age group ,in which the presence of enlarged follicles is not expected.¹² Transvaginal Ultrasound is more helpful, but is not feasible in prepubertal age group.

Common CT and MRI findings with adnexal tumors with torsion with or without hemorrhagic infarction are deviation of the uterus to the twisted side, engorgement of the blood vessels on the twisted side, a small amount of ascites, and obliteration fat planes around the tumor. Deviation of the uterus to the twisted side is because

the torsion and adhesion naturally shorten the supporting system of the uterus on the twisted side. The engorgement of blood vessel on the twisted side represents venous congestion distal to torsion. As MRI is an excellent modality for the demonstration of blood vessels, engorgement of the vessels is distinct and easily identified. A small amount of ascites and obliteration of fat planes indicate transudation of fluid and adhesion of the lesion to the surrounding structure. However, these findings are nonspecific. The lesions with hemorrhagic infarction exhibited unusual and characteristics findings, such as beaked or serpentine protrusion at periphery of the twisted side; the presence of hematoma and lack of enhancement. The presence of a tubular protrusion on the twisted side likely indicates a twisted edematous pedicle, which connects the lesion with the uterus and enveloped engorged blood vessels. The demonstration of thick, straight blood vessels that drape around the tumor indicates markedly congested vein on the surface of the tumor distal to the torsion. The hematoma directly represents hemorrhagic infarction. The signal intensity of the entire lesion is variable and thus likely a result of the mixture of the original fluid and hemorrhagic necrotic tissue.¹³

Conclusion

Ovarian torsion is a serious relatively uncommon complication of ovarian mass lesion. It may also occur in otherwise normal ovary

References

- Haller JO, Fellow RA. The pelvis. In: Haller JO, Shkolnik A, eds. *Ultrasound in pediatrics (clinics in diagnostic ultrasound, vol. 8)*. New York: Churchill Livingstone; 1981.
- Alrabeeh A, Galliani CA, Giacomantonio M, et al. Neonatal ovarian torsion: report of three cases and review of the literature. *Pediatric Pathol*. 1988;**8**: 143-9.
- Fleischer AC, Shawker TH. The role of Sonography in pediatric Gynecology. *Clin Obstet Gynecol*. 1987;**30**:735-46.
- Helvie MA, Silver TM. Ovarian torsion: Sonographic evaluation. *JCU* 1989;**17**:327-32.
- Warner MA, Fleischer AC, Edell SL, et al. Uteroadnexal torsion: Sonographic findings. *Radiology* 1985;**154**:773-5.
- Farrell T, Boal D, Teele R, et al. Acute torsion of normal uterine adnexa in children: Sonographic demonstration. *AJR* 1982;**139**:1223-5.
- Graif M, Itzchak Y. Sonographic evaluation of ovarian torsion in childhood and adolescence. *AJR* 1988;**150**:647-9.
- Van Voorhis BJ, Schwaiger J, Syrop CH, Chapler FK. Early diagnosis of ovarian torsion by color Doppler ultrasonography. *Fertil Steril* 1992;**58**:215-7.
- Fleischer AC, Kepple DM. Transvaginal color duplex sonography: clinical potential and limitations. *Semin Ultrasound, CT, MRI* 1992;**13**:69-80.
- Fleischer AC, Rao BK, Kepple DM. Transvaginal color Doppler. In: Fleischer AC, Kepple DM, eds. *Transvaginal sonography: a clinical atlas*. Philadelphia, Pa: Lippincott, 1992; 273-5.
- Rosado WM Jr, Trambert MA, Gosink BB, Pretorius DH. Adnexal torsion: diagnosis by using Doppler sonography. *AJR* 1992;**159**:1251-3.
- Graif M, Shalev J, Strauss S, Engelberg S, Mashiach S, Itzchak Y. Torsion of the ovary; sonographic features. *AJR* 1984; **143**:1331-4.
- Kimura I, Togashi K, Kawakami S, Takakura K, Mori T, Tonishi J. Ovarian torsion: CT & MR imaging appearances. *Radiology* 1994 Feb;**190**(2):337-4.