

# NATURAL HISTORY OF DEGENERATIVE DISC DISEASE UNDERGOING CONSERVATIVE MANAGEMENT. ASSESSMENT AND CT FINDINGS.

Tariq Alam<sup>1</sup>, Hina Gul<sup>1</sup>, Inayat Shah Roghani<sup>1</sup>, Shehryar bin Ayub<sup>1</sup>, Shafqat<sup>1</sup>, Zakia<sup>1</sup>, Umara<sup>1</sup>, Zainab Afridi<sup>1</sup>, Mumtaz<sup>2</sup>

<sup>1</sup> Department of Diagnostic Radiology, Khyber Teaching Hospital, Peshawar, Pakistan.

<sup>2</sup> Department of Neurosurgery, Lady Reading Hospital, Peshawar, Pakistan.

PJR April - June 2008; 18(2): 37-41

## ABSTRACT

The natural history of sciatica in conservatively treated patient is not entirely clear. This study was undertaken to see morphological changes in the herniation accompanying natural resolution of sciatica. CT imaging of lumbar spine was performed for 100 patients presenting to neurology clinic with sciatica. Follow up CT of pathological disc was performed for 72 out of hundred patients after 1 year. During 1-year, period patients were treated conservatively with epidural injection of steroids and local anesthetics. 45(75%) out of 60 patients with disc herniation or sequestration showed partial or complete resolution. 2(6.06%) patients out of 33 patients with a generalized or local bulge showed partial or complete resolution, and 24(72.72%) patients did not demonstrate any change on follow up CT examination. Younger patients with disc herniation or sequestration having symptoms for shorter duration, showed more improvement on follow up CT examination

**KEY WORDS:** Sciatica, Disc Disease, CT scan

## Patients and Methods

### Patient Selection

Total of 100 patients, 62 males and 38 females between 18-70Yrs of age (mean age 40 yrs) with sciatica of less than 12 weeks duration (average duration 4 weeks) were selected for the study. All neurosurgeons and radiologists involved were informed about the study and received information about development and results of trial. They referred patient within first 6 – 12 weeks after onset of sciatica.

During first visit to neurology OPD, complete history was taken and detail neurological examination, including examination for root tension signs (positive straight leg raise and femoral stretch test) and neurological signs (altered sensation, diminished or absent reflexes or reduced power) was done.

After confirmation of diagnosis, CT scan examination was performed after informed consent. High-resolution

images were obtained at L3/L4, L4/L5 and L5/S1 interspaces to include all intervertebral foramina. Patients, whose CT scan examination confirmed disc herniation and met eligibility according to inclusion and exclusion criteria were admitted to the study.

## Selection Criteria for Trial Eligibility

### Inclusion Criteria.

- Age 18-70 years.
- Persistent radicular pain in the L4, L5 as S1 dermatome with or without mild neurological deficits
- Evidence of disc herniation or bulge on CT

### Exclusion Criteria

- Cauda equina syndrome
- History of disc surgery on same level
- Degenerative or lytic spondylolisthesis
- Pregnancy
- Severe life threatening or psychiatric illness

**Correspondence :** Dr. Tariq Alam  
Department of Radiology,  
Aga Khan University Hospital,  
Stadium Road, P.O Box 3500, Karachi, 74800  
Pakistan. Tel. No. 4930051- Ext 2020  
E-mail: tariq.alam@aku.edu

CT examination findings were registered independently by radiologist and Neuro surgeons. Disc abnormalities were classified according to the generally accepted criteria as herniation, sequestration, generalized bulge and focal bulge.

## **Treatment**

During the study all therapeutic caudal epidural injections of local anesthetic and steroids were performed as OPD procedures without any premedication.

Before procedure informed consent was obtained. Procedure was performed by Neurosurgeon experienced in spinal interventions in accordance to standard protocols. Injections were given at intervals ranging from weeks to months depending on sign, symptoms and clinical response.

In a small number of patients in whom there was lateral nerve root compression, nerve root was outlined with contrast medium under fluoroscopic guidance and direct injection into appropriate nerve root canal was made at posteriolateral approach. On average patient received 3 injections (1-8) in 1 Year.

## **Patient Reassessment**

During reassessment visits, the patients were assessed for changes since the 1st visit to determine whether there was any improvement in the ability to perform normal routine activities and severity of pain. Detailed Neurological examination was performed to assess any changes in nerve root tension or neurological signs.

## **CT Reassessment**

After complete clinical evaluation, follow up CT scans were performed after 1 year.

Axial images were taken only at site of previous lesions. These images were compared with the one taken on initial visit. Changes were recorded by radiologist. Among total of 100 patients, 28 patients were not rescanned. They were divided into following groups

A. This group consists of 7 patients in whom no disc abnormality was identified on initial CT scan examination. Reason for their pain was bony abnormality.

B. 2nd group consists of 8 patients, they were not willing for re-scan as they were symptoms free after 1 year.

C. 3rd group consists of 9 patients in whom symptoms aggravated and were referred for decompressive surgery.

D. 4th group consists of patients, which were lost during follow up. Such patients were four in number.

72 out of 100 patients were scanned both by initial and follow up CT examination.

## **Results**

Out of 100 patients 93 patients were having disc abnormality on initial CT scan examination.

Out of 93, 72(77.41%) patients were rescanned on follow up. Out of 93, 48 (51.61 %) patients were having disc herniation, 12 (12.90%) patients with disc sequestration, 22 patients (23.65 %) with focal bulge and 11 patients (11.82 %) with generalized bulge.

### **Patients with disc herniation and sequestration**

Out of 60 patients with disc herniation or sequestration 43(71.66%) patients showed complete or partial resolution on follow up CT examination.

7(12%) out of 60 patients showed complete resolution while 36 (60%) patients showed partial resolution with disc herniation or sequestration. In 2(3.3%) patients with disc herniation or sequestration no change was seen. 3(5%) patients with disc herniation or sequestration did not come for follow up.

### **Patients with diffuse or focal bulge**

Out of 33 patients with disc bulge, only 2(6.06%) patients showed any resolution. 24 (72.72%) patients with disc bulge did not demonstrate any change. 1(3.03) patient with disc bulge was lost during follow up. It is very much obvious from results that patient with disc herniation and sequestration showed much better response to conservative treatment.

Patient showing resolution on follow up CT examination revealed marked improvement in severity of pain. Root tension signs resolved in all patients.

Male patients responded better as more female patients underwent decompression surgery Similarly younger patients' response was more than older patients. Patients with symptoms for shorter duration responded better as compared to patient with symptoms for longer period.

Results of our study are quite comparable with results of other studies conducted on lumbar disc changes accompanying natural resolution of Sciatica in the past.

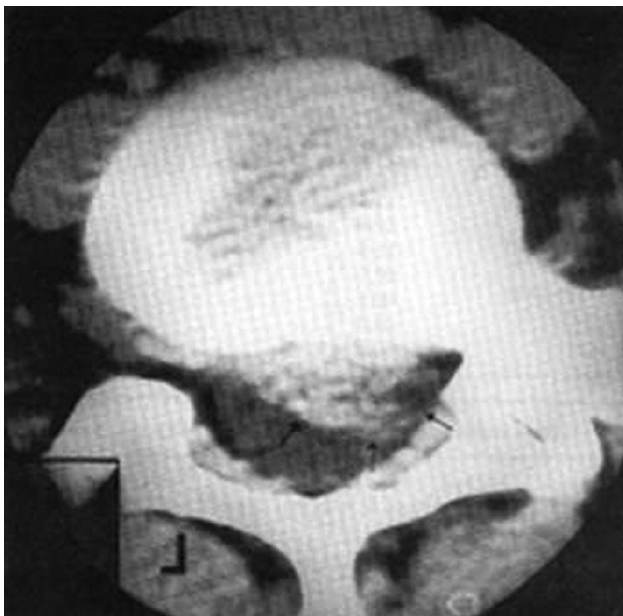
**Table 1: Comparison between the original and follow up CT examination**

Type of disc abnormality	Original CT examination No of cases	Flood up CT examination			
		Complete resolution	Partial resolution	No Change	Increased abnormality
Herniation and sequestration	60	7(12%)	36(60%)	2(3.3%)	1(1.6%)
Focal and diffuse disc bulge	33	0	2(6.06%)	24 (72.72%)	0
Total	93				

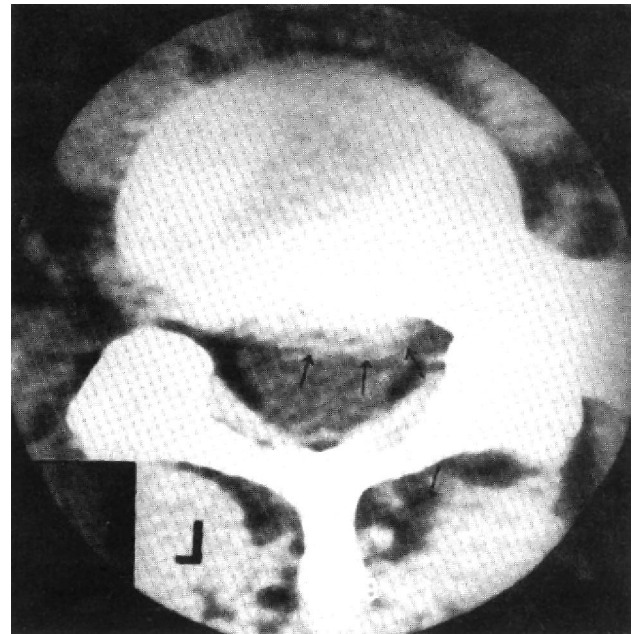
Total no of patients rescanned = 72

**Table 2: Comparison between the resolution of and no change of disc groups**

Variable	Resolution of disc group (45 discs) Mean	No Change of disc group (26 discs) Mean
Age (years)	37.47	42.61
Duration of symptoms (months)	3.50	7.12
Reduction of SLR	27.31	14.17



**Figure 1:** Right posteriolateral L5/S1 disc herniation in 32 yrs old presenting with 3 months of low back pain



**Figure 2:** Partial resolution of Right posteriolateral L5/S1 disc herniation in 32 yrs old male after conservative treatment

## Discussion

Many studies have been conducted on effectiveness of local anesthetic and steroid in management of low back pain and sciatica. It has been used since 1952 and is still integral part of non-surgical management of sciatica.

Studies have been conducted in past on spontaneous resolution of herniated nucleus pulposus. As obvious from results of this study a high percentage of patients showed partial or complete resolution of herniated disc in 1 year periods.

A number of mechanisms have been explained for this spontaneous resorption of disc. Although exact mechanism is unknown, it is obvious that resolution of herniated nuclear material occurs upon exposure to the environment of epidural space. This exposure triggers some activities which finally result in disc material resorption. Disc resorption in turn leads to an end to the mechanical effect of herniated disc upon a nerve root. Various mechanisms have been put forward to explain how the nuclear material shrivels up with time.

It can be due to enzymatic degradation of proteoglycans. There can be loss of water content with time, resulting in shrinkage of protruded disc material. Increased phagocytic activity and associated neovascularization leads to further clearance of herniated disc material.

Apart from mechanical effect, there are other factors like chemical & auto immune reactions leading to nerve root inflammation.

Epidural injection delivers steroids directly into epidural space in spine at site of lesion. It may flush out inflammatory mediators from around the area that may be a source of pain. This may happen without any discernible change on image. This may account for generally good progress of patients whose CT examinations were not reported to demonstrate any change.

## Conclusion

We have concluded that disc herniation of recent onset in young patients with marked reduction of straight leg raise and positive neurological signs has a potential for making natural recovery. Indeed disc herniation, the abnormality which might seem best suited to surgical resection, is the type of disc lesion showing the most significant incidence of natural regression.

## References

1. Abdi S, Datta S, Epidural steroids in the management of chronic spinal pain: a systematic review. *Pain Physician*. 2007 Jan;**10(1)**:185-212. Review.
2. Boswell MV, Shah RV, Everett CR, Sehgal N, McKenzie Brown AM, Abdi S, Bowman RC 2nd, Deer TR, Interventional techniques in the management of chronic spinal pain: evidence-based practice guidelines. *Pain Physician*. 2005 Jan;**8(1)**:1-47.
3. Fish DE, Shirazi EP, Pham Q. The use of electromyography to predict functional outcome following transforaminal epidural spinal injections for lumbar radiculopathy. *J Pain*. 2008 Jan;**9(1)**:64-70. Epub 2007 Nov 5.
4. Boswell MV, Trescot AM, Datta S, Schultz DM, Hansen HC, Abdi S, Sehgal N, Shah RV, Singh V, Benjamin RM, American Society of Interventional Pain Physicians. Interventional techniques: evidence-based practice guidelines in the management of chronic spinal pain. *Pain Physician*. 2007 Jan;**10(1)**:7-111.
5. Schaufele MK, Hatch L, Jones W. Interlaminar versus transforaminal epidural injections for the treatment of symptomatic lumbar intervertebral disc herniations. *Pain Physician*. 2006 Oct;**9(4)**:361-6.
6. Lutz GE, Vad VB, Wisneski RJ. Fluoroscopic transforaminal lumbar epidural steroids: an outcome study. *Arch Phys Med Rehabil*. 1998 Nov;**79(11)**:1362-6.
7. Nelemans PJ, de Bie RA, de Vet HC, Sturmans F. WITHDRAWN: Injection therapy for subacute and chronic benign low-back pain. *Cochrane Database Syst Rev*. 2007 Jul 18;**(2)**:CD001824. Review.
8. Vad VB, Bhat AL, Lutz GE, Cammisa F. Transforaminal epidural steroid injections in lumbosacral radiculopathy: a prospective randomized study. *Spine*. 2002 Jan 1;**27(1)**:11-6.
9. Friedly J, Chan L, Deyo R. Increases in lumbosacral injections in the Medicare population: 1994 to 2001. *Spine*. 2007 Jul 15;**32(16)**:1754-60.
10. Sabers SR, Ross SR, Grogg BE, Lauder TD. Procedure-based nonsurgical management of lumbar zygapophyseal joint cyst-induced radicular pain. *Arch Phys Med Rehabil*. 2005 Sep;**86(9)**:1767-71.
11. Friedly J, Chan L, Deyo R. Geographic variation in epidural steroid injection use in medicare patients. *J Bone Joint Surg Am*. 2008 Aug;**90(8)**:1730-7.
12. Koes BW, Scholten RJ, Mens JM, Bouter LM. Efficacy of epidural steroid injections for low-back pain and sciatica: a systematic review of randomized clinical trials. *Pain*. 1995 Dec;**63(3)**:279-88.
13. Trescot AM, Chopra P, Abdi S, Datta S, Schultz DM. Systematic review of effectiveness and complications of adhesiolysis in the management of chronic spinal pain: an update. *Pain Physician*. 2007 Jan;**10(1)**:129-46. Review.
14. Khot A, Bowditch M, Powell J, Sharp D. The use of intradiscal steroid therapy for lumbar spinal discogenic pain: a randomized controlled trial. *Spine*. 2004 Apr 15;**29(8)**:833-6; discussion 837.

15. Rozenberg S, Dubourg G, Khalifa P, Paolozzi L, Maheu E, Ravaud P. Efficacy of epidural steroids in low back pain and sciatica. A critical appraisal by a French Task Force of randomized trials. Critical Analysis Group of the French Society for Rheumatology. *Rev Rhum Engl Ed*. 1999 Feb;**66(2)**:79-85. Review.
16. Botwin KP, Gruber RD, Bouchlas CG, Torres-Ramos FM, Sanelli JT, Freeman ED, Slaten WK, Rao S. Fluoroscopically guided lumbar transformational epidural steroid injections in degenerative lumbar stenosis: an outcome study. *Am J Phys Med Rehabil*. 2002 Dec;**81(12)**:898-905.
17. Weinstein SM, Herring SA; NASS. Lumbar epidural steroid injections. *Spine J*. 2003 May-Jun;**3(3 Suppl)**:37S-44S. Review.
18. Falco FJ. Lumbar spine injection procedures in the management of low back pain. *Occup Med*. 1998 Jan-Mar;**13(1)**:121-49. Review.
19. Runu R, Sinha NK, Pai R, Shankar PR, Vijayabhaskar P. Our experience with epidural steroid injections in management of low back pain and sciatica. *Kathmandu Univ Med J (KUMJ)*. 2005 Oct-Dec;**3(4)**:349-54
20. Ringsdal VS, Nielsen NA, Slot O, Kryger P. [Epidural glucocorticoid injection in lumbago sciatica] *Ugeskr Laeger*. 1997 Sep 15;**159(38)**:5653-7. Review. Danish.
21. McLain RF, Kapural L, Mekhail NA. Epidural steroid therapy for back and leg pain: mechanisms of action and efficacy. *Spine J*. 2005 Mar-Apr;**5(2)**:191-201. Review.
22. Cooper G, Lutz GE, Boachie-Adjei O, Lin J. Effectiveness of transforaminal epidural steroid injections in patients with degenerative lumbar scoliotic stenosis and radiculopathy. *Pain Physician*. 2004 Jul;**7(3)**:311-7.
23. Dunbar SA, Manikantan P, Philip J. Epidural infusion pressure in degenerative spinal disease before and after epidural steroid therapy. *Anesth Analg*. 2002 Feb;**94(2)**:417-20, table of contents.
24. Rivest C, Katz JN, Ferrante FM, Jamison RN. Effects of epidural steroid injection on pain due to lumbar spinal stenosis or herniated disks: a prospective study. *Arthritis Care Res*. 1998 Aug;**11(4)**:291-7.
25. Hooten WM, Mizerak A, Carns PE, Huntoon MA. Discitis after lumbar epidural corticosteroid injection: a case report and analysis of the case report literature. *Pain Med*. 2006 Jan-Feb;**7(1)**:46-51.
26. Jasper JF. Lumbar retrodiscal transforaminal injection. *Pain Physician*. 2007 May;**10(3)**:501-10.
27. Lee JW, Kim SH, Lee IS, Choi JA, Choi JY, Hong SH, Kang HS. Therapeutic effect and outcome predictors of sciatica treated using transforaminal epidural steroid injection. *AJR Am J Roentgenol*. 2006 Dec;**187(6)**:1427-31.
28. Igarashi T, Hirabayashi Y, Seo N, Saitoh K, Fukuda H, Suzuki H. Lysis of adhesions and epidural injection of steroid/local anaesthetic during epiduroscopy potentially alleviate low back and leg pain in elderly patients with lumbar spinal stenosis. *Br J Anaesth*. 2004 Aug;**93(2)**:181-7. Epub 2004 Jun 11.
29. Liu SS, Melmed AP, Klos JW, Innis CA. Prospective experience with a 20-gauge Tuohy needle for lumbar epidural steroid injections: Is confirmation with fluoroscopy necessary? *Reg Anesth Pain Med*. 2001 Mar-Apr;**26(2)**:143-6.
30. Botwin KP, Sakalkale DP. Epidural steroid injections in the treatment of symptomatic lumbar spinal stenosis associated with epidural lipomatosis. *Am J Phys Med Rehabil*. 2004 Dec;**83(12)**:92.
31. Yang SC, Fu TS, Lai PL, Niu CC, Chen LH, Chen WJ. Transforaminal epidural steroid injection for discectomy candidates: an outcome study with a minimum of two-year follow-up. *Chang Gung Med J*. 2006 Jan-Feb;**29(1)**:93-9.
32. Kraemer J, Ludwig J, Bickert U, Owczarek V, Traupe M. Lumbar epidural perineural injection: a new technique. *Eur Spine J*. 1997;**6(5)**:357-61.
33. Southern D, Lutz GE, Cooper G, Barre L. Are fluoroscopic caudal epidural steroid injections effective for managing chronic low back pain? *Pain Physician*. 2003 Apr;**6(2)**:167-72.
34. Ryderik BL, Cohen DB, Kostuik JP. Spine epidural steroids for patients with lumbar spinal stenosis. *Spine*. 1997 Oct 1;**22(19)**:2313-7. Review.