

CASE OF PORTAL VENOUS GAS SECONDARY TO PNEUMOCOCCAL PNEUMONIA DETECTED ON GRAY SCALE SONOGRAPHY BUT NOT BY COMPUTED TOMOGRAPHY

A Farhan, M Talha, M Idris

Department of Radiology, Aga Khan University Hospital, Karachi, Pakistan.

PJR Jan - Mar 2008; 18(1): 12-13

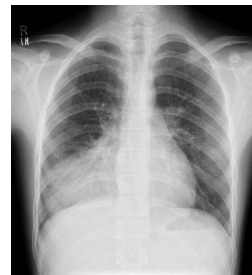Introduction

Portal venous air is a rare condition whose pathogenesis is not fully understood. It is most commonly caused by mesenteric ischemia but may have a variety of other causes. It is idiopathic in approximately 15% of cases.¹ Classically air in the portal vein has been detected by plain radiography but computed tomography and sonography have been shown to be more sensitive instruments in its detection². We report a case of PV air detected on gray scale sonography that went undetected on CT. The cause of PV air was unknown, however the patient had Pneumococcal Pneumonia.

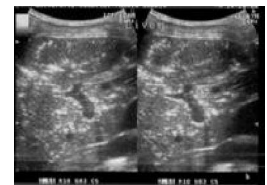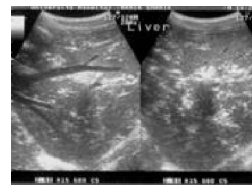Case

An 18-year-old man presented to our hospital with complaints of fever with rigors, pain in right hypochondrium and vomiting for 1 day. On examination patient was febrile with fever of 39°C, mild hepatomegaly with tenderness in right hypochondrium. Laboratory workup revealed Hb of 11mg/dl, W.B.C. of 21,000 and deranged coagulation with I.N.R. of 1.69. His chest X-ray (fig. 1) in ER showed consolidation in right lower lobe. As there was tenderness in right hypochondrium with hepatomegaly ultrasound abdomen was requested which revealed air in portal venous channels (fig. 2 & 3) and mild hepatomegaly. No focal lesion or cause for portal venous gas could be ascertained. CT was advised but it was deferred till next day as patient went into septic shock. Enhanced CT abdomen was performed after 14-hours of ultrasound which did not show the portal venous air (fig. 4) however mild hepatomegaly and right lower lobe consolidation (fig. 5) were shown well.

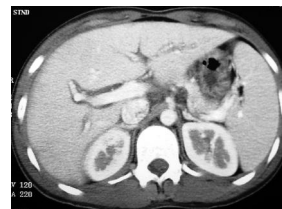
He was managed conservatively with leukocyte count falling within range in following 4 days. Final blood culture report showed growth of Streptococcus pneumoniae. Patient was discharged on oral antibiotics. On follow-up his symptoms significantly subsided.



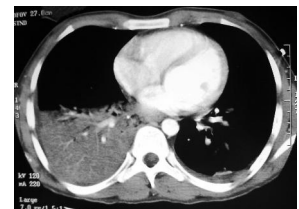(1). Chest X-ray show consolidation of right lower lung zone.



(2 & 3). Ultrasound images show densely echogenic foci within portal venous trunks and in portal radicals in liver parenchyma



(4). Enhanced CT section does not show PV air.



(5). CT section through lung bases, show consolidation of right lower lobe.

Discussion

Portal vein gas and mesenteric vein gas are rare conditions that have been associated with extensive bowel necrosis with fatal outcome. Portal vein gas was first described in children by Wolfe and Evans in 1955

Correspondence : Dr. A. Farhan
Department of Radiology,
Aga Khan University Hospital,
Stadium Road, P.O Box 3500, Karachi, 74800
Pakistan. Tel. No. 4930051- Ext 2020
E-mail: talha.zubairi@aku.edu

and in adults by Susman and Senturia in 1960.¹ The pathogenesis of gas in portal vein is thought to be bacteria traversing the intestinal wall, which is already damaged by an underlying disease and then producing gas in PV.² Because of the nature of flowing blood, the portal venous air is apt to be more transient than biliary tree air.³

The most serious and most frequent cause of portal venous air in adults is mesenteric ischemia. However, the association of portal venous air with this disease process does not imply a worse prognosis; thus, surgical treatment should not be excluded when this sign is present.¹

Other causes include inflammatory bowel disease, blunt abdominal trauma⁴, iatrogenic (after barium enema⁵, intra abdominal sepsis (eg, diverticulitis, abdominal wall gangrene, pylephlebitis, acute appendicitis⁶, liver transplantation, pneumatosis intestinalis, corticosteroid therapy. Two published case reports show PV gas association with lumbar puncture⁷, and colchicine toxicity⁸, as well. Few cases were also reported from mesenteric recurrence of ovarian cancer superinfected with clostridium septicum and sepsis with *Pseudomonas aeruginosa*.¹⁰

The greater sensitivity of sonography over plain film for portal venous air detection is well known⁹. The high acoustic impedance of air results in intensely hyperechogenic foci noted within both the lumen of the PV and the liver parenchyma when air enters the PV. The Doppler appearance of air in the PV is the consequence of an artifact. The large discontinuity of acoustic impedance between a free gas bubble and fluid plasma creates a strong echo, which is Doppler shift if the bubble is moving along the axis of the ultrasound beam.²

At CT, portal vein gas appears as tubular areas of decreased attenuation in the liver, predominantly in the left lobe. These low-attenuation areas are caused by the accumulation of gas in the intrahepatic portal veins, from where it is carried by centrifugal blood to the hepatic periphery.¹

Our patient was diagnosed as having pneumococcal pneumonia and sepsis. Presence of air in portal venous system can be attributed to pneumococcal sepsis. Time delay between ultrasound and CT exams can be accounted for non-detection of air on CT.

References

1. Sebastia et al: Portomesenteric Vein Gas: Pathologic Mechanisms, CT Findings, and Prognosis. *Radiographics*. 2000; **20**: 1213-1224.
2. Lafortune et al: Air in the portal vein sonographic and Doppler manifestations. *Radiology*. 1991; **180** (3): 667-670.
3. Gosink et al: Intrahepatic gas differential diagnosis. *AJR Am J Roentgenol*. 1981; **137** (4): 763-767.
4. Brown et al: Intravascular Gas as an Incidental Finding at US after Blunt Abdominal Trauma. *Radiology*; **210** (2): 405-408.
5. Stein et al: Portal venous air associated with barium enema. *AJR Am J Roentgenol*. 1983; **140** (6): 1171-1172.
6. San Millán Ruíz et al: A Case of Portal Venous Gas Secondary to Acute Appendicitis Detected on Gray Scale Sonography but Not Computed Tomography. *J Ultrasound Med*. 2005; **24** (3): 383-387.
7. Karaosmanoglu et al: Portal and systemic venous gas in a patient after lumbar puncture. *The British Journal of Radiology*. 2005; **78** (932): 767-769.
8. Saksena et al: Hepatic portal venous gas transient radiographic finding associated with colchicine toxicity. *The British Journal of Radiology*. 2003; **76** (911): 835-837.
9. Chezmar et al. Portal venous gas after hepatic transplantation: sonographic detection and clinical significance. *AJR Am J Roentgenol*. 1989; **153** (6): 1203-1205.
10. Walter Wiesner et al: Portal-venous gas unrelated to mesenteric ischemia. 2002; **12** (6): 1432-1437.

1. Sebastia et al: Portomesenteric Vein Gas: