

TRAUMATIC DIAPHRAGMATIC RUPTURE, A DIAGNOSTIC DILEMMA IN BLUNT ABDOMINAL TRAUMA: A CASE REPORT

Sheeza Imtiaz

Department of Radiology, Patel Hospital, Karachi, Pakistan.

PJR April - June 2016; 26(2): 147-150

ABSTRACT

Traumatic diaphragmatic rupture due to the blunt injury is an uncommon finding. This entity poses diagnostic and therapeutic challenges to the treating team. It can be overlooked if not evaluated with the fair degree of clinical suspicion. Despite the advances in diagnostic modalities, it remains a difficult diagnosis leading to missed or late presentations with increased risk of morbidity and mortality. We are presenting a case of young boy with history of trauma on highway who was found to have left diaphragmatic rupture.

Key words: Trauma; diaphragmatic rupture; Hydropneumothorax

Introduction

Blunt diaphragmatic rupture is an uncommon injury. This entity poses diagnostic and therapeutic challenges to the treating team. It can be overlooked if not evaluated with the fair degree of clinical suspicion. Despite the advances in diagnostic modalities, it remains a difficult diagnosis leading to missed or late presentations with increased risk of morbidity and mortality. Its incidence ranges between 1% and 7% of severe blunt trunk trauma cases.¹ If the diagnosis of traumatic diaphragmatic rupture (TDR) is missed, the mortality and morbidity may rise upto 50% due to visceral herniation and strangulation.²

Case Report

An 8 year old boy had a motor vehicle accident (MVA) on a highway. On arrival in the emergency room, he was unconscious, vitally unstable with breathing difficulty. His chest examination revealed reduced air entry on the left hemithorax. Ultrasound FAST examination showed free fluid at hepatorenal angle and

right kidney laceration. Routine trauma series examination was done that showed multiple fractures involving pelvic bones, left femur, 10th and 11th ribs. His initial CXR showed lung contusions and raised left hemidiaphragm. Initially, the clinician suspected it as a hydropneumothorax with raised left hemidiaphragm and chest tube was placed on the left side. The child's breathing was not improved despite of chest tube placement. After that to rule out visceral injury CT scan chest and abdomen was done. CT showed bilateral lung contusions more on left side. There was no hydropneumothorax instead the entire stomach herniated within the left thoracic cavity mimicking hydropneumothorax (Fig. 1,2). The left diaphragm was not visualized in its entire extent with few specks of air noted adjacent to the crus of left diaphragm and within left side of abdomen representing pneumoperitoneum. The radiologist raised the possibility of left diaphragmatic rupture with intrathoracic herniation of stomach (Fig. 3). To further confirm the diagnosis, small amount of non ionic contrast was given to the patient through nasogastric tube and x-ray was taken that confirmed the diagnosis of intrathoracic herniation of stomach (Fig. 4).

Correspondence : Dr. Sheeza Imtiaz
Department of Radiology,
Patel Hospital,
Karachi, Pakistan.
Email: dr.sheeza.imtiaz@gmail.com

Submitted 26 October 2015, Accepted 28 October 2015

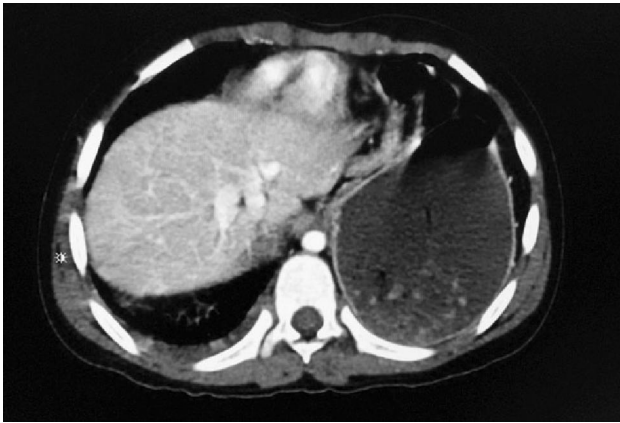

Figure 1: CT Scan chest with contrast showing intrathoracic herniation of stomach through left sided traumatic rupture of the diaphragm mimicking hydropneumothorax.

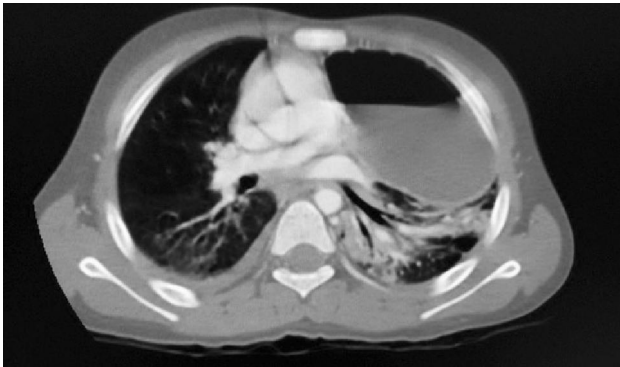


Figure 2: CT Scan chest in lung window setting showing contusions involving both lungs more on the left side.

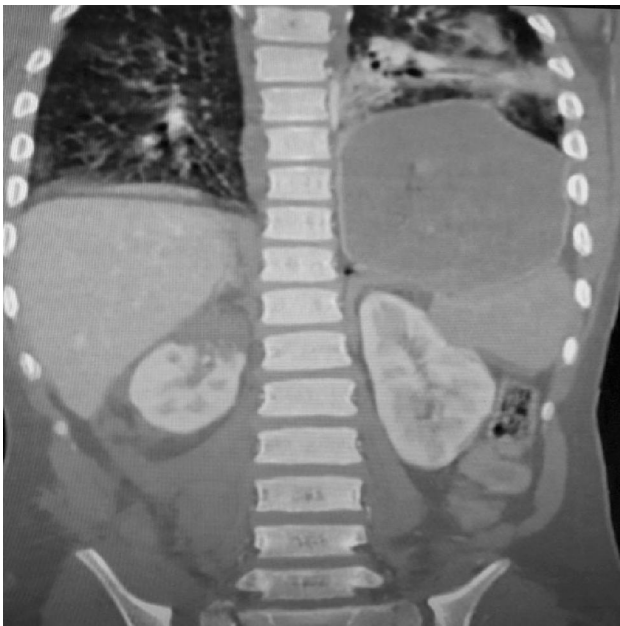

Figure 3: Coronal section of CT abdomen showing defect in the left diaphragm with a small speck of free air representing pneumoperitoneum. Intrathoracic herniation of stomach and right renal contusion also seen.

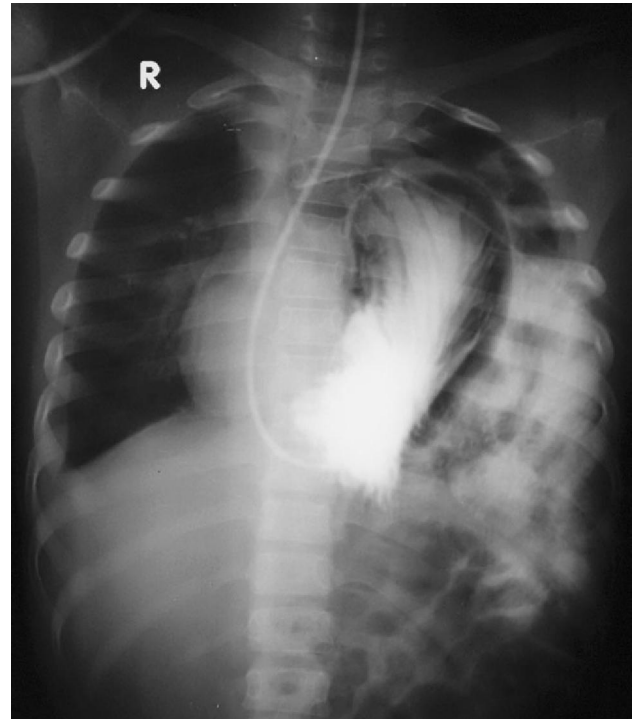


Figure 4: Fluoroscopic guided administration of water soluble contrast through nasogastric tube showing upward intrathoracic herniation of stomach with leakage of contrast on the left side confirming diaphragmatic rupture.

There was also something unusual in this case that, CT scan abdomen doesn't showed any liver and splenic laceration instead there was Grade III laceration and contusion of the right kidney (Fig. 5). Left kidney was normal. Mild amount of free fluid was present in abdominal cavity especially in paranephric region. The patient underwent an emergency exploratory laparotomy and a linear diaphragmatic tear

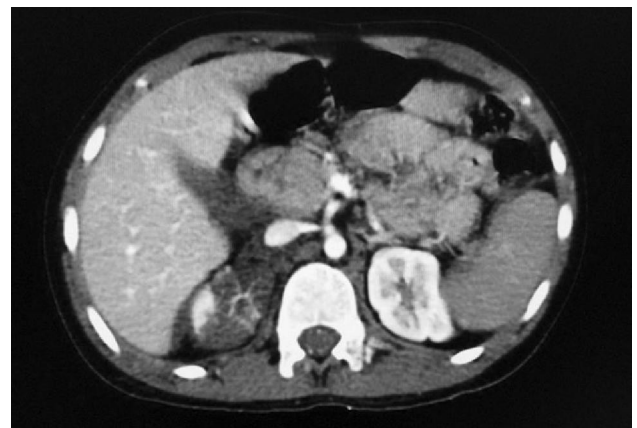

Figure 5: Grade III laceration and contusion involving right kidney. Left kidney was normal.

with herniation of abdominal viscera was seen (Fig. 6) which was repaired.

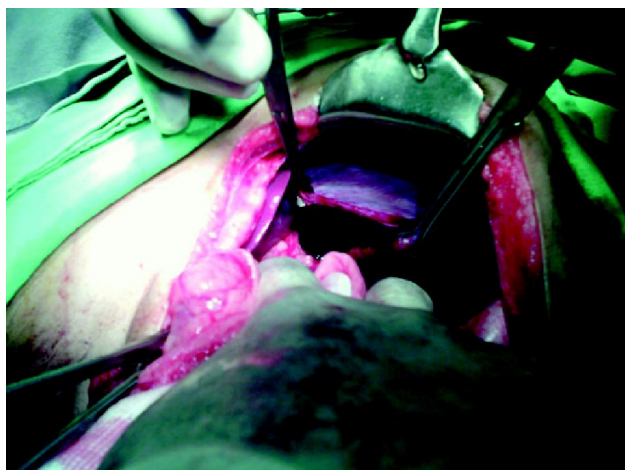


Figure 6: Per operative view of exploratory laparotomy showing linear defect in the diaphragm with herniation of abdominal viscera intrathoracically.

Discussion

Development of diaphragmatic injury in blunt trauma is relatively rare. The incidence rises to 15% in cases of penetrating trauma.¹ Over 90% of blunt diaphragmatic ruptures are caused by MVA,³ and it is reported that 1-5% of MVAs could hide a diaphragmatic ruptures.⁴ In blunt injuries, the left hemidiaphragm is involved in 70 - 80%, as in this case, the right in 15 - 24%, and bilaterally in 5 - 8%.⁵ It is reported that left side involvement is nine times higher than the right side.⁶ In pediatric population, as in this case, it is more difficult to diagnose and treat because compliance of the chest wall results in internal injuries without evident external ones. Their mediastinum is mobile and readily compromised by other intrathoracic lesions such as pneumothorax.⁷

Patients with bilateral diaphragmatic ruptures are often severely injured and have important associated injuries; chest and abdominal injuries are the most common, followed by pelvic and head injuries.^{8,9} The rates for associated injuries in blunt diaphragmatic rupture are as follows: pelvic fractures in 40%, splenic rupture in 25%, liver laceration in 25% and thoracic aortic tear in 5-10%. Diaphragmatic rupture and thoracic aortic disruption are uniquely associated in blunt trauma.¹⁰ In this case report, we observed an

unusual association of Grade III laceration and contusion involving right kidney without any hepatic and splenic laceration.

The presentation of these patients fall into three types: (1) immediate and early after trauma; (2) delayed > 48 h; and (3) delayed with obstructive symptoms. The most commonly experienced symptoms are dyspnea, chest pain, abdominal pain, and vomiting. Physical findings are not specific and this adds to the diagnostic challenge. Although a decrease in the respiratory sounds is the primary finding, bowel sounds in the thorax and the pathognomonic finding of intestinal herniation are detectable in some patients.⁶

Chest X-ray remains the initial diagnostic modality in the context of trauma. It is normal and nonspecific in 27 - 62% of the cases. It is only diagnostic in 33% of left-sided rupture compared with 18% in right-sided rupture.¹¹ Helical CT scan has sensitivity of 71%, specificity 100%, but when using the reformatted forms it increases the sensitivity.⁷ Suggested signs on CT include collar sign indicating focal constriction of viscus at the herniation site or dependent viscera signs which is reported 100% sensitivity in left-sided rupture and 83% in the right-sided rupture.¹² Other modalities such as magnetic resonance imaging, barium studies, and ultrasound or fluoroscopy are helpful in the delayed type because the acute traumatic setting requires hemodynamic stable patients to perform the study.

Recognized associated complications such as ileus (40%), pneumonia (30%), pancreatitis (20%), surgical site infection (20%), intestinal obstruction (20%), atelectasis (10%), and renal failure (6%), with hospital stay range 7 - 54 days (mean 24 days). Diaphragmatic rupture is a marker for severity of injury. Mortality in pediatric population ranges 9 - 15% compared with adults 4 - 37% with right-sided rupture contributing more of this percentage. Death occurs acutely from hypovolemic shock and later from multiorgan failure.¹³ Once diagnosed, treatment of the diaphragmatic tear is straight forward; primary repair of the defect is performed. In our view, laparotomy remains the gold standard, but there have been some case reports with successful laparoscopic repair.

Conclusion

Increased level of suspicion is essential in order to timely diagnose blunt diaphragmatic rupture in polytrauma patients. Early diagnosis can lead to the proper surgical management and reduce the incidence of complications.

References

1. David B, Amir F, Heyman L. A review diaphragmatic injury. *Resp Med J*. 2009; **2**: 1-6.
2. Gelman R, Mirvis SE, Gens D: Diaphragmatic rupture due to blunt trauma: sensitivity of plain chest radiographs. *AJR* 1991, **156**: 51-7.
3. Iochum S, Ludig T, Walter F, Sebbag H, Grosdidier G, Blum AG. Imaging of diaphragmatic injury: A diagnostic challenge? *Radiographics*. 2002; **22**: S103-16.
4. Adler DH. Blunt diaphragmatic injury in a 7-year-old girl. *J Emerg Med*. 2002; **23**: 39-42.
5. Eren S, Kantarci M, Okur A. Imaging of diaphragmatic rupture after trauma. *Clin Radiol*. 2006; **61**: 467-7.
6. Shapiro MJ, Heiberg E, Durham RM, Luchtefeld W, Mazuski JE. The unreliability of CT scans and initial chest radiographs in evaluating blunt trauma induced diaphragmatic rupture. *ClinRadiol*. 1996; **51**: 27-30.
7. Killeen KL, Mirvis SE, Shanmuganathan K. Helical CT of diaphragmatic rupture caused by blunt trauma. *AJR Am J Roentgenol*. 1999; **173**: 1611-6.
8. Thakore S, Henry J, Todd AW. Diaphragmatic rupture and the association with occupant position in right-hand drive vehicles. *Injury*. 2001; **32**: 441-4.
9. Williams M, Carlin AM, Tyburski JG, et al. Predictors of mortality in patients with traumatic diaphragmatic rupture and associated thoracic and/or abdominal injuries. *Am Surg*. 2004; **70**: 157-63.
10. Rizoli SB, Brenneman FD, Boulanger BR, Maggisano R. Blunt diaphragmatic and thoracic aortic rupture: an emerging injury complex. *Ann Thorac Surg*. Nov. 1994; **58(5)**: 1404-8.
11. Gelman R, Mirvis SE, Gens D. Diaphragmatic rupture due to blunt trauma: Sensitivity of plain chest radiographs. *AJR Am J Roentgenol*. 1991; **156**: 51-7.
12. Soundappan SV, Holland AJ, Cass DT, Farrow GB. Blunt traumatic diaphragmatic injuries in children. *Injury*. 2005; **36**: 51-4.
13. Ramos CT, Koplewitz BZ, Babyn PS, Manson PS, Ein SH. What have we learned about traumatic diaphragmatic hernias in children? *J Pediatr Surg*. 2000; **35**: 601-4.