

A CASE REPORT OF SUBPENDYMAL GIANT CELL ASTROCYTOMA IN 7 MONTH OLD PATIENT WITH TUBEROUS SCLEROSIS

Mansoor Ghani, Rashid Nazir, Atif Rana, Umar Amin, Jahangir Haleem Khan

Department of Radiology, Shifa International Hospital, Islamabad, Pakistan.

PJR January - March 2012; 22(1):23-25

ABSTRACT

Tuberous sclerosis is a neurocutaneous syndrome with a wide variety of clinical, pathologic, and radiologic manifestations. Intracranial phakomatosis has been reported to include subependymal nodules; cortical, and subependymal giant-cell astrocytomas. Subependymal giant-cell astrocytomas are rare, benign typically slow growing tumors of mixed neuroglial lineage, which can become aggressive and cause increased intracranial pressure, seizures, and focal neurologic signs. The standard treatment of these tumors is total neurosurgical resection [1,2,3]. We report a 07 month old male patient with tuberous sclerosis who underwent surgery for a large subependymal giant-cell astrocytoma (SEGA). It is rare to find SEGA in this age period.

Keywords: Subependymal giant-cell astrocytoma(SEGAs) ; Subependymal nodules (SENs): Tuberous sclerosis(TS)

Introduction

Tuberous sclerosis is an autosomal-dominant, multisystem, neurocutaneous syndrome classically characterized by the Vogt clinical triad of seizures, mental retardation, and facial adenoma sebaceum. Benign tumors occur in various organs, including the heart, kidneys, and brain. In the brain, the lesions typically manifest as cortical and subependymal hamartomas or tubers; these are areas of giant neurons, astrocytes, and areas of gliosis. Subependymal Giant cell astrocytoma is a rare, low grade tumor accounting for 1-2% of all pediatric brain tumors and occurring exclusively in patients with TS.⁴ Although histologically benign, SEGAs commonly arise in the lateral ventricles near the foramen of Monro and can result in obstructive hydrocephalus.² Historically, patients often presented with symptoms of increased intracranial pressure, and the death rate after surgery in the acute phase approached 10%. More recently, tumors have been resected in the nonacute phase to improve prognosis.⁵

Case Report

A 7 month old male patient, diagnosed case of Tuberous sclerosis, presented with complaints of seizures, feeding difficulties and vomiting. Patient underwent CT scan without contrast of brain, which showed a large 3 x 2 cm (AP x TR) well defined lobulated heterogeneous predominantly hyperdense mass lesion with specks of calcification occupying the frontal horn and anterior body of right lateral ventricle extending to foramen of monro, which was effaced, resulting in dilatation of occipital horn of lateral ventricle (Fig. 1A & 1B). Multiple small subependymal calcific nodular deposits and few hyperdense nodules in white matter were detected. Patient underwent right frontal craniotomy, and biopsy of the lesion revealed; Subependymal Giant cell Astrocytoma (WHO Grade1).

Correspondence : Dr. Mansoor Ghani
Department of Diagnostic Radiology,
Shifa International Hospital,
H-8/4, Islamabad 44000, Pakistan.
Email: Mansoor_ghani270@yahoo.com

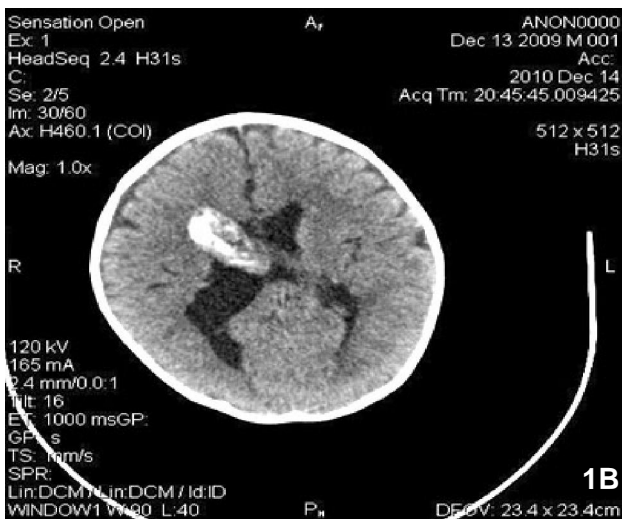
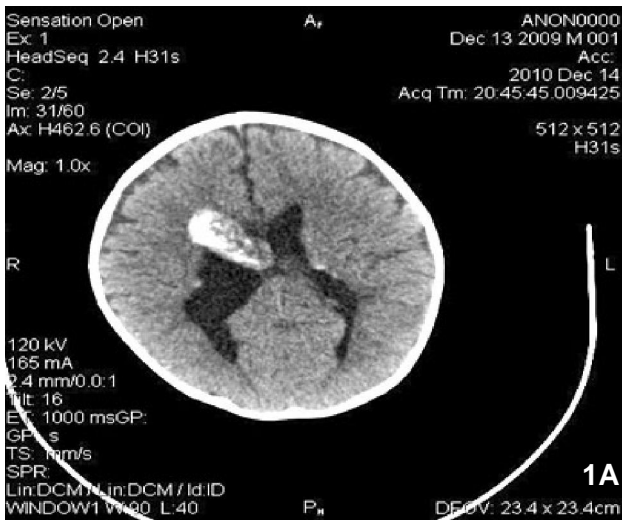


Figure 1A & B: (CT brain without contrast) Well defined lobulated heterogeneous predominantly hyperdense mass lesion with specks of calcification occupying the frontal horn and anterior body of right lateral ventricle extending to foramen of monro.

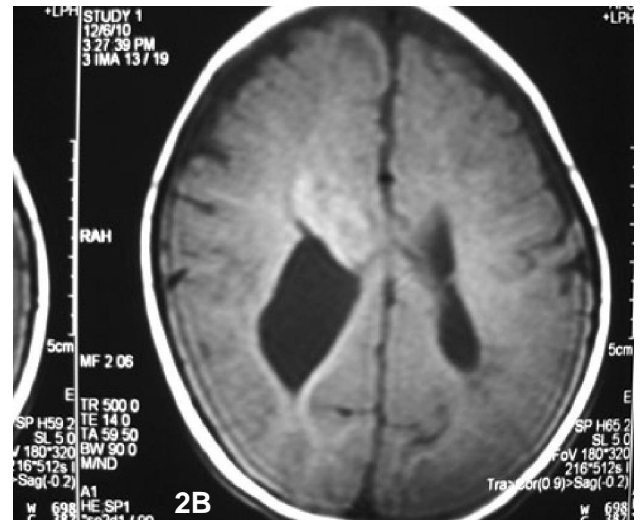
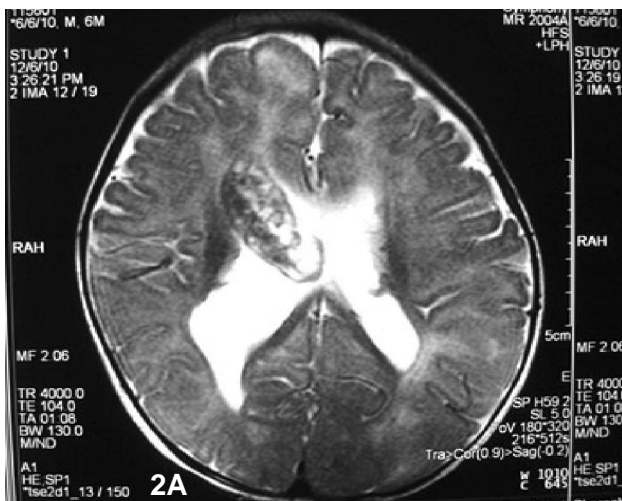


Figure 2A & B: MRI brain T2 and T1 images showing lobulated mass lesion occupying the frontal horn.

Discussion

Tuberous sclerosis is an autosomal-dominant neurocutaneous disease that originates during fetal development, and gives rise to hamartomas in multiple organ systems. In the brain, four major pathological features have been identified, as follows:

- 1) Cortical and Subcortical tubers
- 2) White matter disease
- 3) Subependymal Nodules (SENs)
- 4) SEGAs.

CT is a useful tool for detection of subependymal nodules, since they are associated with calcification far more commonly (88%) than are cortical tubers. Unenhanced CT typically depicts multiple small foci with dense calcification along the lateral ventricles bilaterally. At MR imaging, subependymal nodules are hyperintense on T1-weighted images and iso to hyperintense on T2-weighted images. Subependymal nodules tend to have lower signal intensity on T2-weighted image than do cortical tubers, probably because subependymal nodules have high water content.

SEGAs are characterized by proliferative astrocytes and giant cells, with a prevalence 5%–20% in patients with TS.⁶ The typical location of SEGAs is in the foramen of Monro, leading to obstructive hydrocephalus. Typically, the initial symptom of SEGAs is increased intracranial pressure, frequently with acute onset. Different from other cerebral astrocytomas, SEGAs have benign biologic and pathologic features

(i.e, slow growth, minimal or no attendant brain edema, and minimal invasiveness). It is widely accepted that SEGAs are derived from subependymal nodules; this is supported by the existence of intermediate cells between hamartomatous nodules and SEGAs and by serial CT studies indicating growth of nodules into SEGAs.⁷ SEGAs are typically slow growing tumor usually present in older children and adolescents, although SEGAs can evolve in utero too.⁸

7. Bongiorno L, Arroyo HA, Lubienicki F. Subependymal nodules-sudependymal giant cell astrocytoma complex in children with tuberous sclerosis. *Medicina*. 2009; **69**: 8-14.
8. Raju GP, Urion DK, Sahin M, Neonatal subependymal Giant cell astrocytoma: New case and review of literature. *Pediatr Neurol*. Feb 2007; **36(2)**: 128-31.

References

1. Darcy A, Krueger, Marguerite M, Care, Katherine Holland, Karen Agricola, Cynthia Tudor, Prajakta Mangeshkar, Kimberly A. Wilson, Anna Byars, Tarek Sahnoud, and David Neal Franz, Everolimus for Subependymal Giant-Cell Astrocytomas in Tuberous Sclerosis. *N Engl J Med* 2010; **363**: 1801-11.
2. Berhouma M (2010) Management of subependymal giant cell tumors in tuberous sclerosis complex: the neurosurgeon's perspective. *World J Pediatr* **6**: 103-10.
3. Torres OA, Roach ES, Delgado MR, Sparagana SP, Sheffield E, Swift D, Bruce D. Early diagnosis of subependymal giant cell astrocytoma in patients with tuberous sclerosis. *J Child Neurol* 1998; **13**: 173-7.
4. Jiang T, Jia G, , Luo S, Zhang Y. The diagnosis and treatment of subependymal giant cell astrocytoma combined with tuberous sclerosis. *Childs Nerv Syst*. 2011 Jan; **27**: 55-62.
5. De Ribaupierre S, Dorfmueller G, Bulteau C, Fohlen M, Pinard JM, Chiron C, Delalande O. Subependymal giant-cell astrocytomas in pediatric tuberous sclerosis disease: when should we operate? *Neurosurgery* 2007; **60**: 83-9.
6. Moavero R, Pinci M, Bombardieri R, Curatolo P. The management of subependymal giant cell tumors in tuberous sclerosis: a clinician's perspective. *Childs Nerv Syst*. Aug 2011; **27(8)**: 1203-10.