

# TRAUMATIC ABDOMINAL WALL HERNIA: A CASE REPORT

Mubarak Mohammad Yousuf, Haida Hassan, Allah Rakha Dar, Feng Yin Chai

Department of Radiology, Universiti Kebangsaan Malaysia Medical Centre, Cheras, Kuala Lumpur, Malaysia.

PJR January - March 2012; 22(1):21-22

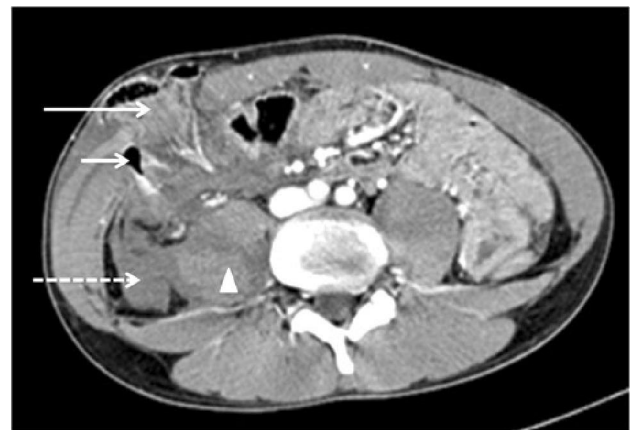## Introduction

Traumatic abdominal wall hernia occurs after blunt abdominal trauma. It is related to the sudden increase of intra abdominal pressure and shearing of the abdominal wall except the skin. Contrast enhanced Computed Tomography (CECT) is the principal imaging modality to diagnose the hernia, its content and related intra abdominal injuries.

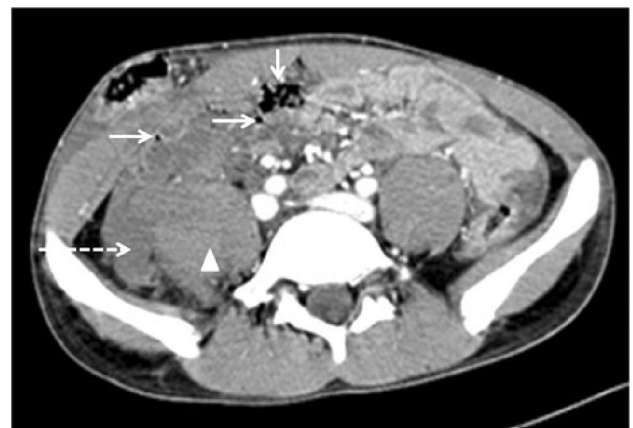
## Case Report

A 19-year-old motorcyclist was allegedly involved in a motor vehicle accident while he was traveling at 80 km/h. He skidded from his motorbike and could not recall the exact event of the accident. He was found unconscious at the site of accident and only regained consciousness in our Accident and Emergency unit. On examination, his Glasgow Coma Scale was 14/15 and he was complaining of right abdominal pain. His blood pressure was 110/70 mmHg and the pulse rate was 75 beats per minute. There were abrasions on the face and both knees. The chest, upper and lower limbs examinations were unremarkable. On the abdomen, there was a tender soft swelling at the anterior right lower quadrant measuring 5.0 cm x 4.0 cm. The overlying skin was intact and there were no bruises or wound. Contrast enhanced computed tomography scan of the abdomen was done to assess the swelling and to look for intra abdominal injury. It showed a defect at the right anterior abdominal wall with bowel loop herniation. The skin was intact. There were extra luminal air pockets adjacent to the caecum and in the pelvis. There was hematoma near the caecum and the caecal wall was thickened. The right

psoas muscle was swollen with hypodense hematoma (Fig. 1, 2). Fluid was seen in the Morison's pouch and in the pelvis. The liver, spleen, pancreas and both kidneys were normal.



**Figure 1:** CECT showed right anterior abdominal wall defect with hernia (long arrow), air-pockets due to extra luminal gas (short arrow), haemoperitoneum (dashed arrow) and rectus muscle hematoma (arrow head).



**Figure 2:** CECT image at the level of the iliac crest showed pneumoperitoneum (arrows) in the pelvis, haemoperitoneum (dashed arrow) and rectus muscle hematoma (arrow head).

**Correspondence :** Dr. Mubarak Mohammad Yousuf  
Department of Radiology, Universiti Kebangsaan  
Malaysia Medical Centre, Jalan Yaacob Latiff,  
Bandar Tun Razak, 56000 Cheras, Kuala Lumpur,  
Malaysia.  
Email: adibawazif@yahoo.com

The patient had acute traumatic anterior abdominal wall hernia with pneumoperitoneum, haemoperitoneum and right psoas muscle injury. He underwent exploratory laparotomy and was found to have 200 mls haemoperitoneum. There was perforation and contusion of the caecum and herniation of bowel loop. He had right hemi colectomy and repair of the abdominal wall and right psoas muscle.

## Discussion

Traumatic abdominal wall hernia (TAWH) is a rare clinical situation with the prevalence of 0.2% to 1.0%.<sup>1-3</sup> The hernia is preceded by blunt abdominal trauma usually after a road traffic accident or falls from a height.<sup>4</sup> The injury can be missed because it may not be evident on physical examination and more attention is given to the associated intra abdominal injuries.<sup>3</sup>

TAWH tend to occur in relatively weak anatomical sites. The sites are the lumbar triangles<sup>5</sup> and lower quadrants of the anterior abdomen usually the inguinal region and the area lateral to the rectus muscle.<sup>6</sup> The latter is commonly involved because the posterior layer of the rectus sheath is absent inferior to the arcuate line.<sup>3,7</sup> There is no association between the location of the defect and the actual site of impact.<sup>5,8</sup> In this case, apart from the abdominal swelling there was no other injury of the abdominal wall, hence the site of impact could not be certain.

The prime feature of TAWH is the skin remains intact and there should be no pre-existing hernia at the affected site prior to the trauma.<sup>3</sup> The elastic quality of the skin can overcome the sudden surge of the intra abdominal pressure from blunt trauma.<sup>6,9</sup> TAWH has been classified according to the mechanism of injury and size of the defect. Type I involves a small defect due to impact against blunt objects (often referred as handle bar hernia) and association with intra abdominal injury is rare. Type II is a larger defect occurring during motor-vehicle accident or fall from a height. Type III is intra abdominal bowel herniation following deceleration injuries.<sup>10</sup> This reported case belongs to type III and he had bowel perforation and required laparotomy.

CECT of the abdomen is the modality of choice to diagnose TAWH. It allows the assessment of the abdominal wall injury, hernia and its content, and the

detection of associated intra abdominal injuries.<sup>2,3,5</sup> Intra abdominal injuries have been found in 30% to 60% of TAWH.<sup>2,8</sup> In our case, CT is helpful to identify the hernia, psoas muscle injury, haemoperitoneum and minimal pneumoperitoneum.

## References

1. McBeth PB, Widder S, McColl RJ, Graham A, Kirkpatrick AW. Traumatic abdominal hernia with presternal herniation. *Can J Surg* 2009;**52(5)**: 207-8.
2. McDaniel E, Stawicki SP, Bahner DP. Blunt traumatic abdominal wall disruption with evisceration. *Int J Crit Illn Inj Sci* 2011;**1**:164-6.
3. Gupta S, Dalal U, Sharma R, Dalal A, Attri AK. Traumatic abdominal wall hernia. *Ulus Travma Acil Cerrahi Derg* 201;**17(6)**:493-6.
4. Den Hartog D, Tuinebreijer WE, Oprel PP, Patka P. Acute traumatic abdominal wall hernia. *Hernia* 201;**15(4)**:443-5.
5. Aguirre DA, Santosa AC, Casola G, Sirlin CB. Abdominal wall hernias: imaging features, complications, and diagnostic pitfalls at multi-detector row CT. *RadioGraphics* 2005; **25**:1501-20.
6. Van Bommel AJ, van Marle AG, Schlejen PM, Schmitz RF. Handlebar hernia: a case report and literature review on traumatic abdominal wall hernia in children. *Hernia* 2011;**15(4)**:439-42.
7. Ajisaka H, Okura S, Wakasugi M. Traumatic Abdominal Wall Hernia: A Case Report of High-Energy Type without Surgical Repair. *Clin Med Insights Case Rep.* 2011;**4**:35-8.
8. Singh R, Kaushik R, Attri AK. Traumatic abdominal wall hernia. *Yonsei Med J* 2004;**45**:552-4.
9. Hassan KA, Elsharawy MA, Moghazy K, AlQurain A. Handlebar hernia: A rare type of abdominal wall hernia. *Saudi J Gastroenterol* 2008;**14**:33-5.
10. Wood RJ, Ney AL, Bubrick MP. Traumatic abdominal hernia: a case report and review of the literature. *Am Surg.* 1988;**54**:648-51.