

## GIANT CELL TUMOR : RARE SITES

Zaheda Khatoon, Rukhsana Tariq, Shahzad Babar Kureshi, Rashid Ahmed

Advanced Radiology Clinic (Pvt.) Ltd., Karachi, Pakistan.

PJR January - March 2012; 22(1):13-17

### ABSTRACT

Giant cell tumor ( GCT) is a primary benign neoplasm of bone. It accounts for 5% of all skeletal tumors. It usually originate from long bones. We report three cases of GCT arising from rare locations. Two lesions were seen involving the tarsal bones of foot including the talus and calcaneum. The third case originated from an extremely rare site i.e. sternum. Tumor from calcaneum presented with pain and swelling in right heel. Physical examination revealed swelling of tendoachilles and calcaneum. On plain radiography there was expansile lytic lesion of calcaneum. Contrast enhanced MRI demonstrated expansile, erosive, locally aggressive mass lesion of calcaneus with exophytic extension. The mass demonstrated iso-intensity on T1WI, heterogenous hyperintensity was seen on T2WI with non homogenous enhancement on post contrast examination. The tumor was resected and histological features were consistent with Giant cell tumor. The other case involving the talus presented with pain in left ankle joint. Plain radiograph and MRI scan showed a lytic, solid cum cystic mass lesion involving the body ,neck and tail of the talus bone. Enbloc resection with total talectomy and arthrodesis with cementing was done. The third case involved sternum which is an extremely rare location for GCT. This was a 48 years old female who presented with a history of pain in midline upper chest and cough. On examination a firm mass was present on anterior chest wall in the region of manubrium sterni. On computed tomography (C.T) an expansile lytic mass was seen in the sternum. Fine needle aspiration cytology was done and histopathology was consistent with Malignant Giant Cell Tumor.

### Introduction

Giant Cell Tumor is a locally aggressive primary bone tumor with features of local recurrence and has potential to metastasize as well as malignant transformation.<sup>1,2</sup> It usually arises in the metaphyseal- epiphyseal area of the long bone. It is usually seen in the third and fourth decade with a slight female preponderance.<sup>3</sup> About 50% of cases originate around the knee.<sup>1,4</sup> The GCT of small bones of hands and feet and axial skeleton including vertebral bodies, ribs, sacrum and sternum are rare sites.<sup>1,3</sup> We report three cases of GCT at rare sites. Two of them involved the tarsal bones of foot, one arising from the talus and the other from the calcaneum. The third one involved the sternum.

**Correspondence** : Dr. Rashid Ahmed  
Advanced Radiology Clinic (Pvt.) Ltd.  
Karachi, Pakistan.  
UAN: 111-111-(ARC) 272  
Email: arcra@cyber.net.pk

### Case Report 1

A 20 years old male presented to our clinic with a complaint of pain and swelling of insidious onset in right heel for about 2 months duration. Physical examination revealed a tender, posterior bony hard swelling of tendoachilles and calcaneum. Plain radiograph of foot showed an expansile lytic lesion involving the body of the calcaneum with an intact superior articular surface. Laboratory studies including ESR, TLC & CRP were within normal limits. Three phase skeletal scintigraphy revealed increased tracer uptake over right calcaneum.

Contrast enhanced MRI, demonstrated an expansile, erosive and destructive mass lesion with exophytic extension and involvement of the soft tissues of the ankle joint on its postero-superior aspect. Cortical erosion of the lateral aspect of the calcaneum was

also associated with extension into subjacent soft tissues. The mass measured 3.8 x 4.8 x 4.0cms. The mass demonstrated isointensity on T1W, heterogenous hyperintensity on T2W images. Non-homogeneous enhancement with central necrosis was seen on MRI. (Fig.1A-1D) The patient underwent surgery. The tumor was resected and histological features were consistent with GCT. A follow up till 5 months after surgery was uneventful.

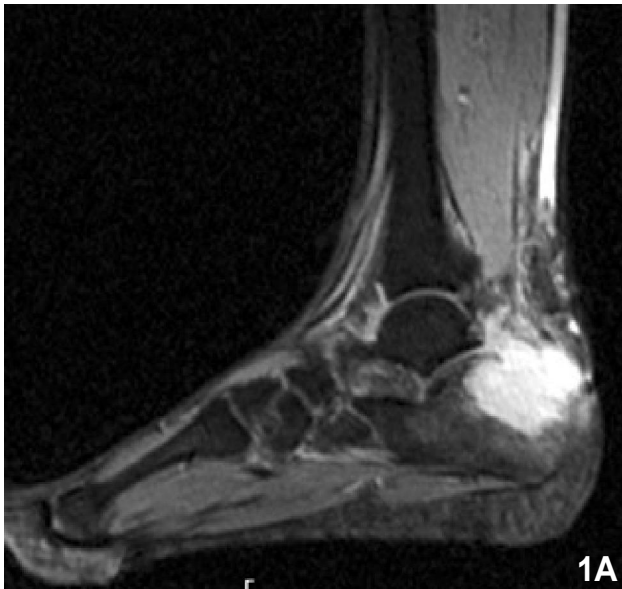


Figure 1A: Sagittal STIR image

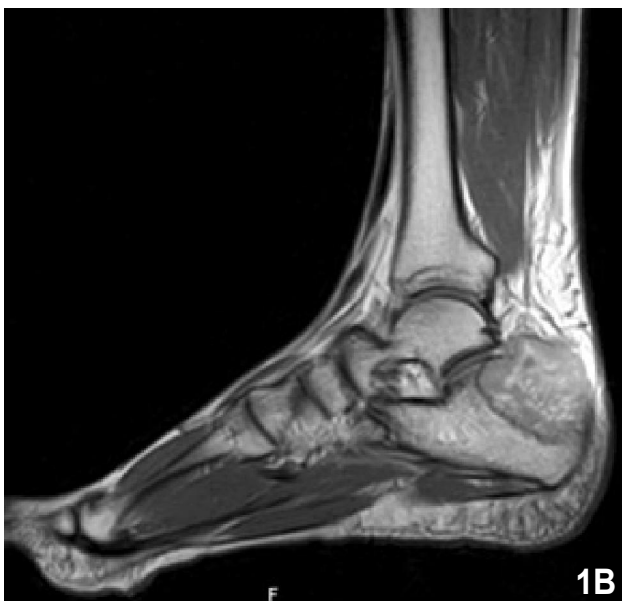

Figure 1B: Post contrast sagittal image

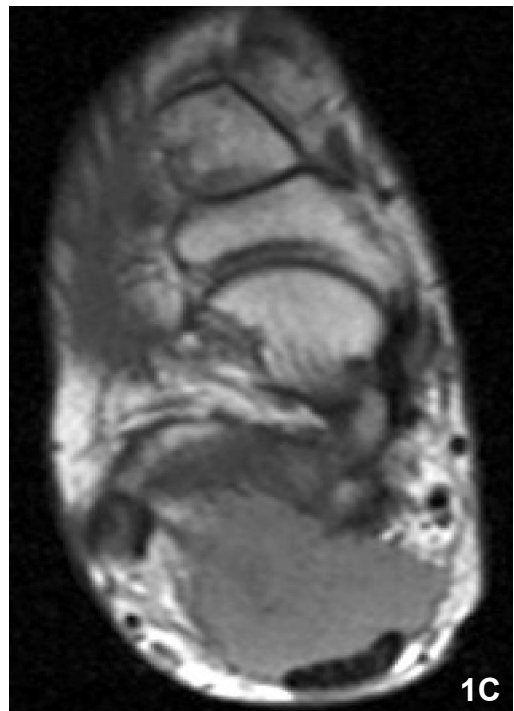


Figure 1C: T1W axial image

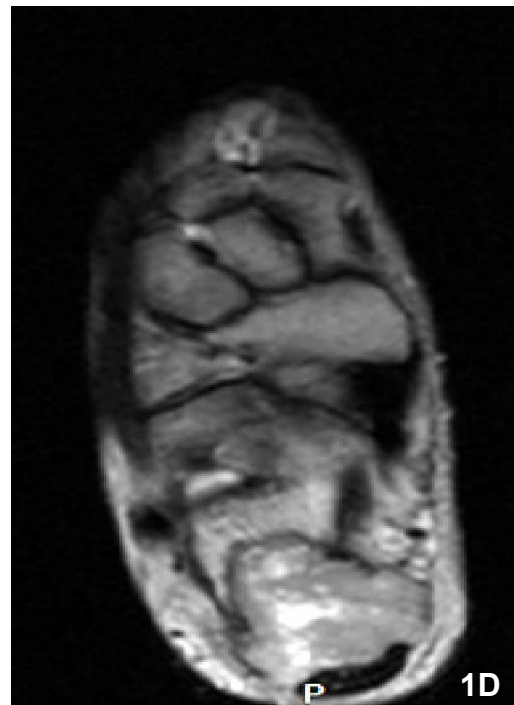

Figure 1D: T2W axial image

Figure 1(A,B,C,D): MR images of right foot of a 20 years old patient demonstrating an expansile, erosive and destructive mass lesion within calcaneum with exophytic extension and involvement of the soft tissues of the ankle joint on its postero-superior aspect.

## Case Report 2

A 38 years old male presented with pain in the left ankle joint since 1 year. The pain aggravated with walking and movements. There was no history of fever, weight loss or generalized weakness. On physical examination, there was a small, hard, tender swelling in the left ankle joint postero-laterally. Plain radiograph of foot demonstrated a radiolucent lytic lesion involving the body, neck and tail of the talus with expansion and thinning of the cortex. Laboratory studies including ESR, TLC & CRP were within normal limits. Three phase skeletal scintigraphy revealed increased tracer uptake in talus bone of left foot. Contrast enhanced MRI done from our clinic showed a bubbly, lytic, solid cum cystic mass lesion with multiple trabeculations involving the body, neck and tail of the talus. It demonstrated signal heterogeneity with predominantly intermediate to low signals on T1WI, heterogeneous hyperintensity on T2W and STIR images with enhancement of the solid components of the mass on post contrast examination. The mass measured 4.8 x 2.8 cms (Fig.2A-2D). Local extension of the mass with involvement of the flexor hallucis longus muscle and tendon sheath, the interosseous talo-calcaneal ligament and the talofibular ligament and capsule was seen. Biopsy of the lesion was done which showed Giant cell tumor or Chondroblastoma. Enbloc resection with total talectomy and arthrodesis with cement was done. Histopathology confirmed the mass to be GCT. Patient came 8 months after surgery with complaint of pain at the surgical site with a non-healing of ulcer, however there was no recurrence.

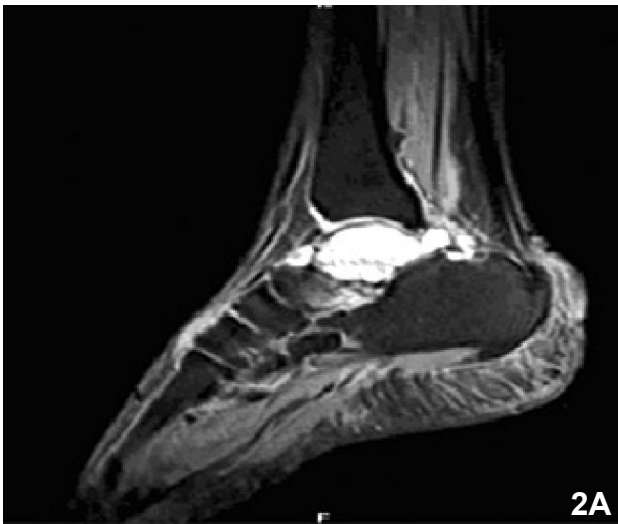


Figure 2A: Sagittal STIR image

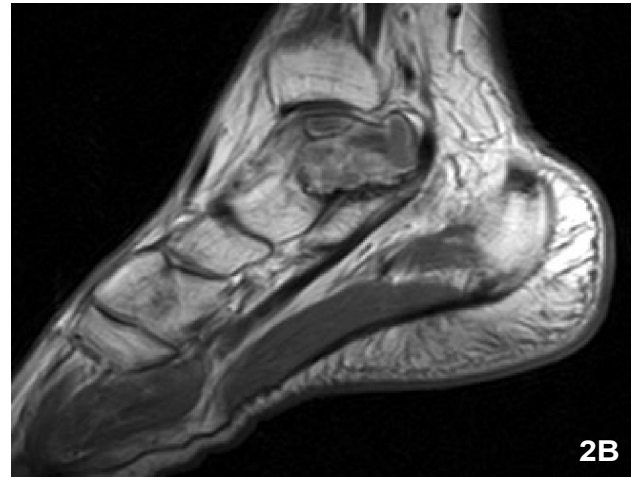


Figure 2B: Post contrast Sagittal image

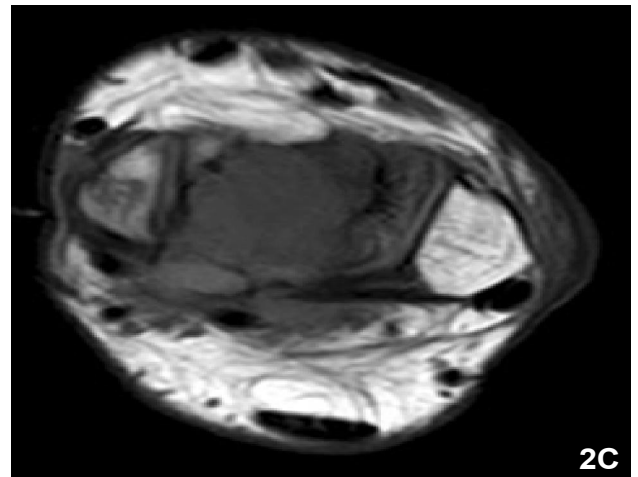


Figure 2C: T1W axial image

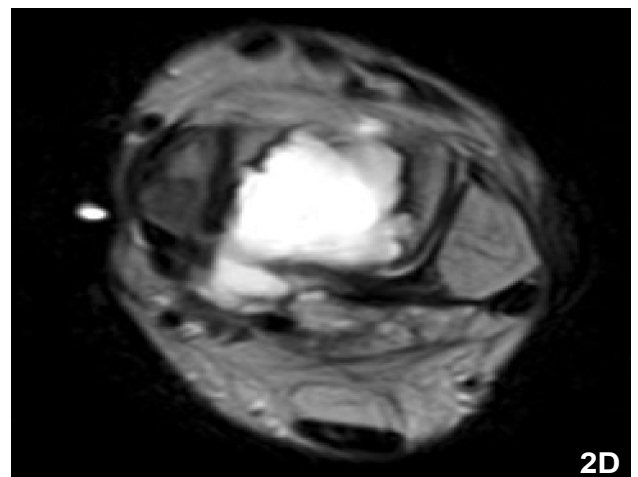
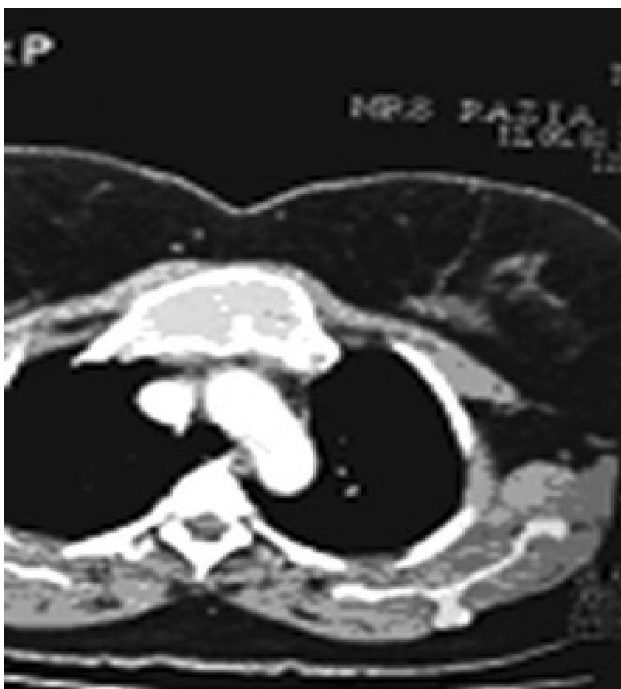


Figure 2D: T2W axial image

Figure 2(A,B,C,D): MR images of right foot of a 38 years old patient, demonstrating lytic, multicystic, solid cum cystic mass lesion with multiple trabeculations involving the Talus. Signal heterogeneity on T1W and T2WI with predominantly intermediate to low signals on T1W, heterogenous hyper intensity is seen on T2W and STIR images with enhancement of solid components of the mass on post contrast examination.

## Case Report 3

A 48 year old female presented to our clinic with a history of pain in the midline of upper chest and cough since 01 year. On examination, a firm, fixed non tender mass of about 4.0 x 3.0 cms was seen in the midline of the chest involving the sternum. Overlying skin was normal. Computed tomography (CT) scan demonstrated an enhancing, expansile, lytic, destructive mass lesion involving the body of the sternum. (Fig.3) Fine needle aspiration was done and histo-pathology was consistent with Malignant GCT of the sternum. The patient was referred for surgery and further management.



**Figure 3:** Axial C.T scan chest demonstrating an enhancing, expansile lytic lesion of the sternum. No cortical disruption is seen. No extension into the soft tissues is seen.

## Discussion

GCT, also known as osteoclastoma is a relatively common, benign neoplasm constituting 5% of all primary bone tumors.<sup>2</sup> It consists of connective tissue, multinucleated osteoclastic giant cells and a fibrous stroma. It usually occurs de novo but may also occur as a rare complication of Paget's disease of the bone.<sup>2,3</sup> GCT predominantly occurs in mature skeleton with a peak incidence in third decade of life and slightly more common in female.<sup>1,3</sup> About 50% are located around

the knee. Common sites include distal femur, proximal tibia and distal radius. Although it can occur at all skeletal sites.<sup>4</sup> It arises mainly in metaphyses of long bones and extends into epiphyses and can involve the joint.<sup>3,4</sup>

The small bones of hands and feet and axial skeleton including vertebral bodies, sacrum, ribs and sternum are rare sites for GCT.<sup>1</sup> Mirra et al report an incidence of less than 2% in the foot and Huvos reports an incidence of 1.8% in the foot.<sup>5</sup> The sternum is less commonly affected by bone neoplasms. Malignant tumors such as chondrosarcoma, osteosarcoma, multiple myeloma and lymphoma can involve the sternum but GCT is extremely rare.<sup>6,7,8</sup> Study conducted in Mayo Clinic by Futani et al. showed only 2 cases of sternal GCT out of 568 GCT cases accounting for 0.3% involving.<sup>9</sup> The average age of the patients with sternal GCT tends to be higher than that of patients with other GCT's.<sup>8</sup> This was also seen in our case.

Solitary GCT in the foot occurs more in the tarsal bones. GCT of foot usually occur in a slightly younger age group<sup>1,2</sup> and are more aggressive than those of long bones. It is important to exclude other conditions which can present with similar clinico-radiological and histological features. Hyperparathyroidism (brown tumor) with multiple lytic lesions is an important differential. The other differentials include Giant Cell Reparative granuloma,<sup>1</sup> Fibrosarcoma, Paget's disease, Metastasis, Osteosarcoma, Multiple myeloma and multifocal infection.<sup>2</sup>

The clinical presentation of GCT is insidious onset of pain and swelling at the affected site. This non-specific symptom in many cases may be mismanaged as infection or as chronic sprain.<sup>4,8</sup> A history of preceding minor trauma is infrequent. Early detection of tumor is important to avoid amputation. The local aggressiveness of the lesions warrants proper diagnosis and demonstration of extension of the lesion for surgical planning and further management. In spite of their benign nature, GCT's have shown local recurrence in 20-40% and pulmonary metastasis in 2%.<sup>6</sup>

Radiologically the lesions mainly involves the long bones. They are eccentric, osteolytic, trabeculated and slightly expansile. The lesions involve the metaphysis and diaphysis but may also extend to involve the epiphysis and subchondral bone and invade the joint. Sclerotic rim or reactive bone formation is usually absent.<sup>1,7</sup> Pathological fractures may also be seen.

CT scan permits delineation of the tumor extent. MRI is sensitive for the detection of soft tissue involvement, intraarticular extension and marrow changes. MRI is the excellent modality for assessment of subchondral breakthrough and extension of tumor into an adjacent joint. Local extension into soft tissues were seen in both tarsal bones in our study. The diagnostic accuracy of MRI is high when interpreted in conjunction with plain radiograph.<sup>4</sup> Bone scans are usually less useful than other examinations.

Therapeutic options include intralesional curettage and bone grafting. Sternal tumor should be treated with partial sternectomy depending upon the extent of involvement, to protect the lungs, heart and main vessels while preserving functional thoracic movement to prevent paradoxical respiration.<sup>6</sup>

Recurrence of the tumor as a result of curettage has a high probability. Polymethylmethacrylate (bone cement), Cryotherapy and phenol can be used as an adjuvant to curettage to prevent recurrence.<sup>6,8</sup>

Talar lesions require partial or total talectomy with arthrodesis. Arthrodesis is essential after resection of all tarsal bones except calcaneum.<sup>7,10</sup> Limb salvage and amputation is reserved for recurrences only.<sup>1,7</sup> Radiation therapy is considered for inoperable cases but it has no role in the treatment of completely resected tumors.<sup>8</sup>

## Conclusion

Rare sites of GCT may be diagnosed wrongly and mismanaged. Early and proper diagnosis of tumor clinically and radiologically can lead to proper management. Early diagnosis especially in cases of foot involvement can prevent limb amputation which can lead to disability. Due to the risk of local recurrence and pulmonary metastasis, the follow up of patients including radiological imaging of the involved area and the lungs is important.

## References

1. Varshney A, Rao H, Sadh R. Multicentric GCT of Tarsal Bones in an Immature Skeleton: A case report with Review of Literature. *The Journal of Foot & Ankle Surgery* 2010; **49**: 399.e1-399.e4.
2. Dhillon M S, Prabhudev Prasad AP, Virk MS, et al, Multicentric giant cell tumor involving the same foot: A case report and review of literature. *Indian J Orthop* 2007; **41**: 154-7.
3. Mechlin M B, MD, Kricun ME, Stead J, MD, et al, Giant Cell Tumor of Tarsal Bones. Report of three cases and review of the literature. *Skeletal Radiol*(1984) **11**: 266-70.
4. Goh LA, FRCR; Chew F S, MD. Giant cell Tumor imaging. *Emedicine.medscape.com/article/389833-overview*.
5. Biscaglia R, MD, Bacchini P MD, Bertoni F MD, Giant cell tumor of the Bones of the Hand and Foot.
6. Faria R A, Silva C M D, Miziara J E A, Giant cell tumor of the sternum. *J. bras. Pneumol.* July/August 2010; **4(36)**: Sao Paulo.
7. Sharma S, Wani I H, Gupta N, et al, Giant cell tumor of talus: a case report. *Cases Journal* 2009; **2**: 74.
8. Abate E. MD, Banki F. MD, Hagen. MD, et al, Giant cell tumor of the Sternum. *Ann Thorac Surg* 2009; **88**: 645-7.
9. Futani H, Okumura Y, Fukuda Y. Giant cell tumor of the sternum: a case report and review of the literature. *Pub Med. Anticancer Res.* 2008 Nov-Dec; **28(6B)**: 4117-20.
10. Kumar M J, Gowda N. Giant Cell Tumor of Talus: A Case report of late presentation with extensive involvement. *FAOJ Editors.* Jan; **(1)**: 2011.