

# MIDDLE FOSSA ARACHNOID CYST (MFAC) RUPTURE AND SUBDURAL HYGROMA

Sabahat Ather, Rukhsana Tariq, Rashid Ahmed

Advanced Radiology Clinic (Pvt.) Ltd., Karachi, Pakistan.

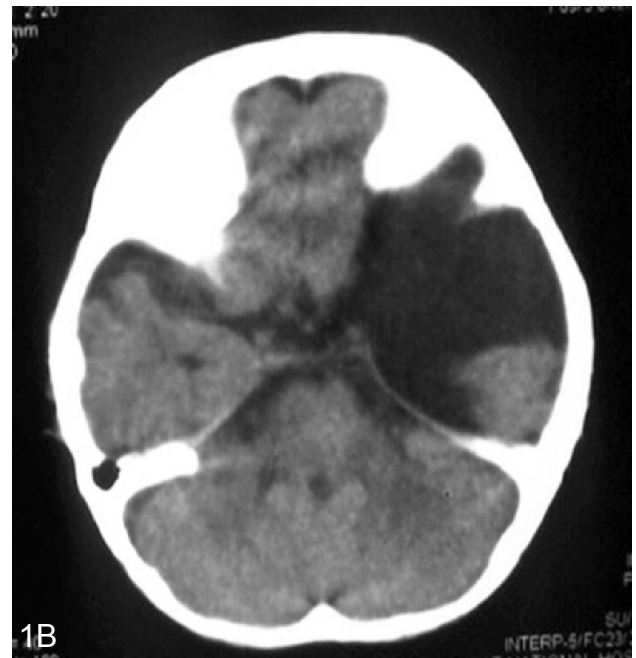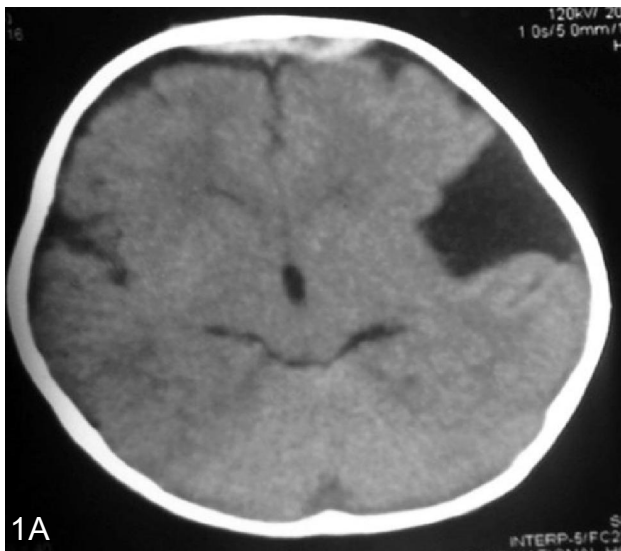
PJR April - June 2016; 26(2): 117-120

## ABSTRACT

Arachnoid cysts are congenital, CSF filled intracranial lesions. These are incidental on routine brain imaging. However, they may present with spontaneous or post traumatic rupture associated with subdural hygroma, hematoma or intracystic hemorrhage. We describe a case of a child referred for CT brain who presented at our institute with status post trauma and demonstrated left middle fossa arachnoid cyst rupture and subsequent development of subdural hygroma.

## Case Report

We received a 9-month old baby boy in our facility with a request for a follow-up CT scan brain. The patient had a history of trauma as he fell down from a flight of stairs. No history of loss of consciousness at the time of trauma or focal neurological abnormality was reported. The child presented to us with a previous CT brain done outside our institute (Fig. 1A & 1B). It demonstrated subdural subcentimeter hema-



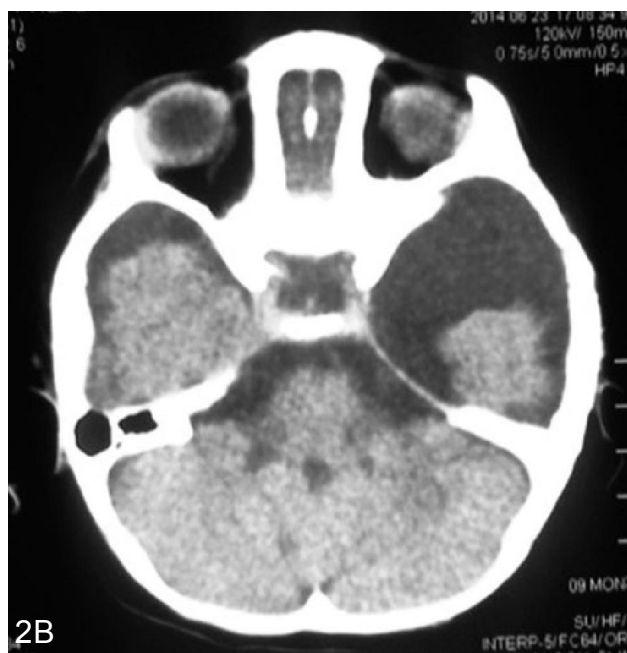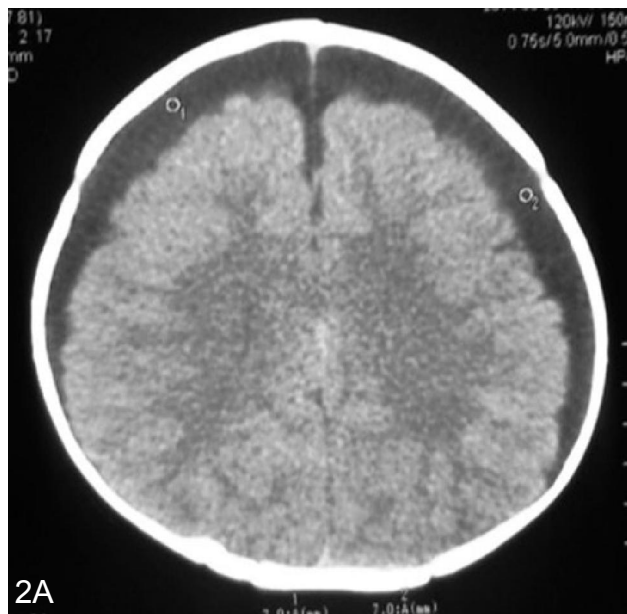
**Figure 1A:** Baseline CT BRAIN demonstrating bifrontal subdural hematomas. **1B:** Left middle cranial fossa arachnoid cyst.

tomas in bilateral frontal region. A large arachnoid cyst was demonstrated in left middle cranial fossa measuring more than 5.0 cm in diameter. The patient was treated conservatively and advised a follow up CT scan.

**Correspondence :** Dr. Rashid Ahmed  
Advanced Radiology Clinic (Pvt.) Ltd.  
Karachi, Pakistan.  
Tel: 111-111-272  
Email: arcra@cyber.net.pk

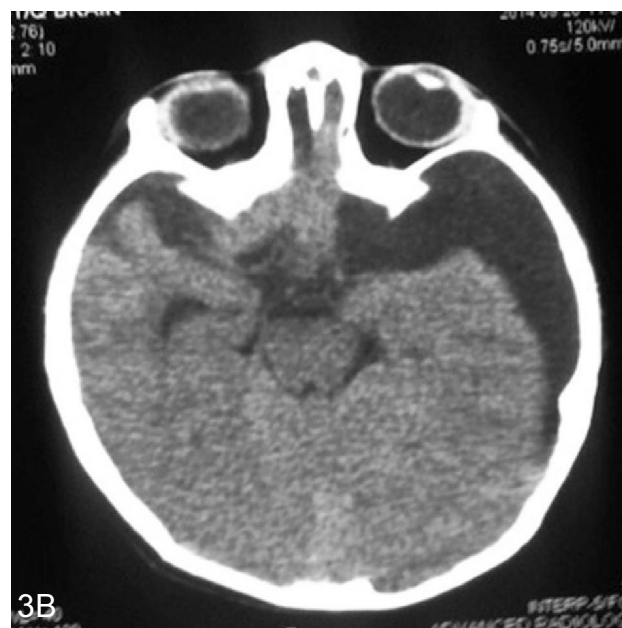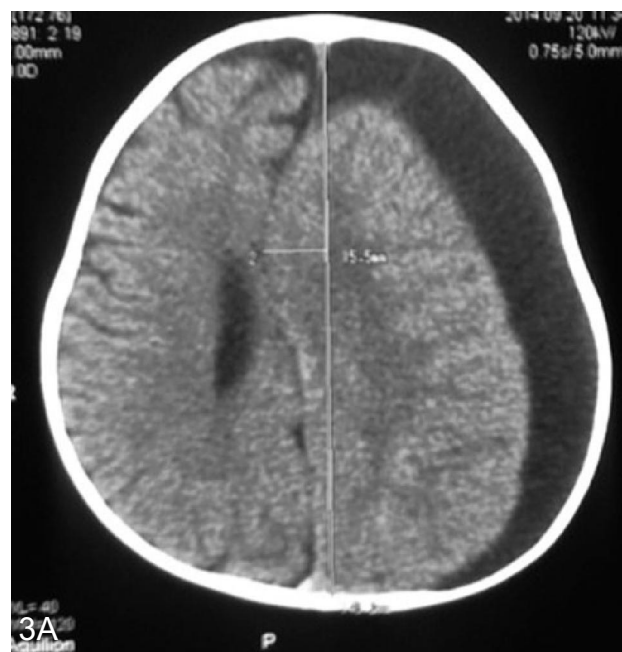
Submitted 17 August 2015, Accepted 3 November 2015

A follow-up CT scan was performed 2 weeks after the trauma demonstrated bilateral frontoparietal subdural hygromas with a maximum width of 1.0 cm on the right and 1.2 cm on the left. The left middle cranial fossa cyst was redemonstrated and was stable in size. There was no midline shift and no pressure over the cerebral hemispheres (Fig. 2A & B). Three weeks post trauma the baby underwent tapping of right sided subdural hygroma.



**Figure 2A:** Bilateral subdural hygromas with resolution of extradural hematomas. **2B:** Left middle cranial fossa arachnoid cyst.

The baby again presented to the clinic 15 weeks post trauma for a follow-up CT scan. The right sided subdural hygroma had resolved on CT. However, there was persistent and progressively enlarging left sided subdural hygroma with a maximum axial diameter of 2.5 cms. There was significant pressure over the left cerebral hemisphere and midline shift to the right of 1.5 cms. (Fig. 3 A & B). Considering the



**Figure 3A:** CT brain demonstrated persistent and progressive left sided subdural hygroma. **3B:** Left middle cranial fossa arachnoid cyst.

patient's history and clinical progression, it was concluded that this left sided subdural hygroma had developed as a result of rupture of left middle fossa arachnoid cyst. The baby was asymptomatic at this time without any neurological signs or symptoms. Patient underwent a second procedure of tapping of left sided subdural hygroma after the 3<sup>rd</sup> CT scan examination.

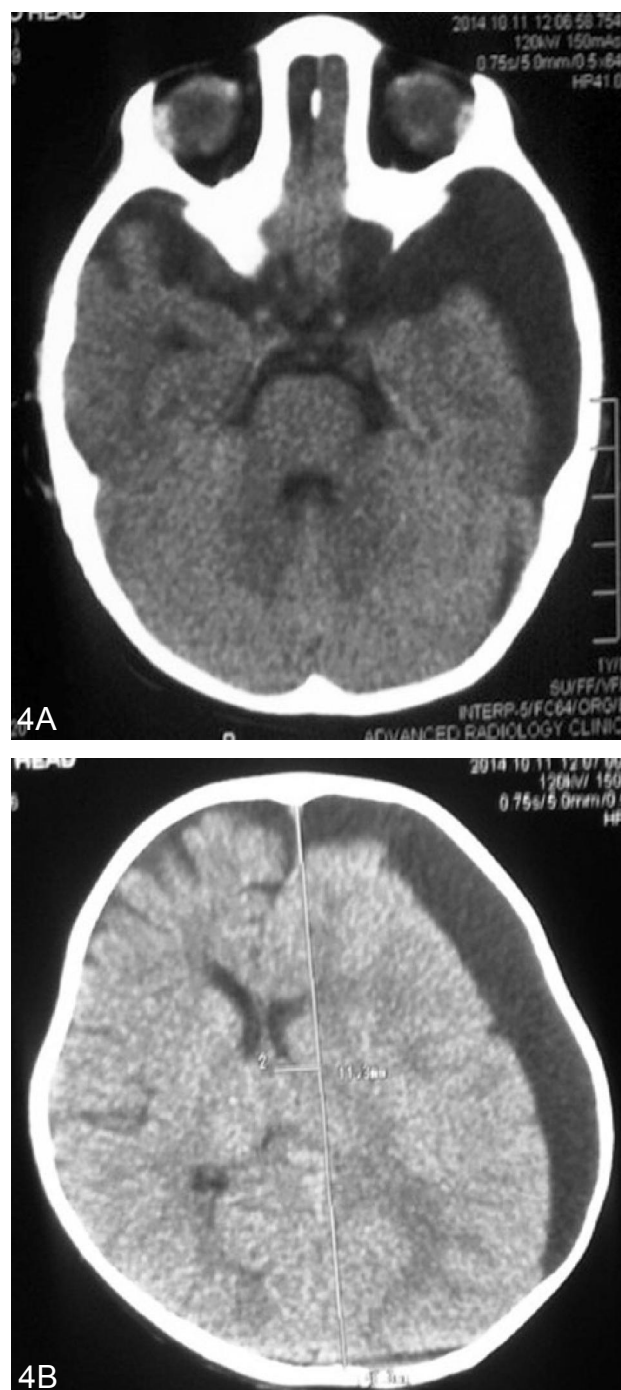
Another follow-up CT scan 3 weeks after 2<sup>nd</sup> tapping procedure was performed. It demonstrated a left sided subdural hygroma with its maximum axial width of 2.2 cms and this had minimally decreased. Midline shift to the right of 1.1 cms was seen (Fig. 4 A & B). 6 months follow-up scan also demonstrated similar features with no significant change. The baby was then planned to go through a burr hole craniotomy. The baby was then lost to follow-up.

## Discussion

Arachnoid cysts make up about 1% of intracranial mass lesions. Though they are usually an incidental finding requiring no intervention; a small subset have been found to rupture either spontaneously or in association with trauma.<sup>1</sup> A more unusual complication is the rupture of arachnoid cyst into the subdural space resulting in subdural hygroma.<sup>2</sup> Review of literature suggests that middle fossa arachnoid cysts are more prone to rupture and more commonly associated with subdural hygromas compared to the arachnoid cysts in other locations.

Middle cranial fossa arachnoid cyst are more prone to rupture<sup>1</sup> because it has been hypothesized that middle fossa lesions are more exposed to potential tearing motions along the lateral dural surface.<sup>3</sup> The bleeding point was probably caused by disruption of cortical vein that frequently traverse the cyst.

Large sized arachnoid cyst and recent head trauma are risk factors for arachnoid cyst rupture. A 5 cm cut-off value was suggested.<sup>4</sup> Both these factors were present in our patient. It has been suggested that due to trauma, outer cyst membrane tears and hence leads to the formation of subdural hygroma.<sup>1</sup> Another possible mechanism is the formation of communication between the cyst and the suba-



**Figure 4A:** Redemonstration of left middle cranial fossa arachnoid cyst. **4B:** Minimal decrease in size of left sided subdural hygroma and mass effect.

chmoid space post trauma with a ball valve mechanism so that the CSF flows from the subarachnoid space into the cyst leading to increase in intracystic pressure and eventual rupture of the cyst and formation of subdural hygroma.<sup>5</sup>

Arachnoid cyst rupture with concurrent subdural hygroma had a predilection for left side and male sex. This has also been reported in the literature. Both these factors were again present in our patient.<sup>6</sup>

Regarding management of patients, review of literature suggests two schools of thought. One school strongly suggests surgical intervention to treat subdural hygromas associated with arachnoid cyst rupture.<sup>2,7,8</sup> The surgical intervention varies from tapping, burr hole drainage, cyst fenestration to a more aggressive approach of placing ventriculo peritoneal shunt.

The other school suggests that subdural hygromas even when symptomatic are benign and are expected to spontaneously resolve in a majority of cases. Hence subdural hygroma associated with arachnoid cyst rupture is not an absolute indication for surgery.<sup>1</sup>

There have been cases where surgical intervention has resulted in complete clinical recovery but surprisingly with no radiological evidence of improvement.<sup>7</sup> This scenario is also reflected in our patient where multiple surgical intervention did not lead to reversal of radiological findings, however the baby had no clinical symptoms at all.

To summarize, this baby presented as a case of left sided subdural hygroma associated with left middle fossa arachnoid cyst rupture with radiological signs of pressure on the ipsilateral cerebral hemisphere and midline shift but with absolutely no clinical neurological signs. The right sided subdural hygroma in this case was most likely secondary to rupture of the middle cranial fossa arachnoid cyst and resolved through fenestration. The patient has recently gone through a third interventional procedure of burr hole evacuation for the non-resolving left sided subdural hygroma and will be closely monitored for further follow up.

## Conclusion

Arachnoid cysts are the most common congenital cystic intracranial abnormality. They remain asymptomatic or may present with intracranial CSF collection or with presence of subdural hematoma secondary to rupture of the cyst. Though the risk for hemorrhage carries a very low incidence. However hemorrhage or rupture of the cyst can be effectively managed by

evacuation of the hematoma or subdural hygromas. They can also resolve spontaneously. CT and MRI have significantly increased the diagnosis of arachnoid cyst along their complications with better outcome and the prognosis is generally remarkable.

## References

1. Mahar CO, Garton HJL, Al-Holou WN, et al. Management of subdural hygromas associated with arachnoid cysts. *J Neurosurg Pediatr*. Nov 2013; **12(5)**: 434-43.
2. Poirrier AL, Ngosso-Tetanye I, Mouchamps M, et al. Spontaneous arachnoid cyst rupture in a previously asymptomatic child: a case report. *Eur. J. Paediatr Neurol*. 2004; **8(5)**: 247-51.
3. Donaldson JW, Edwards-Brown M, Luerssen TG. Arachnoid cyst rupture with concurrent subdural hygroma. *PediatrNeurosurg*. Mar 2000; **32(3)**: 137-9.
4. Marshall C, John R.W.K, Richard H, et al. Research-Human-Clinical Studies Risk Factors for pediatric Arachnoid Cyst Rupture / Hemorrhage: A Case-Control Study. *Neurosurgery*. May 2013; **72(5)**: 716-22.
5. SüslüHT, Çelikoglu E, Güleç I, et al. The Association Between Arachnoid Cysts and Subdural Hygroma and Spontaneous Resolution of Subdural Hygroma. *J Neurol Sci Turk*. 2005; **22(4)**: 417-420.
6. Slaviero F, Frighetto L, Azambuja Júnior ND, et al. middle cranial fossa arachnoid cysts complicated with subdural collections *Arq Neuropsiquiatr*. Dec 2008; **66(4)**: 913-5.
7. Seçer HI, Göçmen S, Cansever T, et al. Clinical and Radiological Effects of The Treatment Modalities in a Case of Arachnoid Cyst Rupture. *Ankara Fırat Medical Journal* 2009; **12(1)**: 97-100.
8. Goswami P, Medhi N, Sarmah BJ. Case report: Middle cranial fossa arachnoid cyst in association with subdural hygroma. *Indian J Radiol Imaging* Aug 2008; **18(3)**: 222-3.