

# **<sup>131</sup>I-MIBG ON DIAGNOSTIC AND THERAPEUTIC FRONTIERS IN EXTRA-ADRENAL ABDOMINAL PARAGANGLIOMAS: A CASE REPORT WITH MINI REVIEW**

Maseeh uz Zaman,<sup>1</sup> Nosheen Fatima,<sup>2,3</sup> Zafar Sajjad,<sup>1</sup> Unaiza Zaman,<sup>4</sup> Khalil Khan,<sup>1</sup> Gufran Khan,<sup>1</sup> Sadaf Saleem,<sup>1</sup> Zohra Pirwani<sup>1</sup>

<sup>1</sup> Section of Nuclear Medicine, Department of Radiology, The Aga Khan University Hospital (AKUH), Karachi, Pakistan

<sup>2</sup> Karachi Institute of Heart Disease (KIHD), Karachi, Pakistan

<sup>3</sup> Karachi Institute of Radiotherapy and Nuclear Medicine, (KIRAN), Karachi, Pakistan

<sup>4</sup> 2nd year MBBS, Dow Medical College / DUHS, Karachi, Pakistan

PJR April - June 2012; 22(2):52-58

## **ABSTRACT**

Paraganglioma are tumors originating from paraganglial system and may be associated with parasympathetic (head, neck and anterior mediastinum tumors) or sympathetic (adrenal or extraadrenal or posterior mediastinal tumor) system. Majority of sympathetic paraganglioma and minority of parasympathetic tumor are functional and <sup>131</sup>I or <sup>123</sup>I labeled MIBG (Meta Iodio Benzyl Guanidine) is a well established tool with good sensitivity and exceedingly high specificity. We are presenting a case report of a large extraadrenal paraganglioma with extensive bony metastases and raised serum Chromogranin-A level. In this case <sup>131</sup>I-MIBG was not only helpful in revealing the true burden of functional disease but also showed an overwhelming therapeutic response proven on post-therapy MIBG scan and normalization of serum Chromogranin-A level. This case report is followed by a mini-review about pathology, genetic mutation, diagnosis and treatment of focused on extraadrenal paragangliomas.

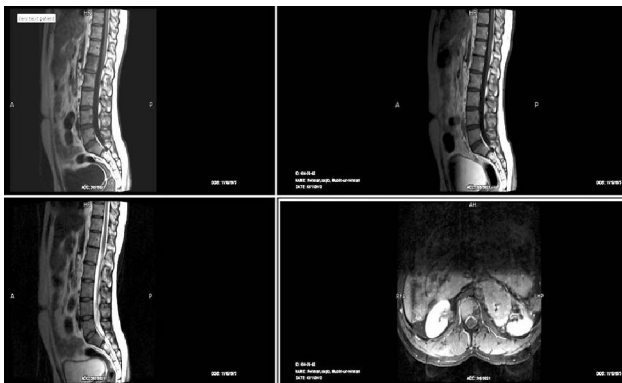**Key words:** paraganglioma; extraadrenal; MIBG; MIBG therapy; FDG-PET; Somatostatin receptor imaging

## **Case Report**

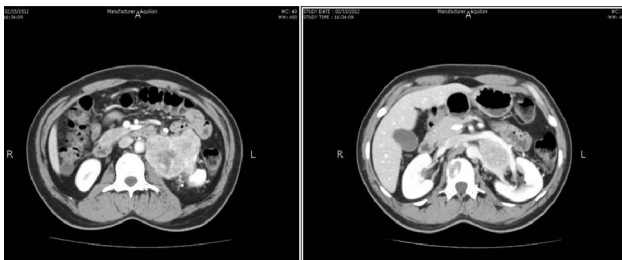
We present a case of 39 years old male, known diabetic and mildly hypertensive with 8 months history of lower backache. His MRI spine revealed a large retroperitoneal mass close to left kidney with abnormal signal intensity lesions over T10-11, L1,2,4,5 and both iliac bones with a provisional diagnosis of lymphoma (Fig. 1). A subsequent CT abdomen and Chest with contrast showed a large heterogenous enhancing soft tissue mass with necrosis located medially within left perinephric space displacing renal vein anteriorly, renal artery and ureter posteriorly. The mass lesion was also associated with multiple lytic bony lesions (Fig.2).

There was no evidence of pulmonary or liver metastases. After 3 days a whole body radionuclide bone scan (Technetium-99m Methylene Diphosphonate) was performed which revealed multiple bony metastases with lateral displacement of left kidney due to clinically known retroperitoneal mass (Fig. 3). A CT guided core biopsy of left sided abdominal mass was done and histopathology revealed paraganglioma. His vanillylmandelic acid level was raised (30 mg; Normal <13.6 mg). He underwent an exploratory laparotomy and retroperitoneal mass was resected with left kidney. Histopathology revealed paraganglioma (Ki-67 proliferative index 15-20%) and no evidence of tumor invasion to left kidney.

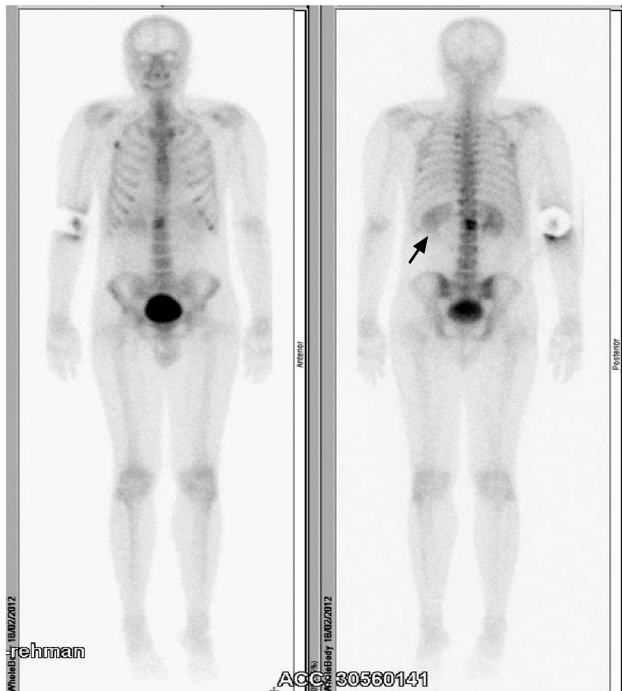**Correspondence :** Dr. Maseeh uz Zaman  
Associate Professor and Section  
Head Nuclear Medicine,  
Department of radiology, AKUH, Karachi  
Tel No.: 34930051 - Ext. 2020  
Email: maseeh.uzzaman@aku.edu



**Figure 1:** T1 pre and post contrast Sagittal and T2 sagittal images showing a area of abnormal T1 signal with enhancement. Axial post contrast T1 shows the vertebral lesion along with an enhancing mass adjacent to the left kidney.

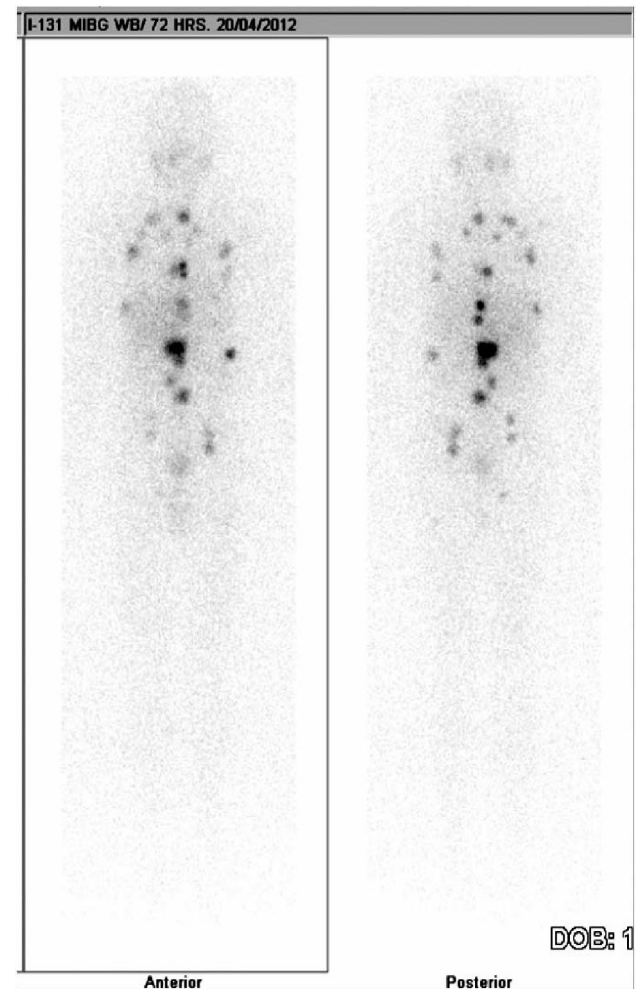


**Figure 2:** Axial contrast enhanced CT scans through the upper abdomen. There is a heterogeneous enhancing lesion in the left lumbar area lying medial to the left kidney and behind the renal vein. No evidence of vascular invasion. Note the lytic lesion in the adjacent vertebral body consistent with a metastatic deposit.

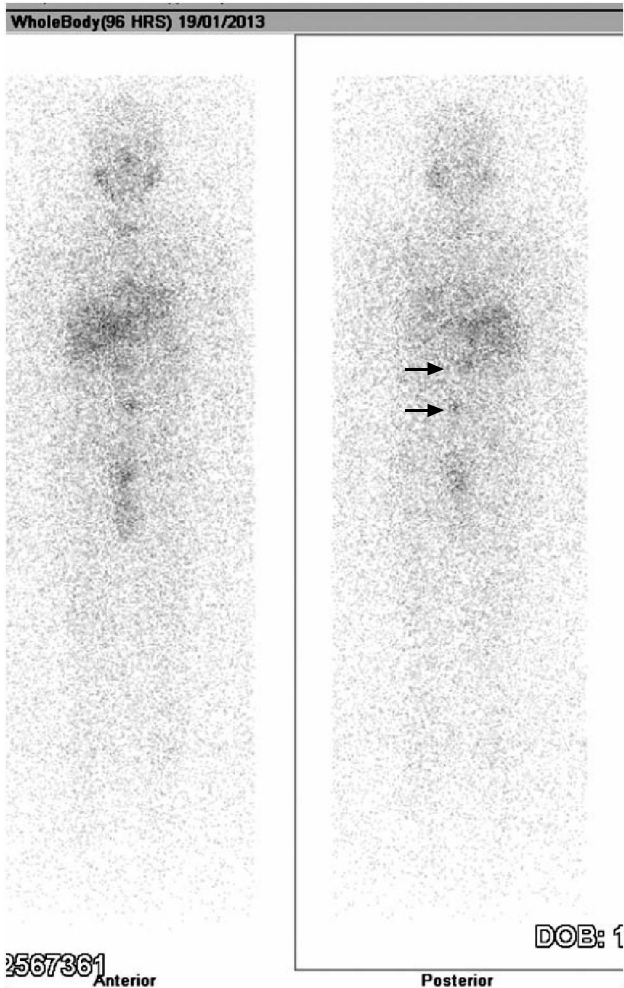


**Figure 3:** Tc-99m MDP bone scan showing desne tracer uptake over L1 (right side) and small areas of uptake over right 3rd rib and left 7th rib. Left kidney is displaced laterally (arrow) due to retroperitoneal mass.

In view of multiple bony metastases, I-131 labelled Metalodo Benzyl Guanidine (MIBG) therapy was considered and a diagnostic whole body scan with 1 mCi of <sup>131</sup>I-MIBG was performed to assess extent and avidity of functioning metastases for MIBG. This scan showed widespread MIBG-avid bony metastases involving predominantly axial skeleton (Fig. 4). His serum Chromogranin-A (CgA) level was >600 ug/liter (Normal : <36.4 ug/liter). In June and October 2012 he received 400 mCi of <sup>131</sup>I-MIBG (200 mCi per session) and in December 2012 his CgA level came down to <6 ug/liter (below normal limits). In January 2013, his follow up diagnostic whole body <sup>131</sup>I-MIBG (1 mCi) revealed complete resolution of metastatic foci with very subtle uptake over L1 and L4 consistent with complete response to radionuclide therapy (Fig. 5).



**Figure 4:** <sup>131</sup>I-MIBG diagnostic scan (72 hours; post-operative but pre-MIBG therapy) showing more extensive functioning bony metastases as compared to 99mTc-MDP bone scan.



**Figure 5:**  $^{131}\text{I}$ -MIBG diagnostic scan (96 hours; post-MIBG therapy – 400 mCi) showing complete resolution of functioning bony metastases with subtle uptake over L1 and L4 (arrows).

## Introduction

Paragangliomas are tumors that originate from neural crest stem cells and may arise anywhere along the paraganglial system and can be associated with parasympathetic or sympathetic nervous system. The parasympathetic paragangliomas develop from endocrine cells in branchiomeric paraganglial (chemoreceptors) and primarily located in head, neck and anterior mediastinum.<sup>1</sup> The sympathetic paragangliomas are derived from chromaffin cells of adrenal medulla (pheochromocytoma as per WHO's 2004 classification), the organ of Zuckerkandl, and less commonly in urinary bladder (trigone) and gall bladder.<sup>2</sup> Majority of sympathetic paragangliomas are functioning with raised plasma and urinary levels

of catecholamines (epinephrine, norepinephrine and dopamine) while majority of parasympathetic PG (5-10%) are non-functioning.<sup>3</sup>

Extraadrenal paragangliomas (EAP) of abdomen are usually retroperitoneal and arise primarily from the organ of Zuckerkandl and affect predominantly adult in 4th and 5th decade with no gender biasness.<sup>4</sup> Most paragangliomas are solitary and arise sporadically but about 25% are hereditary with a propensity for multifocal disease.<sup>5</sup> Due to this high incidence of hereditary syndrome, it has been proposed that all patients diagnosed with a pheochromocytoma or paraganglioma should consider genetic testing.<sup>6</sup> Majority of EAPG are functional and secrete catecholamines and related classical presentation like headache, palpitation and sweating.<sup>7,8</sup> While less commonly EAPG are non-functional and presented with a palpable mass or pain and other local symptoms due to retroperitoneal mass.<sup>9</sup> Approximately 10% of EAPG are non-functioning and detected incidentally (incidentaloma) during imaging for other clinical problem.<sup>10</sup> So far 10 susceptibility genes have been identified for paragangliomic tumors including succinate dehydrogenase (SDH-B, SDH-C, SDH-D), Von Hippel-Lindau disease (VHL), RET (REarranged during Transfection) in Multiple Endocrine Neoplasia type 2 (MEN2) and type-1 neurofibromatosis.<sup>2</sup> Most EAPG are highly vascular, rubbery, firm with well demarcated and expansile borders, ranging in diameter from few centimeters to 20 cm. Microscopically they are composed mainly of chief cells in a trabecular pattern with bands of highly vascular fibrous bands. No welldefined criteria for malignant paraganglioma exist for histopathologically<sup>11</sup> except the presence of documented metastases to regional lymph nodes, bone, liver and lung. The incidence of malignant paragangliomas, varies from 2% to 36%<sup>12,13</sup> for sporadic cases and >50% for patients with SDHB mutations.<sup>14</sup>

## Diagnosis

### A. Biochemical Markers:

As majority of EAPG are functional and secrete catecholamines which are metabolized within chromaffin cells to metanephrines (norepinephrine to normetanephrine and epinephrine to metanephrine,

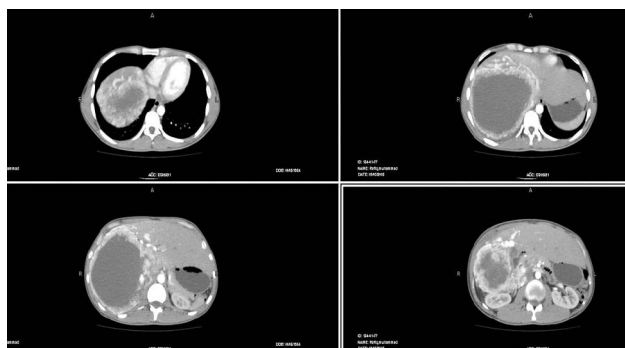


respectively), and this intratumoral process occurs independently of catecholamine release. According to current recommendations, initial testing for paragangliomas must include measurements of fractionated metanephrines in plasma, urine, or both, as available.<sup>15</sup> Blood sampling must be performed in supine posture after approximately 15 to 20 minutes of intravenous catheter insertion. Raised plasma metanephrines level more than 4-fold above the upper reference limit is associated with around 100% probability of the tumor.<sup>16</sup> However, if plasma metanephrine values are above the upper but less than 4 fold reference limit, clonidine suppression test combined with measurements of plasma catecholamines and normetanephrine may prove useful.<sup>15</sup>

## B. Imaging

### B1. Anatomical imaging:

Cross sectional anatomical imaging: like computed tomography (CT) or magnetic resonance imaging (MRI) is recommended for initial tumor localization, preferably MRI in children and pregnant or lactating women because of concerns regarding radiation exposure. On contrast-enhanced CT scans, these tumors appear as para-aortic soft-tissue masses with either homogeneous enhancement or central areas of low attenuation (Fig 6). Smaller tumors are more likely to be homogeneous in attenuation and sharply margined as compared with larger ones. Punctate calcification or focal areas of high attenuation caused by acute hemorrhage may be seen in some tumors.



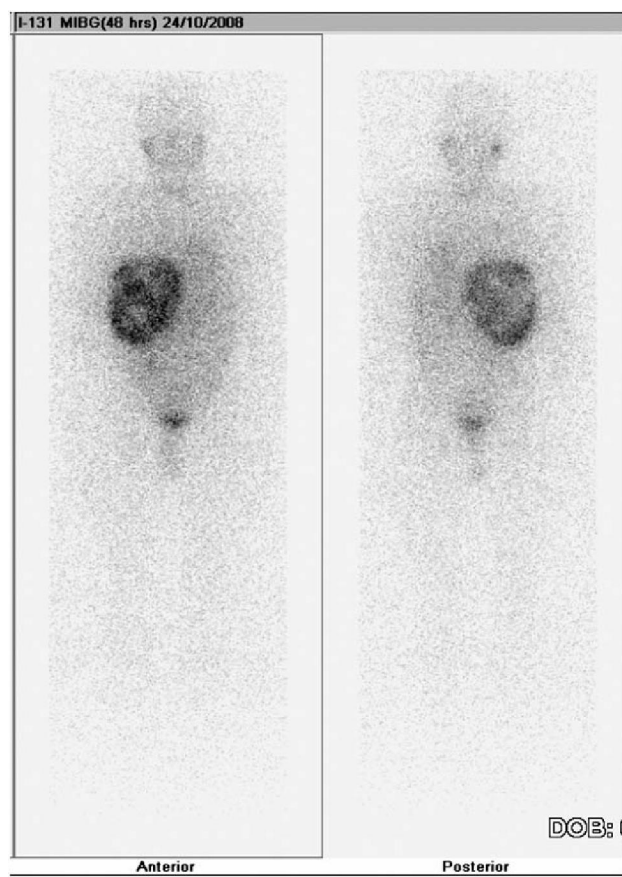
**Figure 6:** Post Contrast Axial CT of the upper abdomen showing a large, highly vascular lesion with central necrosis in the right lobe of the liver.

CT can be performed safely with intravenous nonionic contrast material as no elevation of serum catecholamine levels have been found in recently

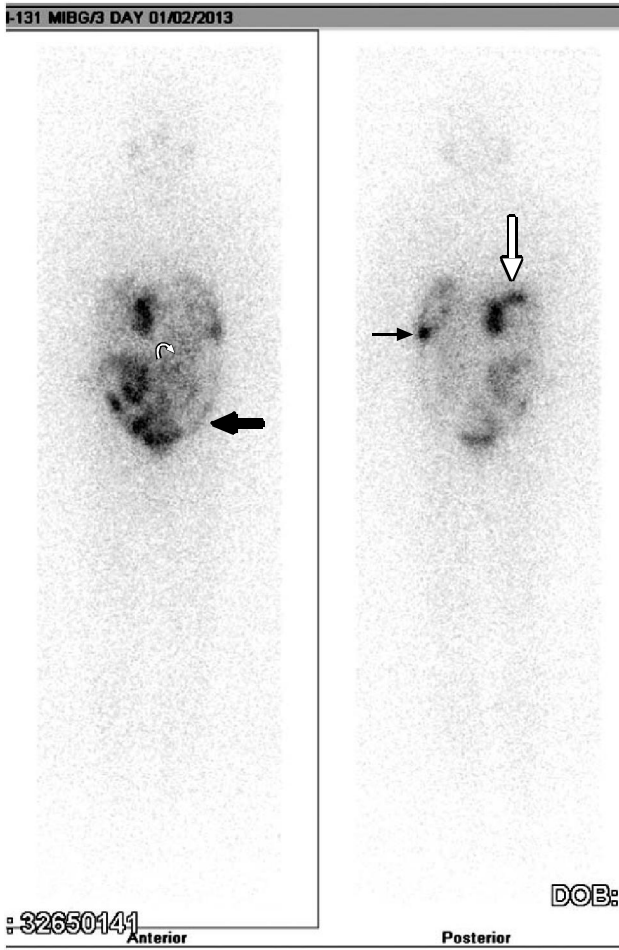
studies.<sup>17</sup> On MRI these tumors are usually hypointense or isointense compared with the liver parenchyma on T1-weighted images and are markedly hyperintense on T2-weighted images<sup>18</sup> (Fig. 1). CT and MRI, unlike MIBG scintigraphy, are not useful in differentiating functioning from nonfunctioning paragangliomas. Even though MRI and CT have excellent sensitivity (90-100%), the ability of CT and MRI alone to specify a paraganglioma is 70-80%.<sup>19</sup>

### B2. Functional Imaging

i) **Meta IodoBenzyl Guanidine (MIBG)**, labelled with either <sup>123</sup>I (pure gamma emitter) or <sup>131</sup>I (beta particle and gamma rays emitter), is a norepinephrine analogue taken up from the circulation by adrenergic tissues via norepinephrine transporter (NET) [type-I uptake]. MIBG scintigraphy provides useful functional information and can be used for the detection of multiple primary tumors, tumors outside the usual locations, or metastases (Fig. 7 and 8). MIBG scanning offers very good specificity (95–100%) but suffers



**Figure 7:** <sup>131</sup>I-MIBG diagnostic scan (48 hours; pre-operative) showing a huge biopsy proven paraganglioma occupying the almost whole of right hepatic lobe but no distant metastasis.

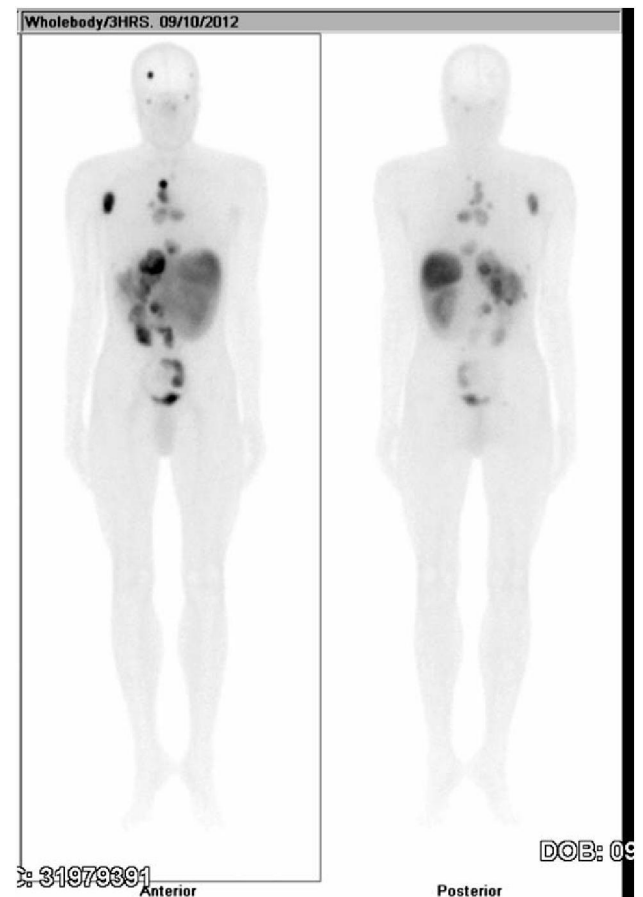


**Figure 8:** A case recurrent right sided pheochromocytoma (open arrow) with extensive omental (curved arrow), splenic (black arrow) and intestinal deposits (thick black arrow).

from relatively imperfect sensitivity (85%).<sup>20</sup> However, MIBG scintigraphy coupled with CT imaging ensures better sensitivity (80%–90%) and specificity (95%–100%).<sup>19</sup> Functional imaging is probably not necessary in the preoperative work-up of patients with negative genetic testing and a small paraganglioma. However, in absence of genetic status before surgery, MIBG imaging is employed for detection of multifocal or metastatic disease. If there is no family history, the need to exclude multiple lesions is particularly important in younger patients ( $\leq 40$  y) and patients with a larger paraganglioma ( $>5.0$  cm).<sup>21</sup>

**ii) Somatostatin receptor imaging** is a non-specific functional imaging. Both pheochromocytomas and paragangliomas express somatostatin receptors. Indium-111 or Technetium-99m labeled octreotide

imaging is useful for identifying malignant / metastatic pheochromocytomas or EAPG with sensitivity approaching 90%<sup>19</sup> (Fig. 9).



**Figure 9:** <sup>99m</sup>Tc-HYNIC Octreotide scan in a patient with recurrent hepatic paraganglioma with extensive nodal and bony metastases.

**iii) Positron Emission Tomography (PET):** Fluorine-18 labeled deoxyglucose (<sup>18</sup>F-FDG) PET has shown uptake of FDG in most pheochromocytomas and recently it has been demonstrated to be a superior tool in the evaluation of metastatic SDHB-associated adult pheochromocytoma and paraganglioma.<sup>14</sup> Newer PET compounds such <sup>18</sup>F-fluorodopamine (<sup>18</sup>F-FDA) and <sup>18</sup>F-fluorodihydroxyphenylalanine (<sup>18</sup>F-FDOPA) have emerged with superiority over MIBG for diagnosis of malignant paraganglioma and pheochromocytomas, although <sup>18</sup>F-FDOPA has been reported limited sensitivity for metastatic disease.<sup>14</sup>


## Treatment

The mainstay of treatment of EAPG is surgical resection, either exploration or laproscopically with

strict pre and per-operative pharmacological blockade using alpha and beta blockers. Preoperative arterial embolization of paraganglioma may be performed to minimize blood loss and adequate resection. After resection, close follow up is necessary as reported recurrence rate for EAPG is 0-7%.<sup>22</sup> The recommended treatment options for recurrent or metastatic paraganglioma is surgical removal and debulking or palliative embolization, radiotherapy, and chemotherapy (cyclophosphamide, vincristine, dacarbazine) when surgery is not a viable option. Radionuclide treatment with high doses of <sup>131</sup>I-MIBG is also a good option with overall initial improvement in symptoms (75%) but only 30% partial tumor remission and <5% of patients demonstrating a complete response.<sup>22</sup>

## References

1. Lee KY, Oh YW, Noh HJ, Lee YJ, Yong HS, Kang EK, et al. Extraadrenal Paragangliomas of the Body: Imaging Features. *AJR* 2006; **187**: 492-504.
2. Taý'eb D, Neumann H, Rubello D, Al-Nahhas A, Guillet B, Hindie E. Modern Nuclear Imaging for Paragangliomas: Beyond SPECT. *J Nucl Med* 2012; **53**: 264-74.
3. Henri JLMT, Karel P, Thanh TH, Mones A, Maria T, Maria JM, et al. Biochemically Silent Abdominal Paragangliomas in Patients with Mutations in the Succinate Dehydrogenase Subunit B Gene. *J Clin Endocrinol Metab* 2008; **93**: 4826-32.
4. Saurborn DP, Kruskal JB, Stillman IE, Parangi S. Best cases from the AFIP: paraganglioma of the organs of Zuckerkandl. *RadioGraphics* 2003; **23**: 1279-86.
5. Mannelli M, Castellano M, Schiavi F, Filetti S, Giacchè M, Mori L, et al. Clinically guided genetic screening in a large cohort of Italian patients with pheochromocytomas and/or functional or nonfunctional paragangliomas. *J Clin Endocrinol Metab*. 2009; **94**: 1541-7.
6. Amar L, Bertherat J, Baudin E, Ajzenberg C, Paillerets BB, Chabre O, et al.: Genetic testing in pheochromocytoma or functional paraganglioma. *J Clin Oncol* 2005; **23 (34)**: 8812-8.
7. O'Riordain DS, Young WF Jr, Grant CS, Carney JA, van Heerden JA. Clinical spectrum and outcome of functional extraadrenal paraganglioma. *World J Surg* 1996; **20**: 916-21.
8. Roman S. Pheochromocytoma and functional paraganglioma. *Curr Opin Oncol* 2004; **16**: 8-12.
9. Saurborn DP, Kruskal JB, Stillman IE, Parangi S. Best cases from the AFIP: paraganglioma of the organs of Zuckerkandl. *RadioGraphics* 2003; **23**: 1279-86.
10. Dunnick NR, Korobkin M. Imaging of adrenal incidentalomas: current status. *AJR* 2002; **179**: 559-68.
11. Lack EE, Cubilla AL, Woodruff JM. Paragangliomas of the head and neck region: a pathologic study of tumors from 71 patients. *Hum Pathol* 1979; **s** 191-218.
12. Nora JD, Hallett JW Jr, O'Brien PC, Naessens JM, Cherry KJ Jr, Pairolero PC. Surgical resection of carotid body tumors: long-term survival, recurrence, and metastasis. *Mayo Clin Proc* 1988; **63**: 348-52.
13. O'Riordain DS, Young WF Jr, Grant CS, Carney JA, van Heerden JA. Clinical spectrum and outcome of functional extraadrenal paraganglioma. *World J Surg* 1996; **20**: 916-21.
14. Chen H, Sippel RS, O'Dorisio MS, Vinik AI, RV Lloyd, Pacak K. The North American Neuroendocrine Tumor Society Consensus Guideline for the Diagnosis and Management of Neuroendocrine Tumors: Pheochromocytoma, Paraganglioma, and Medullary Thyroid Cancer. *Pancreas* 2010; **39**: 775-83.
15. Grossman A, Pacak K, Sawka A. Biochemical diagnosis and localization of pheochromocytoma: can we reach a consensus? *Ann N Y Acad Sci*. 2006; **1073**: 332-7.
16. Eisenhofer G, Goldstein DS, Walther MM, Friberg P, Lenders JWM, Keiser HR, et al. Biochemical diagnosis of pheochromocytoma: how to distinguish true- from false-positive test results. *J Clin Endocrinol Metab*. 2003; **88 (6)**: 2656-66.3

- 
- 
17. Baid S, Lai EW, Wesley RA. Contrast enhanced computed tomography does not induce catecholamine release in patients with pheochromocytoma. *Ann Intern Med.* 2009; **150**: 27-32.
  18. Quint LE, Glazer GM, Francis IR, Shapiro B, Chenevert TL. Pheochromocytoma and paraganglioma: comparison of MR imaging with CT and I-131 MIBG scintigraphy. *Radiology* 1987; **165**: 89-93.
  19. Ilias I, Pacak K: Current approaches and recommended algorithm for the diagnostic localization of pheochromocytoma. *J Clin Endocrinol Metab* 2004; **89 (2)**: 479-91.
  20. Shapiro B, Sisson JC, Shulkin BL, Gross MD, Zempel S. The current status of metaiodobenzylguanidine and related agents for the diagnosis of neuroendocrine tumors. *Q J Nucl Med* 1995; **39 (1)** : 3-8.
  21. Ayala-Ramirez M, Feng L, Johnson MM, Ejaz S, Habra MA, Rich T, et al. Clinical risk factors for malignancy and overall survival in patients with pheochromocytomas and sympathetic paragangliomas: primary tumor size and primary tumor location as prognostic indicators. *J Clin Endocrinol Metab.* 2011; **96**: 717-25.
  22. Disick GIS, Palese MA. Extra-adrenal Pheochromocytoma: Diagnosis and Management. *Current Urology Reports* 2007, **8**: 83-8.