

# OSSIFICATION OF POSTERIOR LONGITUDINAL LIGAMENT OF SPINE- A RECOGNIZABLE CAUSE OF MYELOPATHY IN PAKISTAN

Shahbaz Ahmad Ch, Adnan Latif Malik, Tahir Qadeer Khan<sup>1</sup>

Department of Orthopaedic & Spine Surgery King Edward Medical University, Mayo Hospital Lahore, Pakistan

<sup>1</sup> Department of Radiology, Mayo Hospital Lahore, Pakistan

PJR April - June 2012; 22(2):40-43

## ABSTRACT

Ossification of the Posterior Longitudinal Ligament (OPLL) is not so rare disorder in spine. We reviewed retrospectively three cases of cervical stenosis complicated by Myelopathy in two men and one woman. All patients presented with signs of cervical myelo-radiculopathy of varying degrees. Diagnosis was made clinically & confirmed radiologically with plain radiographs, MRI scan, and CT 3D reconstruction. Surgical decompression was done, two patients underwent laminoplasty and one patient was treated by laminectomy. They all showed favourable outcome following surgical decompression.

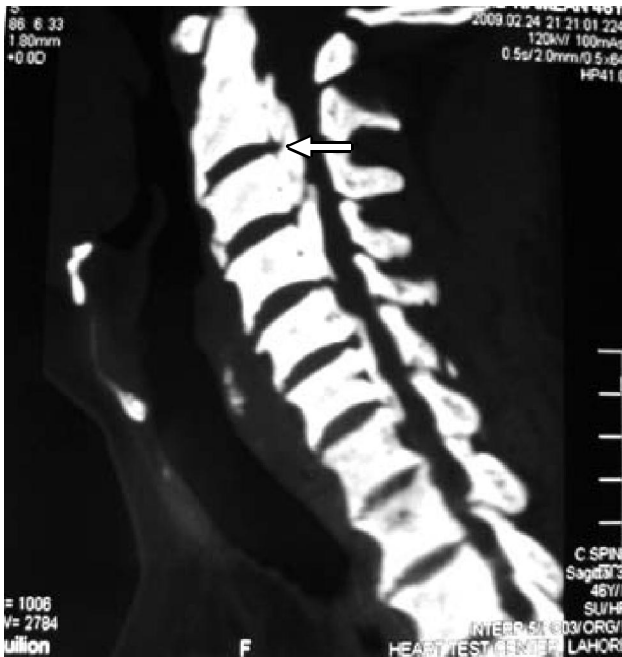**Key words:** Ossification posterior longitudinal ligament (OPLL), cervical spine, Myelopathy

## Introduction

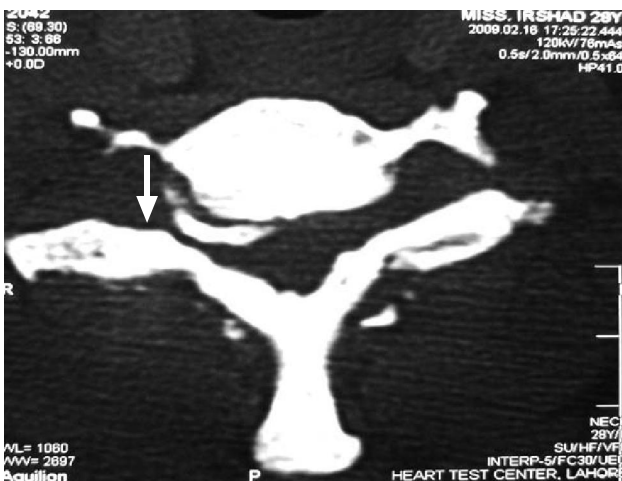Ossification of the Posterior Longitudinal Ligament (OPLL) is a rare entity. It has most commonly been described in the Far East, notably in Japan. It is a noticeably important factor resulting in spinal stenosis leading to Myelopathy. It is estimated that upto 25% patients with cervical myelopathy have features of OPLL.<sup>1</sup> The OPLL predominantly follows geographical distribution. There have been limited reports of this condition in non-Japanese patients. It is considered a rare cause in South East region including Pakistan. OPLL usually presents with Myelopathy in the setting of thoracic spinal stenosis, but its exact etiology remains unknown.<sup>9,10</sup> OPLL however, has been associated with skeletal fluorosis,<sup>2</sup> trauma, diffuse skeletal hyperostosis (DISH),<sup>3</sup> ankylosing spondylitis,<sup>3</sup> diabetes,<sup>4</sup> hemochromatosis, hyperthyroidism, and deposition of calcium pyrophosphate crystals. The pathogenic process of OPLL is similar to heterotopic bone formation in response to mechanical stress in

other tissues. Cartilage cells proliferate first in the periosteum of the vertebral body and then in the annulus fibrosus, longitudinal ligament and dura. The ligament becomes calcified by endochondral ossification. Mature lamellar bone is eventually formed. Only a minority of patients with OPLL are symptomatic. Therefore, patients may be able to compensate for deep indentations in the ventral spinal cord. Patients with congenital spinal stenosis may be predisposed to earlier symptoms if OPLL present. Symptoms also worsened by formation of degenerative osteophytes and/or hypertrophied/ossified ligament flavum (OLF).<sup>10</sup> Decompensation usually occurs after 50-60% of the AP diameter of the spinal canal is occupied (Fig.1). Mild trauma may precipitate quadriplegia.

**Correspondence :** Dr. Adnan Latif Malik  
Department of Orthopaedic & Spine Surgery  
King Edward Medical University, Lahore, Pakistan.  
Ph.: 0300-4204410  
E-mail: dr.adnanmalik@hotmail.com



**Figure 1:** Sagittal view of CT scan cervical spine showing ossification of PLL.



**Figure 2:** Axial view of CT scan cervical spine showing ossification of PLL.

## Material and Method

We reviewed retrospectively three cases of cervical stenosis complicated by Myelopathy in two men and one woman. All patients presented with signs of cervical myelo-radiculopathy of varying degrees. Diagnosis was made clinically & confirmed radiologically with plain radiographs, MRI, and CT scan.

A decompressive laminectomy including one level above and below the lesion was the procedure of choice. In two cases decompressive Laminoplasty &

in one case Laminectomy was done. Postoperatively serial complete neurological examination was performed. All patients commenced with in-patient physiotherapy. In our group there was marked neurological improvement in early postoperative period.

## Results

All patients underwent surgical decompression made uneventful recovery with improvement in power & sensation with the passage of time.

## Discussion

Ossification of Posterior longitudinal ligament causing severe Myelopathy is called Japanese disease. Recently it has been shown that this condition is not only seen in Japan but also in other countries of the South East Asia especially in Pakistan. Ossification of Posterior Longitudinal ligament & ossification of Ligamentum Flavum are characterized by progressive ectopic bone formation in these spinal ligaments.<sup>10</sup> Multiple etiological factors & mechanical stress plays an important role in its development. The exact underlying etiology & pathogenesis still remains an enigma.<sup>6,7</sup> However, the association of OPLL & OLF may share similar etiology & pathogenesis with other hyperostotic conditions such as Ankylosing Spondylitis, Forestier disease & Diffuse Idiopathic skeletal Hyperostosis etc.<sup>3,5</sup> Ossification of posterior longitudinal ligament is characterized by hyperplasia of cartilagenous cells with eventual endochondral ossification. OPLL occurs after the age of 40 years and the most commonly affected region is the cervical spine, usually at C4/5, although the thoracic and lumbar regions are not exempt.<sup>7,8</sup> The frequency of involvement diminishes as the level descends as follows: cervical 70-75%, thoracic 15-20% and lumbar 10%.

The signs & symptoms of ossified posterior longitudinal ligament are numbness in the hand or legs, neck pain, awkward hand movements and gait disturbances. Pathological compression by OPLL above a certain critical point may be the most significant factor in inducing Myelopathy. The CT scan features ossified posterior longitudinal are distinctive. A 2-5 mm thick linear ossified strip along the posterior vertebral margin usually at mid cervical region (C3-C5) characterizes the condition. MRI is valuable in excluding possible cord damage & other associated disc lesion prior to

surgery.<sup>5,7</sup> It is also helpful in showing the extent of ossification well in term of height & cord compression, while CT is useful to measure thickness of the bone mass & residual of the spinal canal.<sup>8</sup> Since ossification of longitudinal ligament occurs at several levels, meticulous attention to both clinical and radiological findings is mandatory in determining the level of involvement.<sup>8,9</sup>

Laminectomy with or without fusion, or Laminoplasty may be successfully employed to address multilevel cervical pathology due to ossified posterior longitudinal ligament in a carefully selected population.<sup>11,12</sup> The clinical outcome of surgery can be evaluated by using the Japanese Orthopaedic Association Score (JOA score).<sup>13,14</sup>

#### SUMMARY OF JOA SCALE GRADES FOR CERVICAL MYELOPATHY

VARIABLE	GRADE
<b>1. Motor function</b>	
a. Upper extremity	
I. Unable to feed oneself	0
II. Unable to handle chopsticks; able to eat w/ a spoon	1
III. Handles chopsticks w/ much difficulty	2
IV. Handles chopsticks w/ slight difficulty	3
V. Normal	4
b. lower extremity	
I. unable to stand & walk by any means	0
II. need a cane or aid on level ground	1
III. need cane or aid on stairs	2
IV. capable of fast walking but clumsy	3
V. normal	4
<b>2. Sensory function</b>	
a. upper extremity	
i. apparent sensory loss	0
ii. minimal sensory loss	1
iii. normal	2
b. lower extremity	
i. apparent sensory loss	0
ii. minimal sensory loss	1
iii. normal	2
c. trunk	
i. apparent sensory loss	0
ii. minimal sensory loss	1
iii. normal	2
<b>3. Bladder function</b>	
a. urinary retention &/or incontinence	0
b. sense of retention &/or dribbling &/or thin stream	1
c. urinary retardation &/or pollakiuria	2
d. Normal	3

**Cumulative normal grade in a healthy individual is 17**


The diagnosis & treatment of clinical ossification of Posterior Longitudinal ligament is continuing to evolve & its effects become more readily recognized & surgical decompression is the main stay of treatment in such cases.<sup>11,12</sup>

## Conclusion

We recommend high index of suspicious OPLL in cases of cervical Myelopathy, in our region. Besides meticulous neurological examination, a thorough MRI exam of the whole spine is also strongly recommended. The presence of one level ossification should alert the surgeon of the possibility of multiple lesions (e.g. type II or III). It has been reported that electrophysiological diagnosis may be useful for establishing the responsible lesions in patients with multilevel spinal stenosis. In terms of the surgical treatment for spinal ossifications, how to establish the surgical extent is very important. Failure to do so may result in the wrong operative approach, inadequate decompression and increased neurological dysfunction.

## References

1. Epstein N: Ossification of the cervical posterior longitudinal ligament: a review. *Neurosurg Focus* **13:2** ECP1, 2002
2. Gupta RK, Agarwal P, Kumar S, Surana PK, Lal JH, Misra UK: Compressive myelopathy in flurosis. MRI. *Neuroradiology* 1996; **38**: 338-42.
3. Ramos-Remus C, Russell AS, Gomez-Vargas AS, Hernandez-Chavez A, Maksymowych WP, Gamez-Nava JI, et al.: Ossification of the posterior longitudinal ligament in three geographically and genetically different populations of ankylosing spondylitis and other spondyloarthropathies. *Ann Rheum Dis* 1998; **57**: 429-33,
4. Inamasu J, Guiot BH, Sachs DC: Ossification of the posterior longitudinal ligament: an update on its biology, epidemiology, and natural history. *Neurosurgery* 2006; **58**:1027-39,
5. M Khalid, Khan A Mannan, Sakeer Hussain, Reyazuddin. Ossification of posterior longitudinal ligament (OPLL) presenting as cervical myelopathy. *Indian Journal of Rad* 2000; **4**: 253-4.

- 
- 
6. Harsh IV, Griffith R, Sybert GW, Wienstein PR, Ross DA, Wilson Charles B. Cervical spine stenosis secondary to ossification of the posterior longitudinal ligament. *J Neurosurgery* 1987; **67**: 349-57.
  7. Hyman RA, Merten CW, Liebeskind AL, Naidich JB and Stein HL. Computed Tomography in ossification of the posterior longitudinal spinal ligament. *Neuroradiology* 1977; **13**: 227-8.
  8. Tadao N, Taikei E, Takao E, Yutaka M. Ossification of posterior longitudinal ligament, a clinico radiological study of 47 cases. *Journal of Neurology, Neurosurgery and Psychiatry* 1987; **50**: 321-6.
  9. Nagashima C. Cervical myelopathy due to ossification of posterior longitudinal ligament. *J Neurosurgery* 1972; **37**: 653-60.
  10. Fujiwara M, Bitoh S, Hasegawa H, Nakata M, Hata H. A case of nodular calcification of the ligamentum flavum with ossification of the posterior longitudinal ligament in the cervical spine. *No Shinkei Geka* 1982; **10**: 769-74.
  11. Yonenobu K, Wada E, Suzuki S, Kanazawa A. The dorsal approach in degeneratively changed cervical spine. *Orthopade* 1996 Nov; **25(6)**: 533-41
  12. Yue W, Tan CT, Tan SB, et al: Results of cervical laminoplasty and a comparison between single and double trap-door techniques. *J Spinal Disord* 2000; **13**: 329-35.
  13. Huduku S, Muchizuki T, Ogata M, Schichikuwa K, Shimamura Y. operations for cervical spondylotic myelopathy: a comparison of the results of anterior and posterior procedures. *J Bone Joint Surg Br* 1985; **67**: 609-15,
  14. Houten JK, Cooper PR. Laminectomy and posterior cervical plating for multilevel cervical spondylotic myelopathy and ossification of the posterior longitudinal ligament: effects on cervical alignment, spinal cord compression, and neurological outcome. *Neurosurgery* 2003; **52**: 1081-7.