

PERCUTANEOUS DRAINAGE OF ILIOPSOAS ABSCESS IN AN PATIENT WITH INCIDENTAL HIV INFECTION

Igbinedion, Blessing Ose-Emenim,¹ Irowa, Omoruyi Omorodion²

¹Senior Lecturer/Consultant Radiologist, University of Benin/University of Benin Teaching Hospital, Benin, Edo, Nigeria.

²Consultant Surgeon, University of Benin Teaching Hospital, Benin, Edo, Nigeria.

PJR October - December 2012; 22(4): 147-149

ABSTRACT

The abscess in iliopsoas muscle compartment is fairly uncommon in patients with Human immunodeficiency virus (HIV) infection leads to depression of immunity (autoimmune deficiency syndrome; AIDS) which is unfortunately common in Africa. In this case report we are presenting the role of diagnostic imaging in the management of a patient presented with a space occupying lesion involving iliopsoas region.

Key words: HIV; AIDS; Abscess; Iliopsoas, tuberculosis

Introduction

Human immunodeficiency virus (HIV) infection leads to depression of immunity (autoimmune deficiency syndrome; AIDS) which exposes the individual to diseases from opportunistic organisms. The iliopsoas muscle compartment is seldom affected by pathologic conditions,¹ though HIV/AIDS patients are commonly referred to the surgeon on account of abdominal pain complaints.² In the preceding period before computerized tomography (CT) was introduced, iliopsoas abscess had late presentation due to its insidious onset, obscure signs and symptoms and non-specific radiographic features.³ Hence surgical open drainage (which is still largely the practice in our environment) was delayed leading to increased complication rates. It is reported that mycobacterium tuberculosis with secondary vertebral osteomyelitis is a common cause of psoas abscess in countries (Nigeria inclusive) where TB is prevalent.⁴ However, there is no reported case of iliopsoas abscess in the reference

environment in patient with immuno-suppression arising from HIV/AIDS and (to the best of our knowledge) no patient has had drainage of iliopsoas abscess performed percutaneously in Nigeria. We describe an unusual case of intra-abdominal abscess in an incidentally diagnosed HIV infected patient mimicking an iliopsoas muscle neoplasm that was managed by ultrasound guided percutaneous drainage.

Case Report

A 32 year old female presented at the Urology clinic of the University of Benin Teaching Hospital (UBTH) after been referred from a secondary care hospital on account of left flank pain of 5 year duration which worsened significantly in the last 2 months. The patient had abdominal ultrasound and CT done prior to presentation. The ultrasound revealed a left psoas muscle mass with associated left hydronephrosis and retroperitoneal enlarged lymph nodes, while the CT

Correspondence : Dr. Igbinedion, Blessing Ose-Emenim, Senior Lecturer/Consultant Radiologist, University of Benin/University of Benin Teaching Hospital, Benin, Edo, Nigeria. E-mail: igbins2@yahoo.com.

showed a left psoas mass suspected to be either a cold abscess (likely from tuberculosis) or a rhabdomyosarcoma (Fig. 1). An ultrasound guided fluid

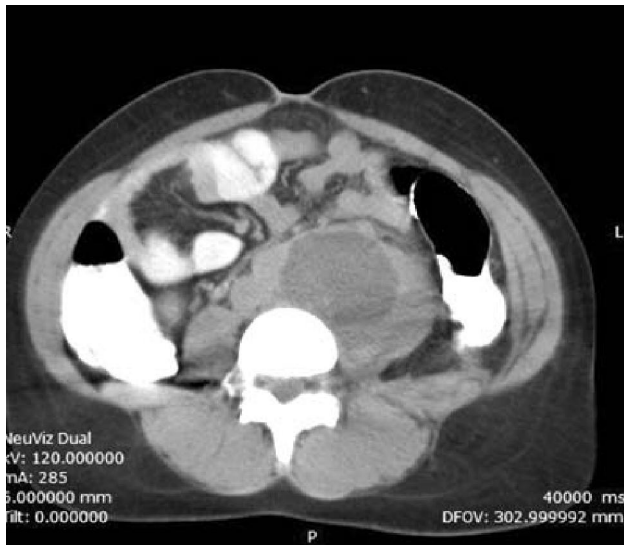


Figure 1. The patient's CT scan image showing enlarged left iliopsoas muscle with a hypodense lesion within it and some surrounding fatty stranding.

aspiration was done using an 18G trocar and stylet assemblage (Fig. 2). About 8 ml of very viscid fluid

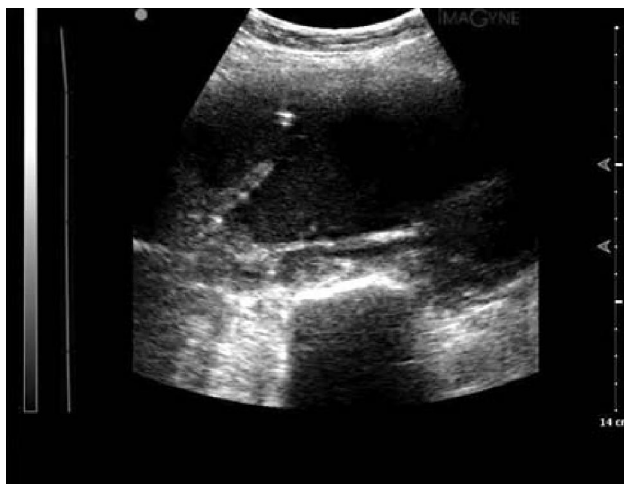

Figure 2: Ultrasound image during aspiration of the iliopsoas abscess with the draining trocar shown (arrowed).

was aspirated. Further attempt to aspirate more fluid proved abortive. The patient was then placed on antibiotics (Ciprofloxacin 500mg) and therapeutic trial of anti-tuberculous (Rifampicin 600mg, Isoniazid 300mg, Pyrazinamide 1.5mg, Ethambutol 800mg, Pyridoxine 50mg) and analgesic (Diclofenac Sodium 100mg) drugs. The aspirate confirmed that it was an abscess and it was sent for microscopy, culture and sensitivity and for alcohol and acid fast bacilli (AAFB).

Gram positive cocci were cultured from the aspirate and there was no AAFB.

On her next clinic visit two weeks later, the patient was now afebrile and could walk. Ultrasound guided aspiration of 345 ml of purulent fluid was performed from an abscess cavity that measured 12.3 cm x 7.4 cm x 7.3 cm, remaining some deep-seated septated fluid within the pelvis. Laboratory results were now available which include a reactive retroviral screening result, sputum for m/c/s yielded gram positive cocci (strepto-coccus spp.) while sputum was negative for acid fast bacillus. Mantoux test was non-reactive with 0 mm reading. A repeat image-guided aspiration was performed a month later yielded about 220 ml of purulent fluid. The abscess cavity was ablated with 96% alcohol after irrigation and aspiration of 50 ml of normal saline. The patient was discharged home same day after an hour of observation at the end of each of the image-guided aspiration.

Following the reactive retroviral screening the patient was referred to the HIV/AIDS clinic in our facility and she was placed on HAART (highly active antiretroviral therapy) while the anti-TB therapy was continued. At the last surgical outpatient clinic visitation by the patient, there was no back pain, the tenderness to the lower lumbar region/left para-spinal area and her general conditions improved markedly. Follow up ultrasound three months after did not show abscess re-accumulation.

Discussion

Percutaneous drainage (PCD) of abscess is one of the most common and rewarding procedures performed by interventional radiologists (IR) because it markedly reduces morbidity and mortality when compared with open (surgical) drainage by offering precise non-invasive localization of fluid collections, minimally invasive therapeutic techniques, avoidance of general anaesthesia in most cases and shortening of hospital stay.⁸ In the last two decades image guided percutaneous drainage has evolved and has become an important treatment option in the management of iliopsoas abscess. Unfortunately, the services of IRs is unavailable in many Nigerian hospitals due to scarcity of trained radiologists, unavailability of appropriate equipment and IR materials, and potential probable reluctance of clinicians to refer patients. In addition, in some hospital settings the IR has to improvise

materials or source it through difficult and discouraging acquisition processes.

PCD is been considered the draining method of choice.^{3,9} Studies have shown that the combination of PCD and antibiotic completely treats iliopsoas abscess.⁹ In this case we utilized an 18G trocar and stylet assemblage set under ultrasound guidance to drain significant amount of purulent fluid from the left iliopsoas which led to remarkable clinical improvement of the patient. The patient was managed as a day case on each aspiration procedure day and observed for an hour with immediate discharge after satisfactory clinical status during observation. Consequently, the cost was significantly reduced when compared to an open surgery. Open surgical drainage is indicated when the abscess collection is large, multi-loculated, inaccessible (due to overlying bowels), unable to control sepsis or in some cases of secondary iliopsoas abscess (e.g. associated gastrointestinal or genitourinary diseases).

Just as in this case report, the diagnosis of iliopsoas abscess by use of CT poses a diagnostic dilemma. Differentiation between iliopsoas abscess and neoplasm is difficult as both can present with enlarged muscle bulk and hypodense mass, which may have gaseous foci.¹⁰ Hence percutaneous drainage may serve both diagnostic (biopsy specimen taken) and therapeutic (drainage of the abscess) purposes. CT-guided PCD unlike ultrasound has the added advantage of detecting the abscess irrespective of overlying bowels, showing the possible drainage pathways and detecting other associated lesions. Psoas abscess drainage can be done by direct needle aspiration or through the use of drainage catheter. Acetylcysteine can be used to liquefy viscid abscess.¹² Unfortunately it is unavailable in our centre, hence we had to place the patient under appropriate antibiotic cover before draining the abscess at a later date. Ablation with 96% alcohol after complete aspiration of the abscess and normal saline irrigation of the cavity was done in this patient which was seldom performed by other authors. We hypothesize that alcohol ablation of iliopsoas abscess cavity may reduce the recurrence rate, hence future studies on a larger scale should be investigated.

Conclusion

Percutaneous drainage of iliopsoas abscess is achievable in Nigeria. This case has clearly shown the advantage of collaboration between the surgeon and the

(interventional) radiologist for the best management regimen to undertake for individual patients with iliopsoas abscess (and also for other cases).

References

1. Charalampopoulos A, Macheras A, Charalabopoulos A, Fotiadis C, Charalabopoulos K. Iliopsoas abscess: Diagnostic, etiologic and therapeutic approach in five patients with a literature review. *Scand J gastroenterol* 2009; **44**: 594-9.
2. Parente F, Cernuschi M, Antinori S, et al. Severe abdominal pain in patients with AIDS: frequency, clinical aspects, causes, and outcome. *Scand J Gastroenterol* 1994; **29(6)**: 511-5.
3. Mueller PR, Ferrucci JT, Wittenberg J, Simeone JF, Butch RJ. Iliopsoas abscess: Treatment by CT-guided percutaneous catheter drainage. *AJR* 1984; **142**: 359-62.
4. Muckley T, Schutz T, Kirschner M, et al. Psoas abscess: the spine as a primary source of infection. *Spine* 2003; **28**: 106-13.
5. Lorenz J, Thomas JL. Complications of percutaneous fluid drainage. *Semin Intervent Radiol* 2006; **23**: 194-204.
6. Yacoub WN, Sohn HJ, Chan S, Petrosyan M, Vermaire HM, Kelso RL, Towfigh S, Mason RJ. Psoas abscess rarely requires surgical intervention. *Am J Surg* 2008; **198(2)**: 223-7.
7. Ebraheim NA, Rabenold JD, Patil V, Sanford CG. Psoas abscess: a diagnostic dilemma. *Am J Orthop* 2008; **37(1)**: 11-3.
8. vanWaes PF, Feldberg MA, Mali WP, Ruijs SH, Eenhoorn PC, Buijs PH, Kruis FJ, Ramos LR. Management of loculated abscesses that are difficult to drain: a new approach. *Radiology* 1983; **147(1)**: 57-63.