

RETROAORTIC INVERTED LEFT RENAL VEIN: A RARE ANOMALY FOUND IN A RENAL DONOR

Sofia Sabouri,¹ Hoseinee,¹ Seyedeh Shirin Shivaei²

¹Department of Radiology, Shohada-e-Tajrish Hospital, Shahid Beheshti University of Medical Science, Tehran, Iran.

²Tooska Medical Imaging Center, Tehran, Iran.

PJR October - December 2012; 22(4): 135-138

ABSTRACT

Awareness of the renal vascular anatomy, including variants of the renal vein, is important for abdominal and renal surgery including renal transplantation. The complex embryological development of the renal vein results in the following variations: additional renal veins (ARVs), on the left side, circum-aortic renal collar and retro-aortic renal veins. We are going to report a case of 35 years old renal donor who had a rare renal vein anomaly that had been shown by computed tomography (CT) angiography. The left renal vein was single, and just before draining into IVC made two branches craniocaudally, which both passed retroaortically and separately entered the inferior vena cava.

Key words: renal vein anomaly, CT angiography, renal donor

Introduction

Complete knowledge of the anatomy and variations of renal veins is necessary for retroperitoneal surgeries, including renal transplantation. Failure to diagnose these anomalies at surgery may lead to bleeding, nephrectomy and even death.¹⁻³ Furthermore, hematuria, proteinuria or varicocele may be caused by left renal vein anomalies which are usually detected incidentally.³ These variations are more frequently detected and better assessed with the advent of multi-detector CT.⁴ CT angiography is accepted as a reliable method for assessment of renal donors.⁵

Left renal vein anomaly is more common than that of right side.⁶ There are few reports of rare cases of renal vein anomalies.

Yesildag et al. reported left renal vein anomaly in 32 of 984 cases (3.2%) in their study. Twenty-three (2.3%) of them were retro aortic and 9 (0.9%) of them were circumaortic left renal vein.³ Other

variations in left renal vein are also reported (7-10)

In the following case, we will introduce a case with uncommon form of left renal vein drainage to inferior vena cava (IVC).

Case Report

The patient was a 35 years old man who was a renal donor. Routine ultrasonography of kidneys was normal. He was scheduled for abdominal CT angiography to define any preoperative vascular anomalies. CT angiography was done with a multi-detector 4 row Light speed QXI (GE model) scanner. Protocol of scan included 1.25 mm collimation, 7.5 mm table speed and 1.5 pitch. 100 milliliter of 300 milligram visipaque was injected by a power injector. Scan was done from diaphragm down to level of pubic symphysis. In renal donors, to achieve optimal opacification of renal vein in addition to renal artery by using bolus tracking method, we start scan in the late arterial phase. Data

Correspondence : Dr. Sofia Sabouri
Department of Radiology,
Shohada-e-Tajrish Hospital,
Shahid Beheshti University of Medical Science,
Tehran, Iran.
Email: dr.sabouri@hotmail.com

was analyzed in an ADW 4.1 GE workstation. Images were reviewed in Multi planar reconstructions (MPRS), Maximum Intensity projection (MIP) and Volume rendering (VR).

There was right sided renal artery duplication. The accessory renal artery originated from abdominal aorta adjacent to superior mesenteric artery, and both renal arteries had normal diameter and density. (Fig. 1)

The left renal vein was single, and just before draining into IVC made two branches craniocaudally. They both passed retroaortically and each one had a separate drainage to inferior vena cava. (Fig. 2)

Right renal vein and its drainage into IVC were normal. (Fig. 3)

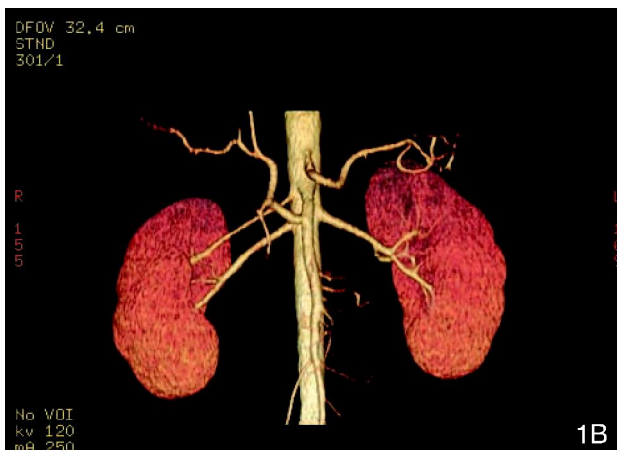
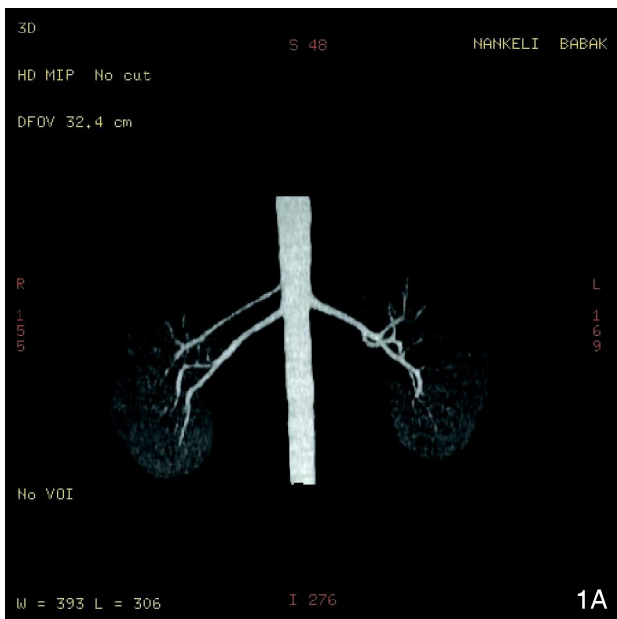


Figure 1A and 1B: Duplicated right renal artery

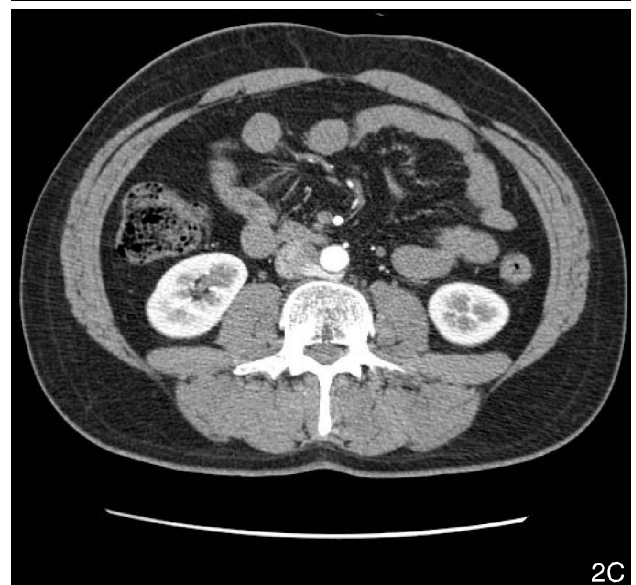
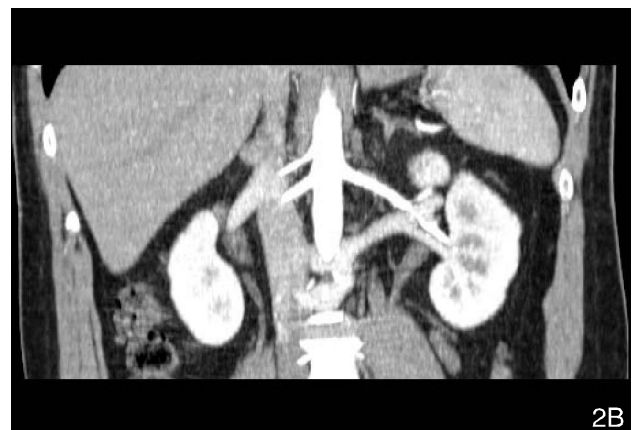
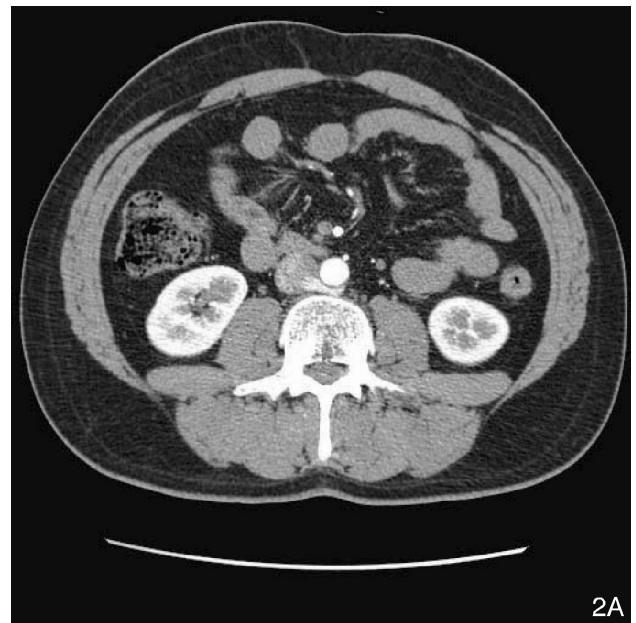


Figure 2A, 2B and 2C: Single retroaortic left renal vein with dual drainage to IVC

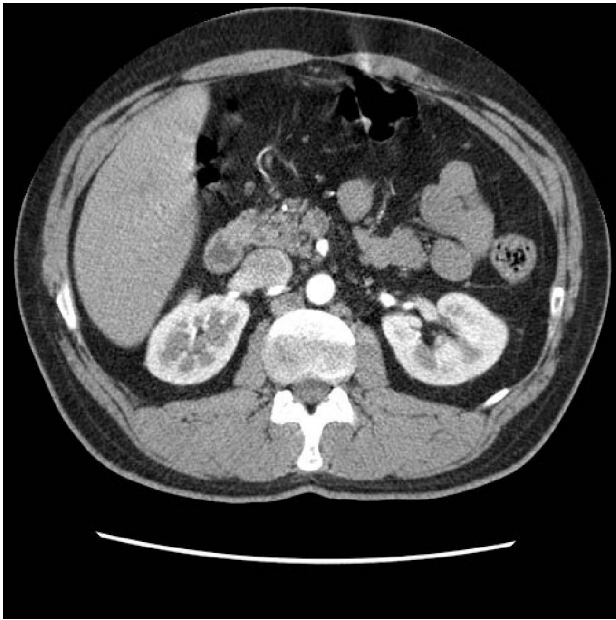


Figure 3: Normal right renal vein

Discussion

In renal transplantation, the morphology of the renal veins has a special importance in that variations may affect the method of the surgery. For example, variations limit availability of vein for mobilization methods. During surgery, the surgeon may see a pre-aortic vein while being unaware of an additional retro aortic portion or a posterior primary branch, and may disturb it while mobilizing the kidney.¹⁻³ Thus, imaging screening of potential renal transplantation donors seems to be critical.

These variations are more frequently detected and better assessed with the advent of multi-detector CT. CT-Angiography is a noninvasive accurate method to evaluate renal donor,⁵ even though venous anomalies can be distinguished in routine abdominal CT scan with a careful review.²

During fetal development there are 3 major types (I, II, III) of renal vein based on the drainage pattern of the primary renal vein tributaries. The most common type is type 1A which has two upper and lower primary tributaries that combine together to make the main renal vein. The second most common is type 1B with upper, lower and posterior tributaries. Type 3 has additional renal vein too.¹¹

Classically, there are variations of the left renal vein configuration: a single renal vein crossing in front of the aorta to drain into the IVC (normal), retro aortic

LRV, duplication of the IVC or transposition of the IVC, circum-aortic LRV.^{2,3,8}

There are few reports of rare cases of renal vein anomalies. Brancatelli et al. reported a 27-year-old man evaluated with a 1-year history of recurrent right flank pain, hematuria, fever and dysuria.⁷ Images showed a retro aortic left renal vein attaching the left common iliac vein.⁷ Turgut et al. reported a retro aortic left renal vein attaching the left common iliac vein.⁸ There is also a variant of the retro aortic Left Renal Vein (LRV) category with a possible low implantation to the Inferior Vena Cava (IVC) at the L4-L5 level, which has been described by Hoeltl and colleagues.⁹ Two cases, one with two LRV's draining in two different sites of the IVC and one with orthotropic IVC and ectopic left common iliac vein represent a combination of the normal LRV attitude and low-positioned variant of the retro aortic LRV. An additional renal vein is an accessory vein with a separate origin from renal Hilum and a drainage site into IVC which has been found in more common cases.¹⁰ In our case, the left renal vein was single, and just before draining into IVC made two branches craniocaudally, both passed retroaortically and each one had a separate drainage to inferior vena cava. Since we could not find a similar case, our case should be the first reported one with this anomaly.

References

1. Harold A. and Mitty. circum-aortic renal collar: a potentially hazardous anomaly of the left renal vein. *AJR* 1975; **125(2)**: 307-10.
2. Yepildađ A, Adanir E, Korođlu M, Baykal B, Oyar O, Gölsoy UK. [Incidence of left renal vein anomalies in routine abdominal CT scans]. *Tani Girişim Radyol* 2004; **10(2)**: 140-3.
3. Satyapal KS, Kalideen JM, Haffejee AA, Singh B, Robbs JV. Left renal vein variations. *Surg Radiol Anat.* 1999; **21(1)**: 77-81.
4. Chai JW, Lee W, Yin YH, Jae HJ, Chung JW, Kim HH, Park JH. CT angiography for living kidney donors: accuracy, cause of misinterpretation and prevalence of variation. *Korean J Radiol* 2008; **9(4)**: 333-9.



5. Panaro F, Testa G, Balakrishnan N, Rao B, Bogetti D, Jarzembowski T, Sammartino C, Sankary H, Benedetti E. Living related small bowel transplantation in children: 3-dimensional computed tomography donor evaluation. *Pediatr Transplant* 2004; **8(1)**: 65-70.
6. Gillaspie, C., Miller, L. and M. Baskin. Anomalous renal vessels and their surgical significance *Anat. Rec* 1916; **11**: 77-86.
7. Brancatelli G, Galia M, Finazzo M, Sparacia G, Pardo S, Lagalla R. Retroaortic left renal vein joining the left common iliac vein. *Eur Radiol* 2000; **10(11)**: 1724-5.
8. Turgut HB, Bircan MK, Hatipoglu ES, Dogruyol S. Congenital anomalies of left renal vein and its clinical importance: a case report and review of literature. *Clin Anat* 1996; **9(2)**: 133-5.
9. Hoeltl W, Hruby W, Aharinejad S. Renal vein anatomy and its implications for retroperitoneal surgery. *J Urol.* 1990; **143(6)**: 1108-14.
10. Steven S. Raman, Suwalee Pojchamarnwiputh, Kobkun Muangsomboon, Surgically Relevant Normal and Variant Renal Parenchymal and Vascular Anatomy in Preoperative 16-MDCT Evaluation of Potential Laparoscopic Renal Donors. *AJR* 2005; **188**: 105-14.
11. K. S. Satyapal, Classification of the drainage patterns of the renal veins, Department of Anatomy, University of Durban-Westville, Durban, South Africa *J. Anat* 1995; **186**: 329-33.