

MRI DWIBS – A NOVEL WAY OF NON-INVASIVE WHOLE BODY IMAGING

Siddappa Gurubalappa Gandage, Sushil Ghanshyam Kachewar

Rural Medical College, Pravara Institute of Medical Sciences, Loni, Maharashtra, India.

PJR October - December 2012; 22(4): 128-131

ABSTRACT

BACKGROUND: Whole body imaging is vital in the management of patients having malignancies. It is an established practice to use Bone scan and PET-Scans for follow up of oncology patients to evaluate metastases. But these modalities are not radiation free. Moreover as the availability of these imaging modalities is limited, waiting period is also more. **PURPOSE:** A study was therefore undertaken to see if the MRI DWIBS whole body imaging programme could be used in this scenario to get satisfactory answers, as the facility of MRI is usually available and radiation free. **MATERIALS AND METHODS:** Diffusion weighted whole body Magnetic Resonance Imaging with background body signal suppression (DWIBS) was performed using 1.5 T Philips MRI on patients suffering from malignancies and results were analyzed. DWIBS images were displayed with inversion of grey scale so as to resemble images of Bone scan. **RESULTS:** DWIBS MRI was successful in demonstrating the presence and extent of bone as well as soft tissue metastases. Detail MRI studies are indicated when in depth evaluation of the pathology is desired. **CONCLUSION:** MRI DWIBS is a new non-invasive acceptable way of evaluating metastases and thus be benefit when bone scan and PET scan facilities are not available or are very costly especially in a rural setup. Further comparative studies are necessary to evaluate if DWIBS can replace bone scan or PET scan.

Keywords: Whole body imaging, Oncoimaging, Cancer imaging, DWIBS MRI, Bone scan, PET scan, Non Invasive Imaging

Introduction

The physical, mental, social and economic well being of the patient as well as his relatives is gradually eaten away by Cancers in their different forms. Accurate diagnosis and staging is therefore a vital prerequisite for positive management. Herein comes the role of whole body imaging.

Oncopatient are already weakened not only by the disease but also by various chemotherapeutic agents. Further exposing such an individual to diagnostic radiations as in Bone Scan or PET-CT scans amounts to the proverbial last straw on the camel's back before it is doomed. Therefore attempts are made for generating whole body MRI

screening techniques. Such a technique would be a boon in disguise as MRI helps in detecting metastatic lesions before changes in bone metabolism make them detectable on bone scan.¹ The purpose of this study was to assess if the MRI DWIBS whole body imaging programme can give results like Bone scan or PET scan in cancer afflicted patients.

Poverty in developing nations prevents costly cancer treatment affordability. Advanced Imaging with PET-CT & Bone Scan therefore remains a distant dream. Hence a need was felt to use the locally available DWIBS MRI technology in a satisfactory manner to find a way out.

Correspondence : Dr. Sushil Ghanshyam Kachewar
Rural Medical College,
Pravara Institute of Medical Sciences,
Loni, Maharashtra, India.
Email: sushilkachewar@hotmail.com

Materials and Methods

The study was carried out in a rural medical college setup on 1.5 Tesla Philips MRI system. Permission of institutional ethical and research cell, and informed written consent from patients were obtained prior to study. A normal healthy male volunteer and 20 patient who were either operated for known malignancy or those who had come for post operative follow up were evaluated. Noncooperative, non-consenting patients and those with general contraindications for MRI study were excluded.

Dr.Takahara, Tokai University Hospital, Japan originally developed DWIBS protocol using SENSE parallel imaging technique.¹ Parameters used at our institute are tabulated in (Tab. 1).

Parameter	Value
TR	> 5000ms
TE	< 70ms
EPI factors	47
SENSE factor	2
b value	1000 sec / mm
Slice thickness	4 mm
Breath hold	Not needed
Total acquisition time	10 min.

Table 1: MRI Parameters used for DWIBS study in our institute

Axial slices were reformatted to produce whole body image with inversion of grey scale so that the final images resemble Bone scan or PET scan like images which are now well accepted by referring medical fraternity.

3D reconstructed STIR images with background suppression were taken when exact details of anatomical regions were needed.

Results

DWIBS images in a normal healthy male (Fig.1) show normal hypo intense appearance in brain, central spinal canal, stomach, spleen, pelvis and testes.

DWIBS images in a patient operated earlier for carcinoma cervix (Fig. 2) and now presented with right supraclavicular soft tissue metastasis seen as hypo intense mass. Hypo intensities in vertebral column and pelvis also indicate metastases.

DWIBS in a patient operated earlier for carcinoma breast (Fig.3) and now presented with back ache and thigh pain. Hypo intensities in the cervico-thoracic vertebral column and both the femora indicate metastatic involvement.

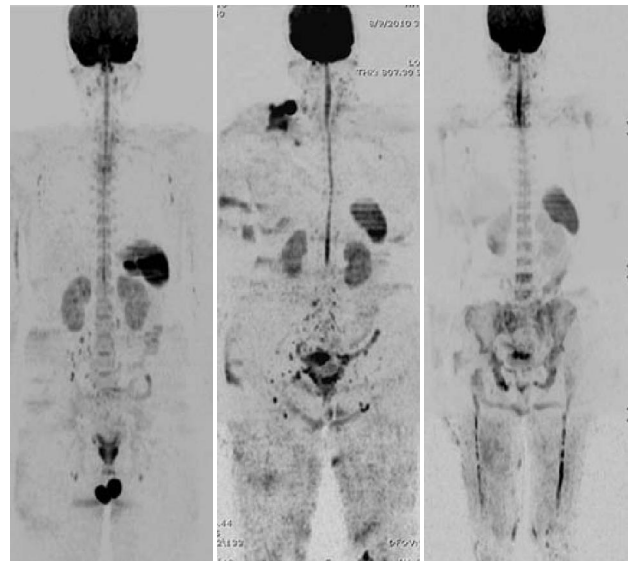


Fig. 1

Fig. 2

Fig. 3

Figure 1: DWIBS images in a normal healthy male.

Figure 2: DWIBS images in a patient operated earlier for carcinoma cervix and now presented with right supraclavicular soft tissue metastasis seen as hypo intense mass. Hypo intensities in vertebral column and pelvis also indicate metastases.

Figure 3: DWIBS in a patient operated earlier for carcinoma breast and now presented with back ache and thigh pain. Hypo intensities in the cervico-thoracic vertebral column and both the femora indicate metastatic involvement.

Of the 20 patients with known malignancies, 8 were in preoperative phase and 12 were follow up cases. 18 patients were having breast malignancies. 2 patients were suffering from carcinoma cervix. MRI DWIBS imaging programme gave satisfactory information about the extent of spread in pre-operative cases and about the presence or absence of metastases in follow up cases.

Discussion

Concerns about radiation hazards, economic constraints, scarce availability and prolonged waiting period of PET-CT & Bone Scan guided us to test whether DWIBS MRI can be an alternative especially in our rural setup.

Tumors with high cellularity possess many cellular membranes leading to restricted diffusion of water molecules. The region with restricted diffusion appears bright on DWI. However the images are printed with inversion of grey scale so that they resemble Bone scan or PET scan images as these are well accepted by treating doctors.^{2,3}

Following are the important differences between DWIBS and conventional diffusion weighted imaging:⁴

1. No breath hold is needed because as DWIBS employs single-shot EPI, the acquired phase shift due to respiratory motion is equal in each phase-encoding step and hence does not affect image formation.⁵
2. Therefore the scanning time and image acquisition time is no more confined to a particular phase of the breathing cycle thereby speed is increased.
3. Images with multiple *b*-values including high *b*-values can be acquired.
4. Thin slices can be obtained.
5. Multiple signal averaging is possible, enabling volumetric (3D) image processing, including maximum intensity projections (MIPs), volume rendering, and multiplanar reformatting (MPR) in any plane

Our initial results with DWIBS have proved satisfactory and have been well accepted by the referring doctors. In fact DWIBS scores much more in comparative analyses of various imaging techniques for evaluating skeletal metastases as shown in Table 2.

Limitations of DWIBS⁴ are that, abscesses can mimic malignancy. Poor anatomical details are noted. Normal non-pathological structures liver, GB, spleen, kidneys etc. also show up, hence basic T1, T2WI & STIR remain indispensable to act as an anatomical reference frame for the DWIBS images.

Applications of DWIBS in Oncology⁴ are mainly for staging and monitoring response to treatment. Persistent or recurrent tumor tissue will show a more restricted diffusion than treatment-related changes, mainly because of higher cellular density. Hence it is possible to differentiate persistent or recurrent tumor tissue from non-tumoral post therapeutic change using DWIBS, although further research is indicated for proving this concept.

Sr. No.	Criteria	Bone Scan	PET Scan	DWIBS MRI
1	Availability	Less	Lesser	More
2	Prior preparation	Needed	Needed	Unnecessary
3	Scan Time	More	More	Less
4	Radiation Exposure	Yes	Yes	No
5	Repeatability	Limited	Limited	Unlimited
6	Usage in Pregnant patients	No	No	Unlimited
7	Usage in Pediatric patients	Limited	Limited	Unlimited
8	Cost of study	More	More	Less

Table 2: Comparative analyses of various imaging techniques for evaluating skeletal metastases

Discrepancy between PET scan and bone scan to detect bone metastases has been reported.^{6,7} Negative scintigraphy with positive magnetic resonance imaging in bone metastases has also been reported.^{8,9} Hence wide comparative studies between DWIBS, Bone scan and PET scan are needed.^{10,11} DWIBS, an MRI similar to 18 F-FDG PET/CT imaging, seems to be feasible in detection of cancers; however it may be difficult to differentiate between the benign and malignant lesions.¹² DWIBS is thus an upcoming MRI modality for cancer imaging where ever Bone Scan or PET scan is not available and cost is an issue. Moreover, DWIBS can be performed on state-of-the-art MRI systems supplied by all major vendors.

Conclusion

Our initial results prove that DWIBS is a good alternative for whole body imaging to assess metastases and help in staging of cancer patients. It is radiation free, widely available and cost efficient. Hence we suggest that it be used more often, although comparative studies with Bone scan and PET scan would help in establishing statistical details about sensitivity and specificity of each modality as compared to DWIBS.

Conflict of interest disclosure - The authors declare no conflicts of interest.

Acknowledgement

All the patients who have undergone DWIBS and their referring doctors are hereby thanked for the trust they have displayed.

References

1. Takahara T, Imai Y, Yamashita T, Yasuda S, Nasu S, VanCauteren M. Diffusion weighted whole body imaging with background body signal suppression (DWIBS): technical improvement using free breathing, STIR and high resolution 3D display. *Radiat Med* 2004; **22**: 275-82.
2. Eustace S, Tello R, DeCarvalho V, et al. A comparison of whole-body turbo STIR MR imaging and planar ^{99m}Tc-methylene diphosphonate scintigraphy in the examination of patients with suspected skeletal metastases. *AJR Am J Roentgenol* Dec 1997; **169**: 1655-61.
3. Kachewar SG. Using DWIBS MRI technique as an alternative to bone scan or PET scan for whole-body imaging in oncology patients. *Acta Radiologica* 2011; **52**: 788.
4. Kwee TC, Takahara T, Ochiai R, Nievelstein , Luijten PR. Diffusion-weighted whole-body imaging with background body signal suppression (DWIBS): features and potential applications in oncology. *Eur Radiol* 2008; **18**: 1937-52.
5. Bammer R. Basic principles of diffusion-weighted imaging. *Eur J Radiol* 2003; **45**: 169-84.
6. Kao CH, Hsieh JF, Tsai SC, et al. Comparison and discrepancy of ¹⁸F-2-deoxyglucose positron emission tomography and Tc-^{99m} MDP bone scan to detect bone metastases. *Anticancer Res* 2000; **20**: 2189-92.
7. Franzius C, Sciuk J, Daldrup-Link HE, et al. FDG-PET for detection of osseous metastases from malignant primary bone tumours: comparison with bone scintigraphy. *Eur J Nucl Med* 2000; **27**: 1305-11.
8. Kattapuram SV, Khurana JS, Scott JA, el-Khoury GY. Negative scintigraphy with positive magnetic resonance imaging in bone metastases. *Skeletal Radiol* 1990; **19**: 113-6.
9. Evans AJ, Robertson JF. Magnetic resonance imaging versus radionuclide scintigraphy for screening in bone metastases. *Clin Radiol* 2000; **55**: 653-4.
10. Daldrup-Link HE, Franzius C, Link TM, et al. Whole-body MR imaging for detection of bone metastases in children and young adults: comparison with skeletal scintigraphy and FDG PET. *AJR Am J Roentgenol* 2001; **177**: 229-36.
11. Dickinson F, Liddicoat A, Dhingsa R, Finlay D. Magnetic resonance imaging versus radionuclide scintigraphy for screening in bone metastases. *Clin Radiol* 2000; **55**: 653.
12. Komori T, Narabayashi I, Matsumura K, Aga F and Matsuki M. ¹⁸F-FDG PET/CT versus body diffusion-weighted MRI for detection of malignant lesions. *J Nucl Med* 2006; **47**: 483.