

QUIZ

GARLET SIGN ON DEXA SCAN

Submitted by: Nosheen Fatima,¹ Maseeh uz Zaman,² Zafar Sajjad,² Unaiza Zaman,³ Areeba Zaman,³ Rabia Tahseen³

- ¹ Department of Nuclear Medicine, Ziauddin Hospital, Karachi
- ² Department of Radiology, Aga Khan University Hospital (AKUH), Karachi
- ³ Student MBBS, Dow Medical College, DUHS, Karachi

PJR January - March 2013; 23(1): 51-52

This is a 55 years old postmenopausal lady, being worked up for left sided breast cancer. On her first visit to Radiology department she had a contrast enhanced abdomen and chest CT studies followed by a Dual Energy X-ray Absorptiometry (DEXA) scan on same day (Fig. 1). However, after reviewing the scan, the nuclear physician requested a repeat study after 3 days.

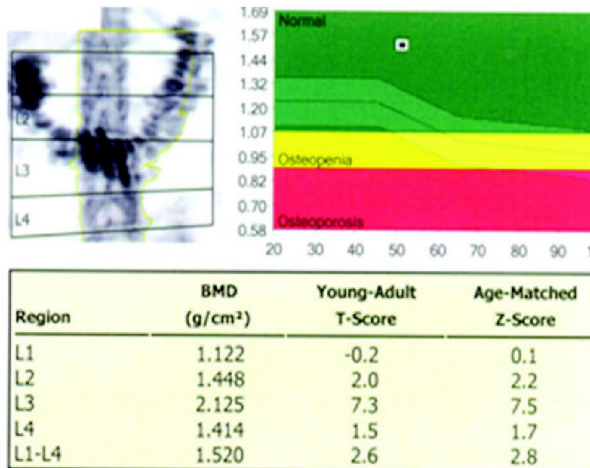


Figure 1: DEXA scan of lumbar spine on first visit.

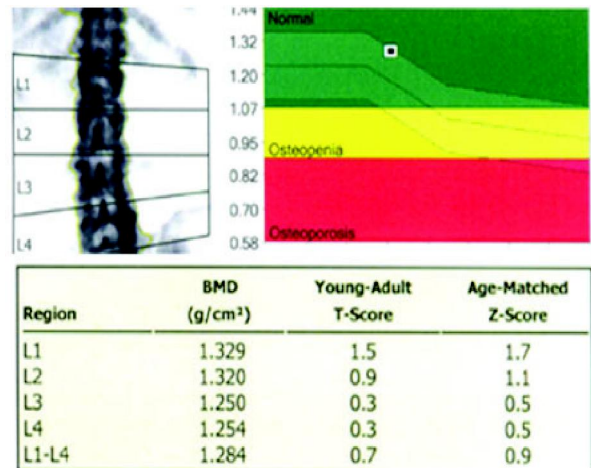


Figure 2: DEXA scan of lumbar spine on subsequent visit. After 3 days a repeat DEXA scan done and this time exam was found satisfactory.

Questions

- Q1. (Fig. 1) Why a repeat study was suggested?
- Q2. (Fig. 2) Why abnormally high T and Z-scores got normalized?

QUIZ

Answers

Figure 1:

- a. Patient was not positioned properly
- b. Error in energy window of X-ray
- c. Computer error in calculating T and Z-scores
- d. Optimal study but with abnormally high T and Z scores

Figure 2:

- a. Patient was positioned properly
- b. Technical error in DEXA machine was rectified
- c. Oral contrast has been washed out
- d. Patient has received some treatment to bring her T and Z score into normal limits.

Comment: Correct answers are 1d and 2c.

One her first visit she had a contrast enhanced CT study which was followed by a DEXA scan. Due to presence of oral gastrografen in transverse colon (visible in Figure 1 as a “Garlet Sign” called by authors) this has resulted in higher photon attenuation over the lumbar spine. This attributes to falsely elevated bone mineral density (BMD), T and Z-scores for her age. Repeat scan after 3 days shows absent “Garlet Sign” due to clearance of gastrografen and correct measurement of BMD and other scores over lumbar spine. It is important to defer a DEXA scan for at least 2 weeks after an intravenous contrast, 3-7 days after an oral contrast and 1-2 days after a nuclear medicine procedure performed with Tc-99m to avoid falsely high BMD, T and Z-score values (equal or greater than 4 SD).¹

References

1. Gregson CL, Steel SA, O'Rourke KP, Allan K, Ayuk J, Bhalla A, et al. 'Sink or swim': an evaluation of the clinical characteristics of individuals with high bone mass. *Osteoporos Int.* 2012; **23(2)**: 643-54.