

UTERINE ARTERIOVENOUS MALFORMATION: A REVIEW OF CURRENT LITERATURES

Blessing Ose-Emenim Igbinedion,¹ Suyash Kurlkarni²

¹ Senior Lecturer, Radiology Department, University of Benin, Nigeria.

² Associate Professor of Radiology, Tata Memorial Centre, Parel, Mumbai, India.

PJR January - March 2013; 23(1): 22-30

Introduction

Arteriovenous malformations (AVMs) are vascular channels composed of admixture of arteries and veins without intervening capillaries. These AVMs consist of numerous fragile low-resistant arteriovenous shunts. AVM can occur in any part of the body such as the brain, spleen, lung, kidney, liver, intercostals spaces, iris and spermatic cord.¹ In general, AVMs are most commonly congenital and genetic transmission patterns are unknown.¹ The uterus is involved less commonly by AVM. Uterine arteriovenous malformation (UAVM) is a rare condition that affects women of reproductive age and clinically presents with unexplained profuse bleeding per vagina. The bleeding is usually intermittent, torrential, or may be intractable and life threatening. UAVM are abnormal vascular channels that involve the myometrium and occasionally the endometrium. Myometrial involvement is more common than endometrial AVMs. Endometrial affectation is usually from extension of the myometrial UAVM. The first case of uterine AVM was reported by Dubreuil and Loubat in 1926.² Vaginal bleeding in women of reproductive age is usually pregnancy related for which UAVM is a cause that health personnel involved in the care of such cases should be familiar with. The bleeding from UAVM may occur as a result of exposure of the AVM from sloughed endometrium during menstruations or from uterine instrumentations. The bleeding can be severe enough to warrant multiple pints of blood transfusions as well as more

drastic management to preserve the life of the patient. Uterine AVM is also a cause of recurrent pregnancy loss. Recurrent pregnancy loss can have a devastating effect on these women, her family and close relatives.

Incidence, aetiology and types

The incidence or prevalence of UAVM is unknown and it is considered rare with only over 100 cases reported since 1926.^{1,3,4} The true incidence rate remains unknown despite several attempts. In the study by Yazawa et al⁵ which aimed at determining the incidence of uterine vascular disease and uterine arteriovenous malformations in 959 patients after abortion or delivery and in outpatients, only 1(0.10%) had uterine AVM. This study is the most plausible in the literatures, thus the incidence rate may be approximately 0.10% of women who had abortion or delivered. It is reasonable to assume that this value will reduce significantly if one considers the rate of UAVM amongst women of reproductive age (both pregnant and non-pregnant) because the acquired type (which is more common than the congenital type) has an association with pregnancy and pregnancy-related complications. In another study done by O'Brien et al⁶ the incidence of uterine AVM was put at 4.5% of women within reproductive age who presented with bleeding PV, while Shilpa et al⁷ reported it as constituting 1-2% of cases of genital bleeding. There is significant limitation in getting a correct incidence rate due

Correspondence : Dr. Blessing Ose-Emenim Igbinedion,
Senior Lecturer, Radiology Department,
University of Benin, Ugbowo, Benin,
Edo - 300001, Nigeria.
Tel: +2348034045844
Email: igbins2@yahoo.com

to the few available case reports and small series which may reflect the rare nature of UAVM. However, UAVM is being increasingly reported either because of increased awareness, over-diagnosis/mis-diagnosis with other uterine vascular diseases, increased number of competent hands and imaging equipments. Our search of the literature did not yield any case from Africa which may be due to paucity of competent man-power, imaging equipment and poor awareness. It is almost impossible to hypothesize that it is non-existent in Africa.

There are two types of UAVMs; congenital and acquired. The congenital types are rarer than the acquired type. Congenital UAVM can occur in isolation and with other AVMs in other organs of the body.⁴ Congenital uterine AVMs arise from anomalous differentiation/failure in embryologic differentiation in the primitive capillary plexus which results in abnormal communications between arteries and veins (abnormal vascular connections). In congenital UAVM, multiple feeding arteries with a central nidus (a tangle of vessels with histologic characteristics of both arteries and veins) and numerous large draining veins usually occur.^{6,7} It is also not uncommon to have extension to pelvic vessels other than uterine arteries in cases of congenital UAVM. These other vessels include ovarian artery and the artery supplying the round ligament of the uterus.

On the other hand, acquired UAVMs are confirmed by communications between the uterine arteries and veins unlike congenital UAVM that may connect with other pelvic arteries.⁸ Thus acquired UAVMs result from abnormal arteriovenous communication (arteriovenous fistulae) between one or more uterine arteries and a myometrial and/or endometrial venous plexus, without the interposition of a vascular nidus.⁷ Hence, it can be simply explained that acquired UAVM is the joining of an artery with a simple vein. There are several possible causes of acquired UAVM. But it simply arises from uterine trauma and instrumentation with the following causes reported in the literatures; exposure to diethylstilbesterol, intrauterine contraceptive, pregnancy (including multiple pregnancies), necrotic chorionic villi invading venous sinus, spontaneous abortion, previous dilatation and curettage, caesarean

section, endometriosis, fibromyoma, gestational trophoblastic disease, endometrial and cervical cancer.^{1,7,9,10}

Pathology

On histopathology, gross-specimen evaluation may reveal variable sized thin-walled, tubular channels filled with blood clots which appear as region of irregular blood spaces and congested blood vessels within the myometrial tissues that is devoid of specific lesion. Similarly, microscopic examination may demonstrate the gross pathologic findings as numerous dilated blood-filled (static and congested) thick-walled vessels of varying calibre in the myometrium that may extend into the endometrium.⁹ There are also proliferation of arterial and venous vessels with fistulae and tiny vessels that appear like capillaries. However, these abnormal connections between the arteries and draining veins show no clear signs of intervening capillary channels. The myometrium may also show many thick-walled vessels that arose from high intraluminal pressure within the veins causing venous intimal thickening that makes it look like an artery and thus differentiation between the two becomes difficult.⁴ These vessels have varying dimensions and may be seen up to the uterine serosal.¹

Clinical Presentation

It is pertinent to get detailed and proper history from the patient, especially history that may give an indication as to the possible cause. Such history should include information on pregnancy, recurrent abortions, uterine procedures (such as endometrial biopsy and dilatation and curettage), and uterine surgeries such as myomectomy. Furthermore adequate history may help differentiate congenital from acquired even when radiological examination could not. Incidental cases of UAVMs are not uncommon. It can also be detected during pregnancy and may be asymptomatic with a normal pregnancy outcome despite concerns that it may grow during pregnancy.

However patients may present variably from an asymptomatic case to life-threatening situation such that the patient may be in hypovolemic shock at the point of presentation. Most commonly the bleeding is intermittent and torrential.¹ A surprising case of UAVM was reported by Das et al,¹¹ in which the patient had a history of recurrent par vagina bleeding of 18 years duration. This case shows that patient presentation may be acute or chronic depending on the amount of blood loss, associated complicating features and clinical status.

UAVM can present as recurrent vaginal bleeding following termination of pregnancy or post caesarean section. At such times the clinician may have an impression of either incomplete abortion of gestational trophoblastic disease.⁷ This scenario may even be worsened if the UAVM coexists with retained product of conception which will then have a lot of confusing similarities with gestational trophoblastic disease. The use of beta-human chorionic gonadotropin and imaging modalities becomes vital in making an accurate diagnosis. Consequently, abnormal post-partum or abortal hemorrhage warrants meticulous evaluation to exclude retained product of conception, placental polyp, gestational trophoblastic disease, post-abortal endometritis and other rare causes including AVM, especially as these clinical presentations and imaging features often mimic.

Diagnosis and management

Prior to the advent of modern imaging modalities such as ultrasound, computed tomography (CT) and magnetic resonance imaging (MRI), the diagnosis of uterine AVM was historically by laparotomy or pathologically after hysterectomy.³ As a result imaging has played an important role in those afflicted with this ailment by conserving several uterus and thus sustaining fertility in most instances. The role of radiologists in the management of UAVM has evolved from making diagnosis with increasingly accuracy (as improvements occurs

in imaging equipments and techniques) to treating patients with this condition. In resources limited countries this important role played by radiology is not felt as patients may not be able to afford some of these radiological evaluations or treatment. The clinicians then have limited management options to adopt.

Ultrasound is usually performed as an initial assessment imaging modality of choice in women presenting with bleeding par vaginam. This is particularly so because it is non-ionizing, relatively cheap and non-invasive. It is also not uncommon to find ultrasound unit in health facilities in remote rural regions, although these units may lack Doppler capability which then reduces its diagnostic yield. Thus grey-scale sonographic findings of uterine AVM are non-specific, but may assist in excluding other causes of bleeding such as gestational trophoblastic disease and retained product of conception in most cases. Unfortunately, the diagnostic accuracy of ultrasound depends on the expertise of the user and the machine type. The uterus may appear bulky with or without a demonstrable mass that may appear as focal area of heterogeneity. The mass may be intramural and extend to the endometrium. In addition, the mass may be located within the myometrium, endometrium, or cervix. Endometrial and pelvic fluid collection may be seen especially during the bleeding period. There may be multiple anechoic serpiginous channels within the myometrium (Fig.1A) that may extend to the endometrium with effacement of the junctional zone. Transvaginal scan will give better image quality and improved accuracy especially with Doppler application and is useful in patient's follow up. The invasion of the myometrium and endometrium are better delineated. However it is relatively minimally invasive.

Diagnosis of UAVM can be confidently made by colour and spectral Doppler ultrasound.^{4,6,12} The anechoic channels seen on grey-scale will show intense colour fill on Doppler with associated colour aliasing (Fig. 1B & C). These tangles of vessels with multi-directional high velocity flow and colour mosaic pattern (aliasing) due to turbulence suggest the diagnosis of UAVM. Diagnosis is further improved by spectral Doppler analysis which shows

arteriovenous shunting with high velocity and low resistance flow. Arteriovenous shunting is highly suggestive if the peak systolic velocity is high which can be over 96cm/s; low resistivity index between 0.25 to 0.75; and pulsatility index between 0.3 to 0.6.^{6,13} This spectral Doppler findings may be confused with that caused by malignant AV shunts. Malignant AV shunts tend to have low volume high velocity flow in contrast to low resistance high volume flow that characterizes an AVM. The adnexal vessels may also be involved and becomes prominent or distended with similar colour Doppler findings and high peak and diastolic velocities with low resistivity index.

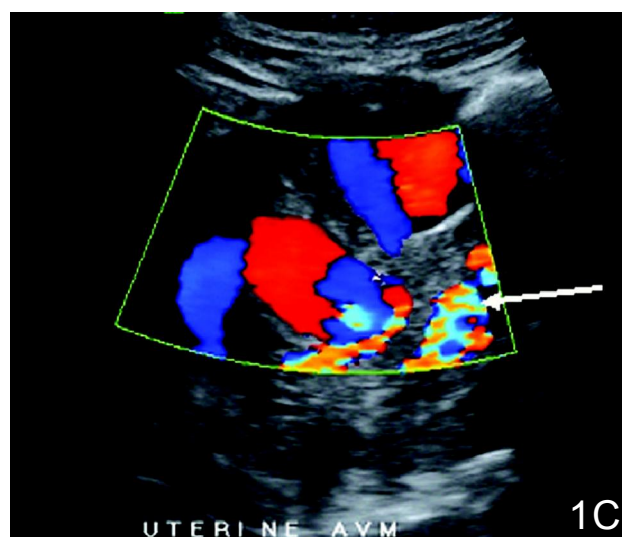
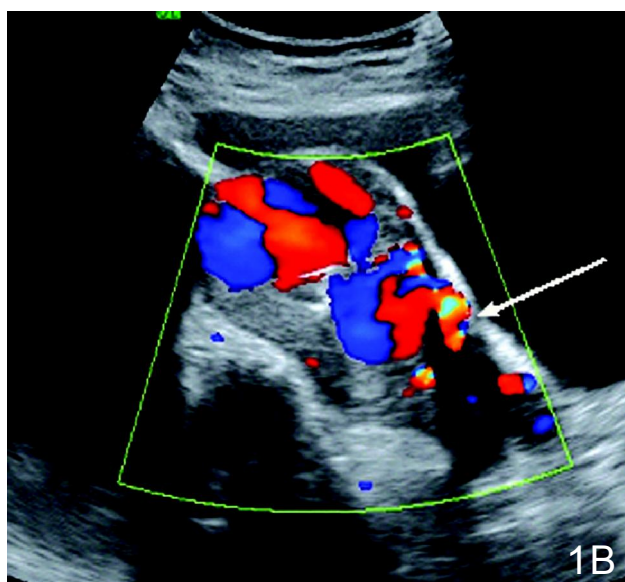
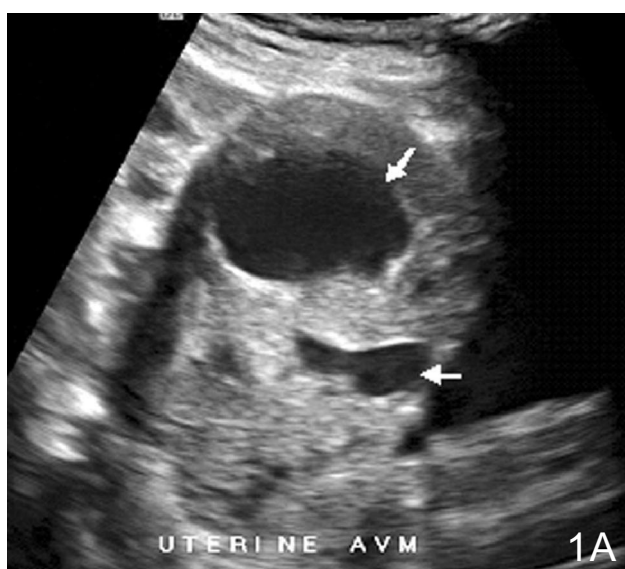


Figure 1: Grey-scale ultrasound image showing the UAVM mass with two large sinusoid channels, short arrows. **A:** On colour application the anechoic channels were filled with colours showing multi-direction and mosaicism, long arrows (**B:** transverse), (**C:** longitudinal).

MRI is superior to CT in showing the size and extent of the lesion with the added advantage that it can demonstrate disruption of the junctional zone and endometrial involvement. The vascular lesions of UAVM will be demonstrated on MRI as multiple serpiginous region of signal void on both T1 and T2 weighted imaging (Fig. 2A & B). On MR angiography there will be increased uterine vascularity and dilated, tortuous or prominent parametrial and pelvic vessels (Fig. 2C). Thus the feeding vessels including their origin and draining veins may also be delineated. Endometrial and pelvic fluid collections, the bulky nature of the uterus and uterine mass caused by UAVM can also be easily depicted. CT may show similar findings to MRI but the radiation dose from it should be taken into account (Fig. 3A, B & C).

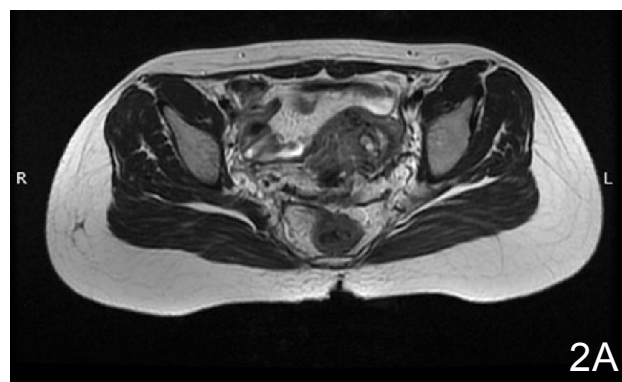

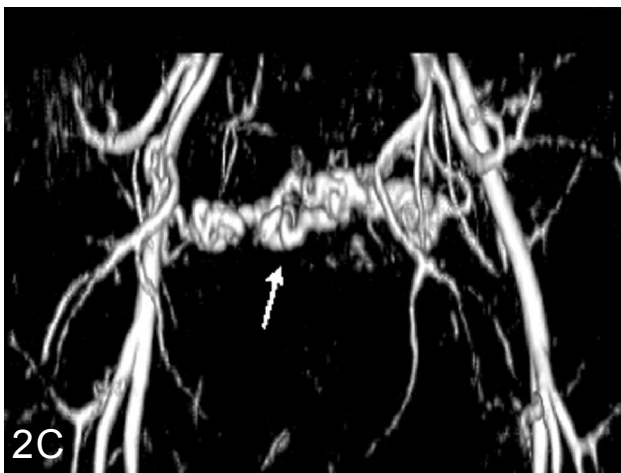
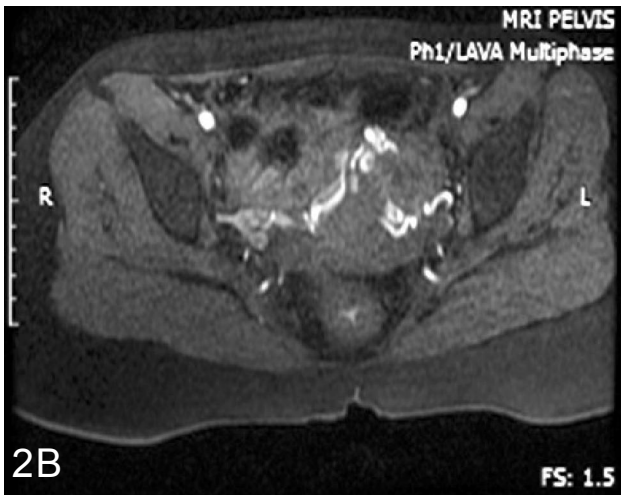

Figure 2: Magnetic resonance images showing the vessels as signal void, black arrow (A), hyperintense tortuous vessels, black arrow (B) and volume rendered processed image of the AVM, white arrow (C).

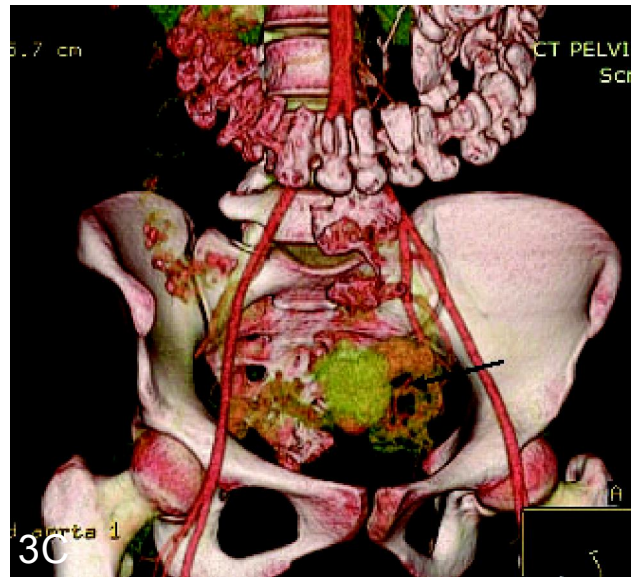
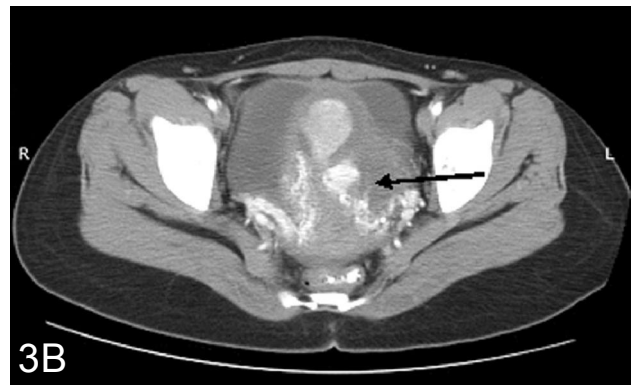
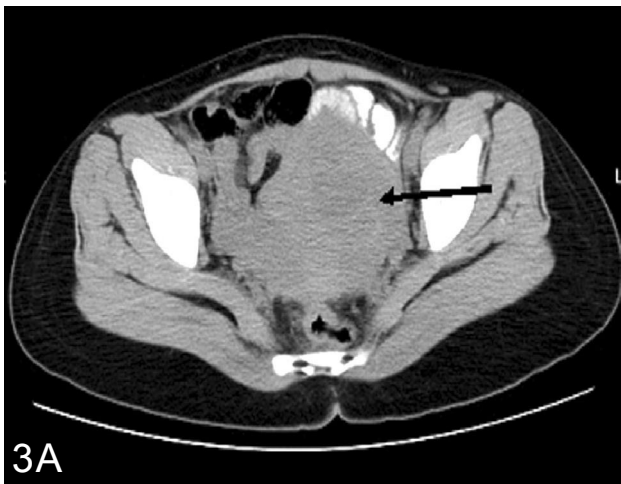

Figure 3: Unenhanced CT image showing a bulky uterus with ill-defined uterine mass, arrowed (A). On contrast injection there were multiple vessels within the mass and prominent left pelvic vessels, arrowed (B). Volume rendered image that shows the UAVM vasculature, arrowed (C).

Goyal et al⁹ used hysteroscopy to make an impression of UAVM. They reported visualizing an extremely vascular mass arising from the posterior wall of the uterus with thinned out endometrium and mosaic-like pulsatile sub-endometrial branching vessels.⁹ Unfortunately, hysteroscopy can complicate the bleeding from UAVM especially in untrained hands, as such, extreme caution should be exercised in its usage.

Angiography is the gold-standard in making a diagnosis of UAVM.^{10,12} However because of concern over its radiation dose the use of ultrasound and MRI for initial assessment is recommended. Angiographic embolization in the treatment of UAVM is being practised in several countries. It is also a minimally invasive procedure that serves both

diagnostic and therapeutic purpose. In fact both of its purposes are presently the gold-standard in the diagnosis and management of UAVM. Transcatheter embolization was first used to treat a case of uterine (obstetric) hemorrhage in 1979.¹⁴ Since then it has been used in several other gynaecological applications. The UAVM appears as a tangle of dilated vessels with early venous drainage which is seen during the angiographic arterial phase (Fig. 4A). The vascularity is demonstrable by doing a distal aortogram, common iliac or internal iliac angiogram (Fig. 4B). Embolization of uterine arteries is the most effective approach, especially if fertility is to be preserved. It also have additional advantages because it reduces the duration of stay in the hospital, complication rate, is a lesser cost of treatment and the recovery period is reduced when compared with other traditional treatments. Furthermore, Angiographic embolization can be done on patients that are anaemic or haemodynamically unstable.⁶

The success rate of bilateral uterine artery embolization is above 95%.¹⁵ In this procedure, selective catheters are passed percutaneously to a convenient proximal point to the UAVM feeders through which embolic agents are introduced until stasis is achieved in order to increase the success rate of the embolization procedure (Fig. 4C). The use of smaller sized catheters (microcatheters) passed coaxially aids access to difficult arteries.

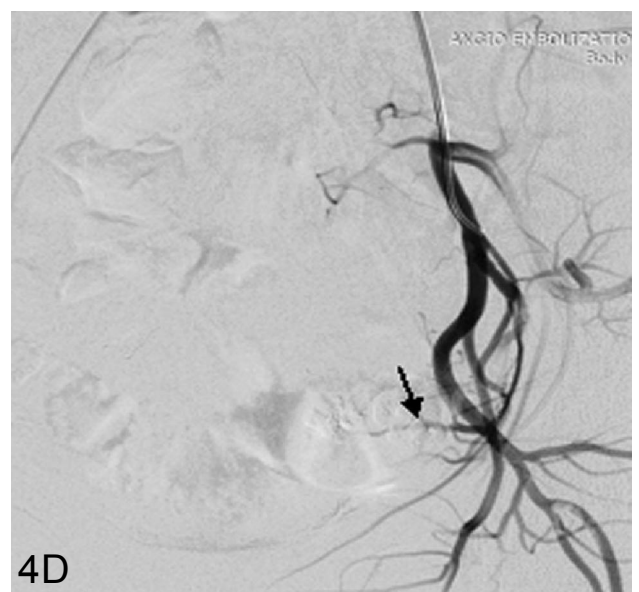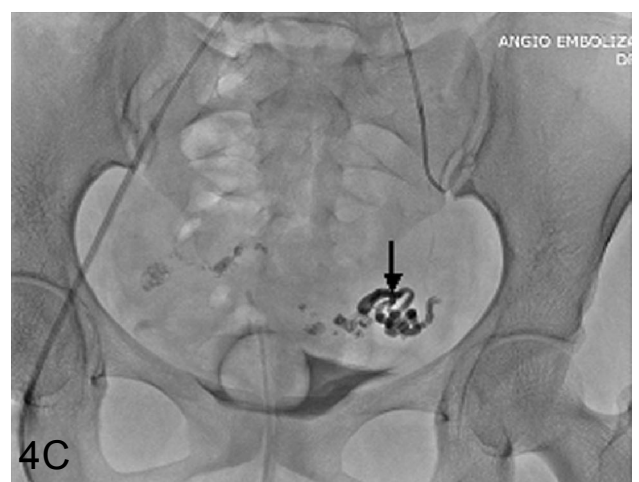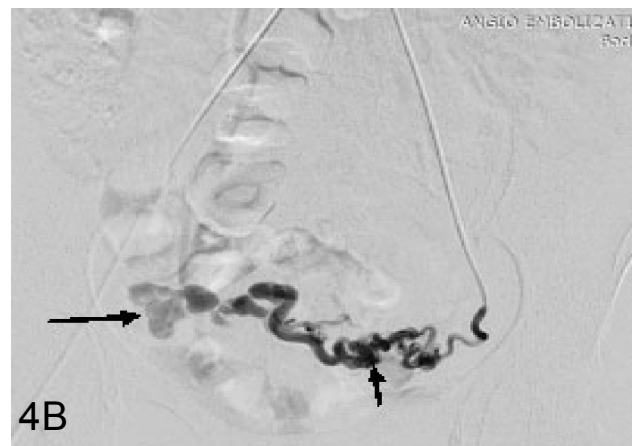
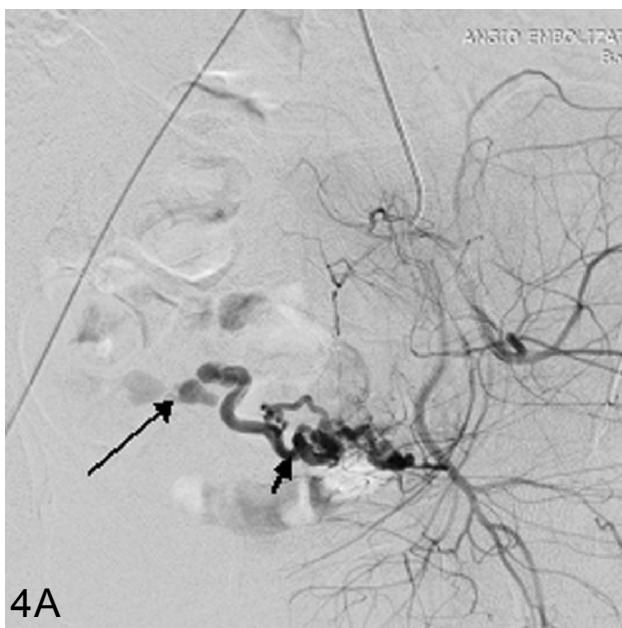


Figure 4: Left internal iliac angiogram showing the tortuous contrast filled vessels (short arrow) with early venous drainage (long arrow) (A) and super-selective angiogram of the feeding artery (B). Angioembolization image by the use of glue, arrowed (C). Post-embolization, no vascular flow to the UAVM, arrowed.

Typical embolic agents used include gelfoam, polyvinyl alcohol (PVA) particles, autologous blood clot, microfibrillar collagen, isobutyl cyanoacrylate (glue) and steel coil spring occluders.¹¹ Some radiologists may combine these embolic agents as desired purportedly to achieve better result. During angioembolization, the development of arterial spasm may reduce the amount of particles injected before stasis supervenes, giving rise to false end point of embolization.¹⁴ As a result vasodilators (such as nimodipine) may be used to dilate the vessels which then increases the amount of embolic agents injected and thus improves the therapeutic effectiveness. At the end of the procedure (Fig. 4D) the patient may be discharged within 48 hours unlike surgical management that may take days. Other authors had used gonadotropin-releasing hormone agonist to shrink the UAVM in adjunct to embolization or to defer embolization.¹¹

Unfortunately, uterine artery embolization may not always be successful and repeated sessions can be performed for recurrent episodes.^{16,17} Another complication is infection (occurs in few cases) that may occur following embolization which can lead to hysterectomy, necessitating early recognition by the managing team to avoid potentially fatal septic shock.¹⁴ Other uncommon complications of angio-embolization include perianal skin sloughing. Uterovaginal and rectovaginal fistulas, and neurological deficit in the lower limb.⁶

From the preceding discussion, it has become crucial that accurate and prompt diagnosis is made to reduce the morbidity and mortality from UAVM. Non-invasive imaging modalities such as ultrasound should be used to differentiate the causes of bleeding PV in women of reproductive age, so as to minimize torrential life-threatening bleeding complication that may arise from investigative or therapeutic procedures such as dilatation and curettage which was indicated for instance to treat retained product. The bleeding results from spontaneous vessel rupture or vessel rupture that is triggered by trauma.⁷ It is important to keep in mind the possibility of uterine AVM in refractory cases of menorrhagia that is not responding to conventional measures.¹¹ Doppler ultrasound is also indicated in patients with recurrent bleeding PV to exclude UAVM. The initial diagnosis of uterine

AVM should be based on pertinent patient history, negative beta-HCG, and the characteristic colour spectral Doppler findings.⁶

Management of UAVM depends on the age of the patient, her desire for future fertility, severity of bleeding, availability of treatment options and trained man-power. In the past hysterectomy was the only remedy.¹¹ It may still be employed in resources limited regions or in cases where the patient opt for it particularly if she is not desirous of having more children. In stable patients, other method of management can be employed such as surgical removal of AVM, laparoscopic bipolar coagulation of the uterine blood vessels, and long term medical therapy with combined oral contraceptives.^{4,11} Others have used methylergonovine and gonadotropin releasing hormone analogue.¹⁸ Stabilization of the patient can be attempted using tamponade with foley's catheter or rolled gauze packing and medical therapy (oestrogen, progestins, methylergonovine, danazol, 15-methyl prostaglandin).¹¹ However, failed attempt have been reported when trial of tranexamic acid, oral contraceptive and a foley's catheter inserted to tamponade the uterus was utilized.¹⁹

In the active bleeding situation percutaneous embolization can be used to arrest uterine hemorrhage from several causes other than UAVM, thereby avoiding hysterectomy which is the definitive management if all fails. The uterus usually reper-fuses itself against the potential ischemia from the embolization by its anastomotic collateral channels with other vessels such as the vaginal, ovarian and the round ligament's arteries.²⁰ As an alternative to embolization, especially where it is unavailable, surgical ligation of the anterior division of the internal iliac arteries that supplies the uterus and the anastomosing ovarian branches can be performed in selected cases rather than doing hysterectomy.

Transvaginal ultrasound and MRI are recommended imaging modalities to evaluate the uterus post-embolization. TVS shows revascularization of the normal myometrium and an essentially normal appearance of the endometrium at 6 months post-embolization.¹⁴ Therefore the endometrial thickness may return to normal within a few cycles. In fact menstrual flow as early as from 4 weeks post-embolization has been reported.^{18,19} Disappea-

rance, shrinkage, reduced vascularity or embolic agents may be demonstrated by TVS and MRI post-embolization. Finally fertility is restored post-embolization and the patients may become pregnant even in the preceding menstrual cycle or 4 months afterwards with normal pregnancy outcome and delivery of healthy babies.^{3,19}

Keywords: AVM, arteriovenous malformation, uterus, uterine AVM, UAVM.

Conflict of interest: The authors have none to declare. The review was not funded by any establishment.

References

1. Al-Shekaili KR, Bhatnagar G, Ramadhan FA, Al-zadjali N. Arteriovenous malformation of uterus. *Indian Journal of Pathology and Microbiology* 2011; **54(1)**: 187-8.
2. Dubreuil G, Luobat E. Aneurysme cricoïdes de l'utérus and Ann. *Anat Pathol* 1926; **3**: 697-718.
3. Castillo MS, Borge MA, Pierce KL. Embolization of a traumatic uterine arteriovenous malformation. *Semin Intervent Radiol* 2007; **24**: 296-9.
4. Bagga R, Verma P, Agarwal N, Suri V, Bapuraj JR. Failed angiographic embolization in uterine arteriovenous malformation: a case report and review of literature. www.medscape.com/viewarticle/567523.
5. Yazawa H, Soeda S, Hiraiwa T, et al. prospective evaluation of the incidence of uterine vascular malformations developing after abortion or delivery. *J Minim Invasive Gynecol* 2013; **20(3)**: 360-7.
6. O'Brien P, nevestam A, Buckley AR, Chang SD, Legiehn GM. Uterine arteriovenous malformations from diagnosis to treatment. *J Ultrasound Med* 2006; **25**: 1387-92.
7. Shilpa D, Vidya M, Meenakshi D, Shrenik P. *Indian Journal of Basic and Applied Medical Research* 2014; **3(2)**: 654-7.
8. Cura M, Martinez N, Cura A, Dalsaso TJ, Elmerhi F. Arteriovenous malformations of the uterus. *Acta Radiol* 2009; **50(7)**: 823-9.
9. Goyal S, Goyal A, Mahajan S, Sharma S, Dev G. Acquired arteriovenous malformation developing in retained products of conception: A diagnostic dilemma. *J Obstet Gynaecol Res* 2014; **40(1)**: 271-4.
10. Grivell RM, Reid KM, Mellor A. Uterine arteriovenous malformations: a review of the current literature. *Obstet Gynecol Surv* 2005; **60(11)**: 761-7.
11. Das C, Chaudhuri S, Karmakar M, Chakraborty S. Uterine arteriovenous malformation as a rare cause of menorrhagia. *Online J Health Allied Scs* 2008; **7(3)**: 4. <http://www.ojhas.org/issue27/2008-3-4.htm>.
12. Bottomoley JP, Whitehouse GH. Congenital arteriovenous malformation of the uterus demonstrated by angiography. *Acta Radiologica Diagnostica* 1975; **16**: 43-8.
13. Huang MW, Muradali D, Thurston WA, Burns PN, Wilson SR. Uterine arteriovenous malformations: gray-scale and Doppler US features with MR imaging correlation. 1998; **206(1)**: 115-23.
14. Heaston DK, Mineau DE, Brown BJ, Miller FJ Jr. Transcatheter arterial embolization for control of persistent massive puerperal hemorrhage after bilateral surgical hypogastric artery ligation. *Am J Roentgenol* 1979; **133**: 152-4.
15. Pelage JP, le Dref O, Jacob D, et al. Uterine embolization. *J Radiol* 2000; **81**: 1873-4.
16. Degani S, Leibovitz Z, Hsapiro I, Ohel G. Expectant management of pregnancy related high velocity uterine arteriovenous shunt diag-



nosed after abortion. *Int J Gynaecol Obstet* 2009; **106**: 46-9.

17. Ghai S, Rajan DK, Asch MR, Muradali D, Simmons ME, TerBrugge KG. Efficacy of embolization in traumatic uterine vascular malformations. *J Vasc Interv Radiol* 2003; **14**: 1401-8.
18. Chittawar PB, Patel K, Agrawal P, Bhandari S. Hysteroscopic diagnosis and successful management of an acquired uterine arteriovenous malformation by percutaneous embolotherapy. *J Mid-life Health* 2013; **4**: 57-9.
19. Vilos AG, Vilos GA, Vrijer B, Kozak R, Abu-Rafea B. Fertility and pregnancy outcomes following uterine artery embolization for uterine arteriovenous malformation. *Gynecol Surg* 2010; **7**: 401-5.
20. Lichtinger M, Burbank F, Hallson L, et al. The time course of myometrial ischaemia and reperfusion after laparoscopic uterine occlusion: theoretical implications. *J Am Assoc Gynecol Laparosc* 2003; **10(4)**: 553-66.